



Introduction

Lecture #1

Introduction: -

Biological signal analysis¹ encompasses several interdisciplinary topics that deal with analyzing signals generated by various physiological processes in the human body. These signals could be electrical, chemical or acoustic in origin and an analysis of these signals are often useful in explaining and/or identifying pathological conditions of the human body. However, these signals in their rawest form do not provide much information and therefore, the motivation behind biological signal analysis is to extract (i.e. to reveal) the relevant information. This analysis has become even more important with modern healthcare striving to provide cost effective point-of-care diagnosis and personalized treatment. Furthermore, fast computing power in recent years has made much of the more complex analysis methodologies possible. The purpose of this chapter is to provide an overview of biological signal origins and describe commonly encountered biological signals.

Before we delve into the analysis of biological signals, it would be useful to understand that they are often represented as discrete in time. For example, Figure 1 shows an example of a sinus rhythm electrocardiogram (ECG), which represents the electrical activity obtained from normal heart. A single measurement of the signal x is a scalar and represents the electrical signals generated by the mechanisms in the heart at a particular instant of time t (denoted with index n) rather than at all points of time.

There are two types of noise inherent in this signal: baseline and powerline interference. Figure 2 shows a cleaned version of Figure 1 obtained through band-pass filtering. This figure also shows a zoomed version of the ECG representing one beat of heart. The sharp peaks in the signal denote the occurrence of what is known as the R wave and the time intervals between consecutive R-R peaks would be useful to measure the heart rate, i.e. the number of times the heart beats in a minute.



Introduction

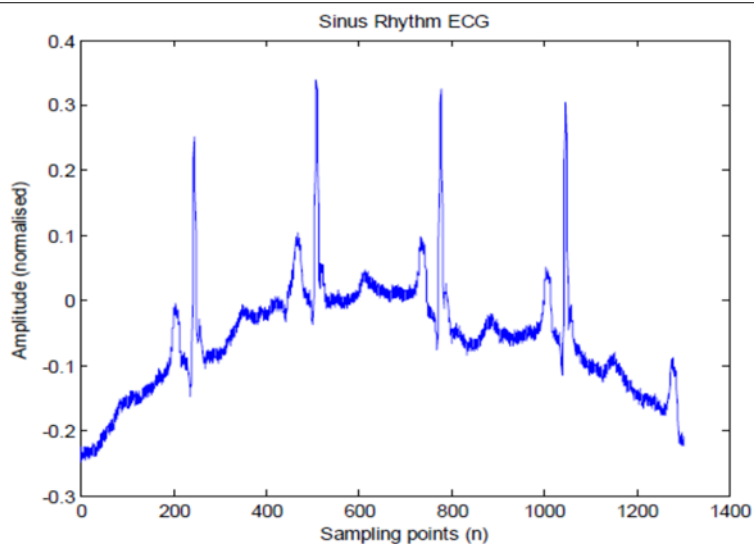


Figure 1: Normal sinus rhythm ECG. ECG data

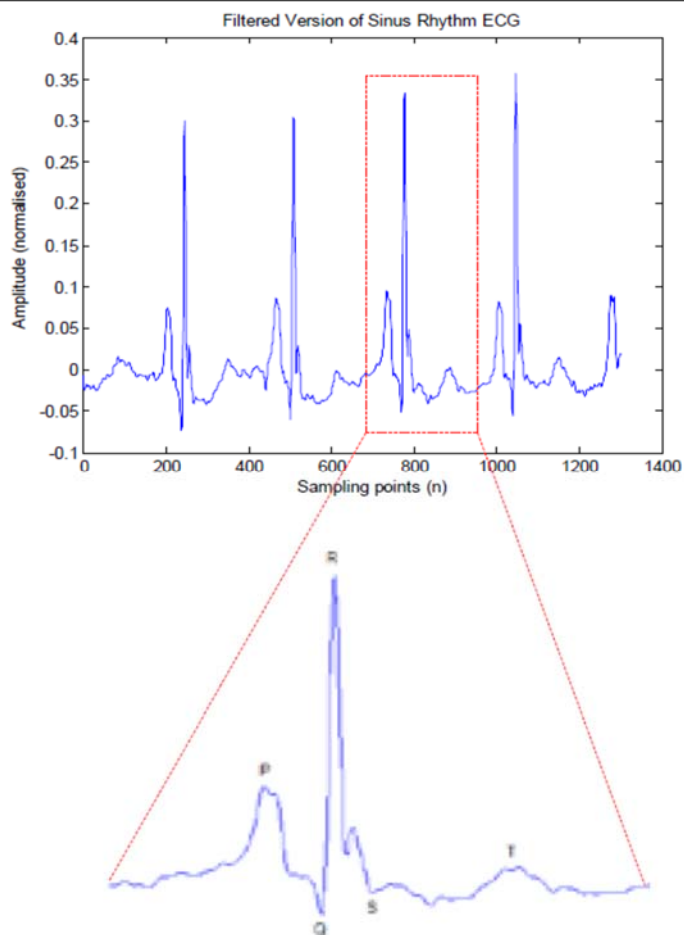
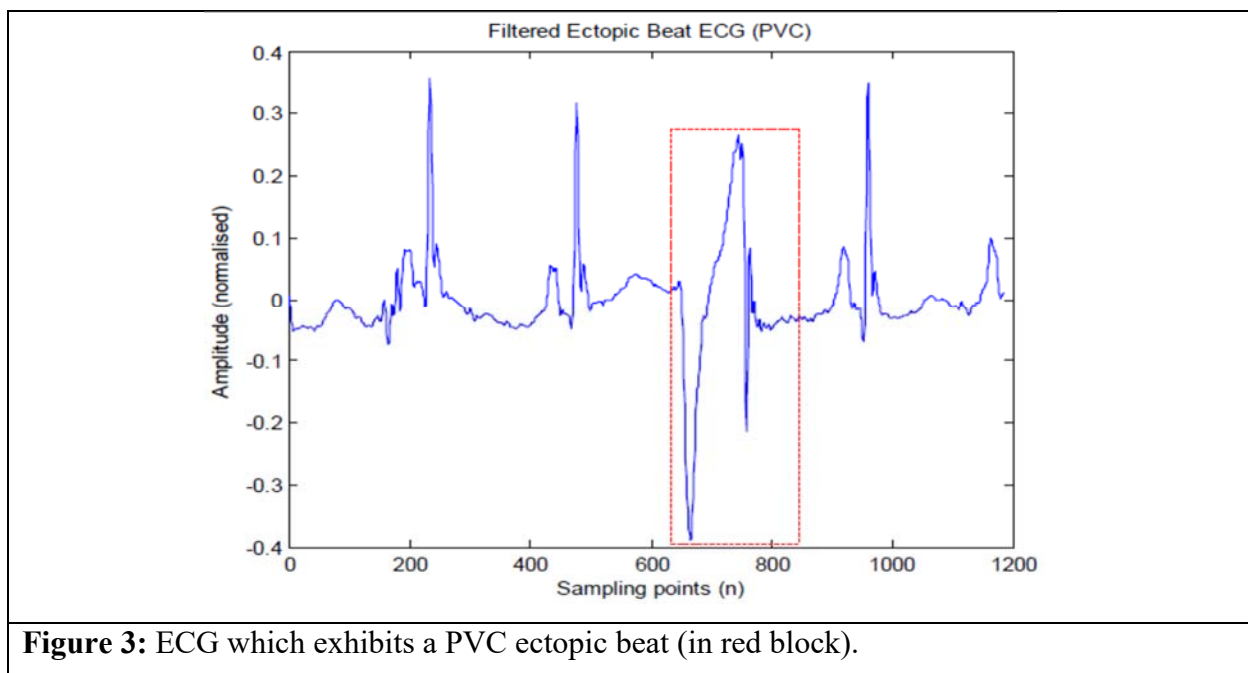


Figure 2: Filtered version of sinus rhythm ECG in Figure 1.



Introduction

Similarly, the segment from the Q wave to the S wave (more commonly known as QRS segment), is useful in indicating certain pathological variations in the heart's electrical system. For example, Figure 3 shows an ECG waveform from a subject with an ectopic beat of Premature Ventricular Contraction (PVC) type. Ectopic beats are premature beats with a complex waveform that can occur occasionally in most people. However, the presence of frequent ectopic beats (more than six per minute) could indicate a serious fatal problem if left uncorrected. While it is visually obvious that the QRS segment for the PVC beat is different from Figure 1, it is impractical to sit and manually detect the occurrences from an ECG chart (or onscreen monitor) of a patient over many hours/days. Rather, a computer that is trained to automatically analyze and detect the occurrence of such beats using signal processing algorithms is employed. This is a typical biological signal analysis application.



Examples of Common Biological Signals: -

Commonly encountered biological signals that describe the electrical activity of the brain, heart, muscles etc will be introduced in this section. Some of these signals like ECG and electroencephalogram (EEG) are spontaneous activity of the human body while others such as evoked potentials are signals in response to external stimulus, for example the presentation of



Introduction

visual stimuli which results in visual evoked potential (VEP) signals. While some analysis procedures are common (like using filters to extract components in specific frequency range), the different properties of these biological signals do call for the application of widely varying analysis procedures. Hence, it is useful to know the fundamental details of how these signals are generated before studying analysis procedures for extraction of the required information.

Electrocardiogram

The ECG is a representation of the electrical activity of the heart and the cardiac rhythm is controlled by the pacemaker cells known as sinoatrial (SA) node. The PQRST waveform (as shown in Figure 4) represents one complete ECG cycle: P wave occurs when SA node fires and the impulse spreads across atria and triggers atrial contraction; PQ interval (isometric segment) is the propagation delay when the impulse travels from atria to ventricles (allowing blood flow to complete in similar direction); QRS complex occurs when the impulse spreads to ventricles and triggers ventricular contraction; ST segment is the period when the ventricles are depolarized and ventricular repolarization (relaxation) begins and T wave represents the return to resting state by the ventricles.

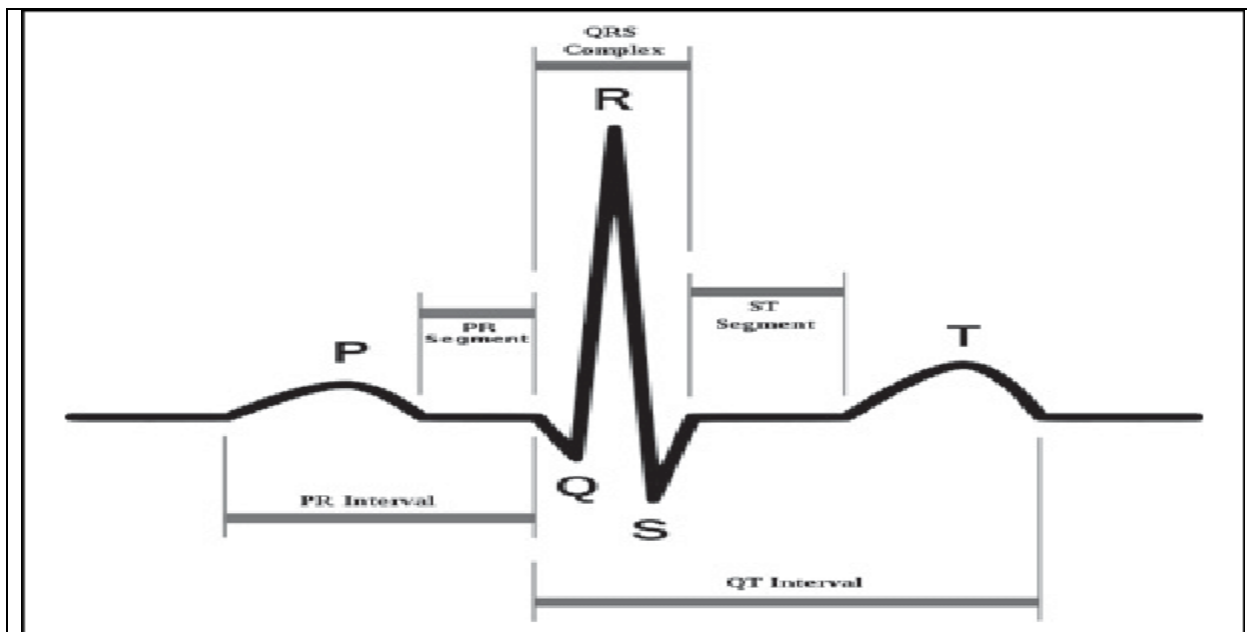


Figure 4: ECG waveform



Introduction

These electrical impulses are normally recorded through electrodes placed on particular areas of the body either using 12-channel ECG in a hospital or 3-channel ECG in the field. Figure 5 shows the hypothetical Einthoven's triangle that is commonly used for the electrode setup. The setup requires four limb electrodes placed on the right and left arms and legs; the fourth limb electrode that is not shown in the diagram is placed on the right leg and serves as reference channel. The top of the Einthoven's triangle forms Lead I, while the left forms Lead II and right forms Lead III. Each lead represents a different aspect of the heart's electrical system. The voltage differences between the limb electrodes: left arm (LA), right arm (RA), and left leg (LL) are used to obtain Leads I, II and III:

$$I = V_{LA} - V_{RA}, \quad (1.1)$$

$$II = V_{LL} - V_{RA}, \quad (1.2)$$

$$III = V_{LL} - V_{LA}. \quad (1.3)$$

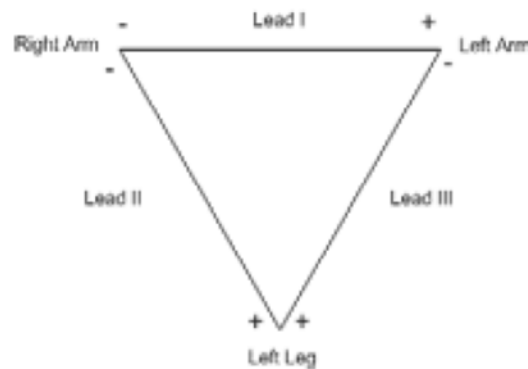


Figure 5: Einthoven's triangle.

Electroencephalogram: -

EEG which represents the electrical activity of the brain has become very useful in the clinical diagnosis and electrophysiological analysis related to functions of the brain. The basic functional unit in the brain is the neuron, which is found in the cerebral cortex. Four different areas of the cortex (frontal, parietal, temporal and occipital) are responsible for varying functions, for example



Introduction

the occipital lobe processes visual information and auditory perception is processed in temporal lobe.

Figure 6 shows the neuron and its interconnections. The brain is made of billions of such connections. The cell body (soma) of a neuron receives neural activity inputs through dendrites and outputs its neural activity through an axon. The axon is covered with a myelin sheath that acts as an insulator (just like rubber covering of copper electrical wires). The axon also contains Ranvier nodes at intervals that act to amplify the signals.

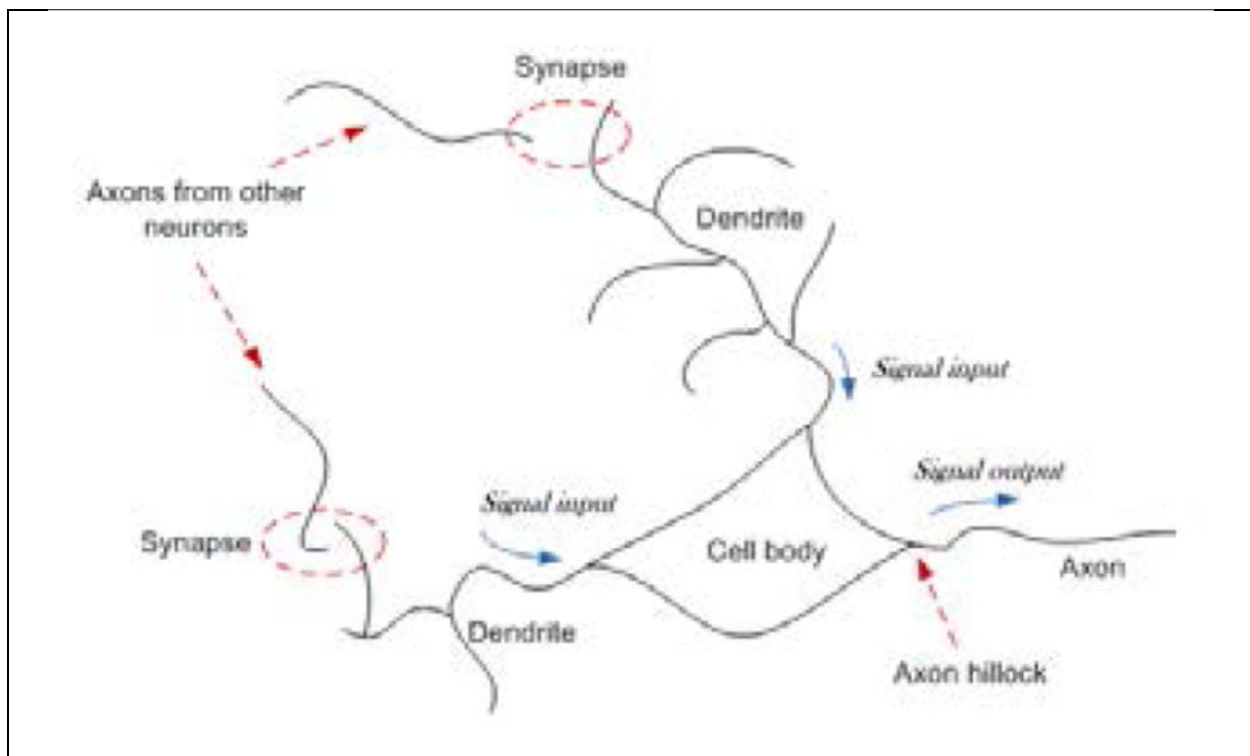


Figure 6: Neuron and its interconnections.

This EEG activity is recorded through electrodes placed on the scalp. The cumulative electrical activity of thousands of neurons (sometimes known as rhythms) as they propagate through the skull and scalp are significantly attenuated but nevertheless can still be captured and amplified to a level that is sufficient for analysis. EEG rhythms are conventionally categorized into five different rhythms based on their frequency ranges (EEG components with frequency less than 0.5 Hz are normally considered to be baseline wander noise): Delta (0.5–4 Hz) rhythm, which only appears



Introduction

during deep sleep stages and in infants as irregular activity; Theta (4–7 Hz) rhythm which is encountered in early sleep stages and drowsiness; Alpha (8–12 Hz) rhythm which is the typical rhythm during relaxed state with eyes closed (it is suppressed with eye opening); Beta (13–30 Hz) rhythm which is prominent during stressful situations and Gamma (> 30 Hz) rhythms, which are believed to be involved in higher order functions of the brain.

In usual practice, EEG signals are recorded on multiple locations on the scalp using electrodes placed at specific points. The International Federation of Societies for Electroencephalography and Clinical Neurophysiology has recommended the 10–20 system of electrode placement, which consists of 19 active electrodes plus two reference (linked to earlobes or mastoids). The distance between each electrode is either 10% or 20% of the total edge distances (e.g. nasion-inion), hence the name 10–20.

Figure 7 shows the 10–20 system of electrode placement, where the letters A, C, F, O, P, and T denote auricle, central, frontal, occipital, parietal, and temporal, respectively⁴. Odd and even numbering are used for the left and right sides, respectively. Midline electrodes are numbered with Z, representing zero. Nowadays, it is common to extend this 10-20 system by placing electrodes in between thus arriving at 32, 64, 128 and even 256 channels!

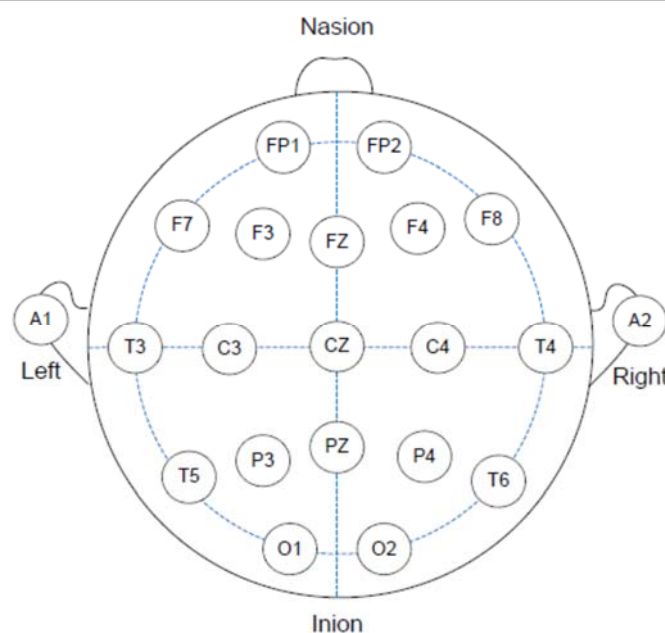
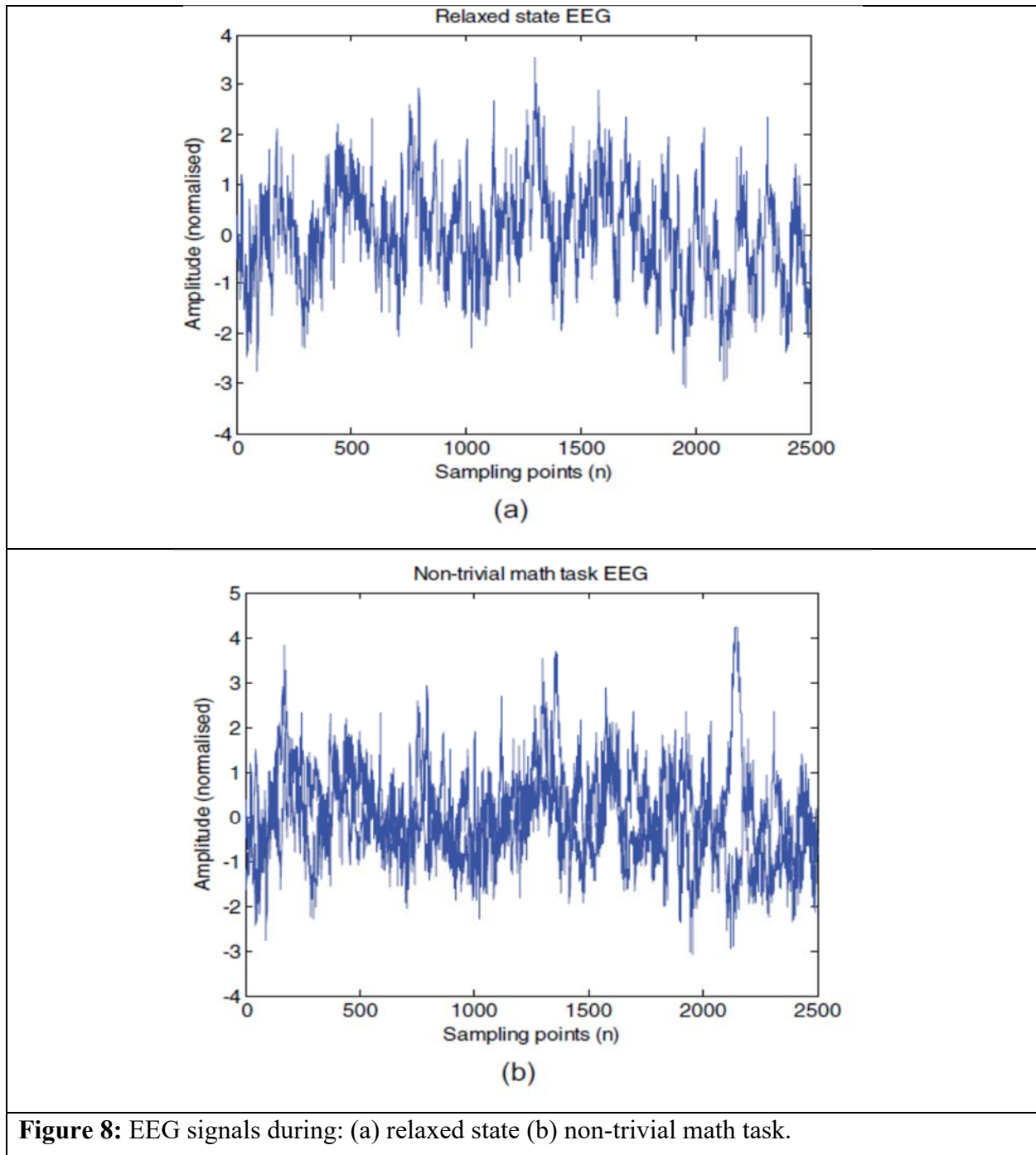


Figure 7: Neuron and its interconnections.



Introduction

Figure 8 shows examples of EEG signals extracted from a subject while resting and performing an active mental task (non-trivial computing task). Visually, both these signals appear to be just noise but in later chapters, it will be shown that both these signals can be discriminated effectively for use in a brain-computer interface application.





Introduction

Electromyogram: -

Electromyogram (EMG) is recorded by an electromyography device, which measures the muscle's electrical potential. The central nervous system consisting of the brain, spinal cord and peripheral nerves controls the action of the muscle fibers that typically results in movements. Muscle is composed of specialized cells that are capable of contraction and relaxation and is controlled by simulations from innervated motor units (neurons).

EMG can be recorded by two methods: surface EMG (SEMG, which records EMG using electrodes placed on the skin) which is more popular than intramuscular EMG (a needle electrode is inserted in the muscle) as it is non-invasive. SEMG measures the muscle fiber action potentials of a single (or more) motor unit, which are known as the motor unit action potentials (MUAPs).

The actual potential is about 100 mV but due to the layers of connective tissue and skin, the SEMG is a complex signal with much less amplitude (typically about 5 mV). Figure 1.14 shows an example of a SEMG signal.

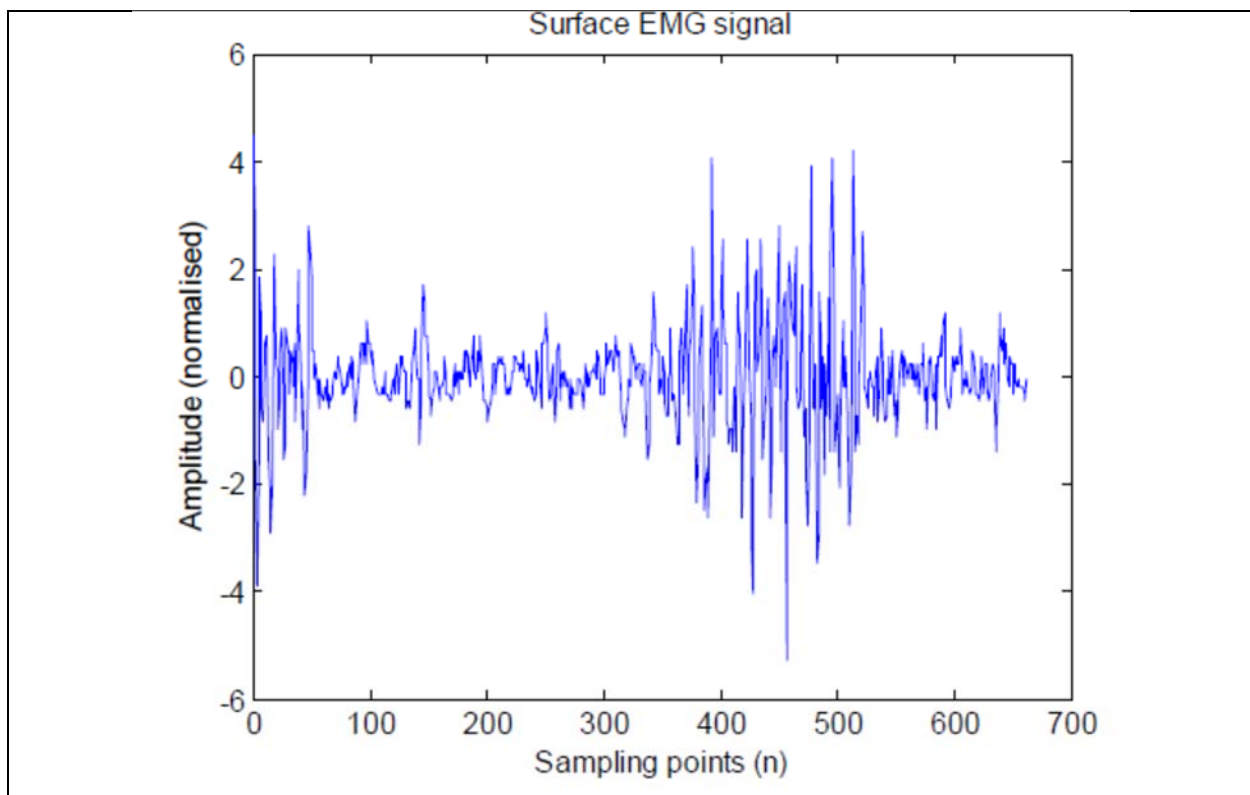


Figure 9: Typical surface EMG signal.

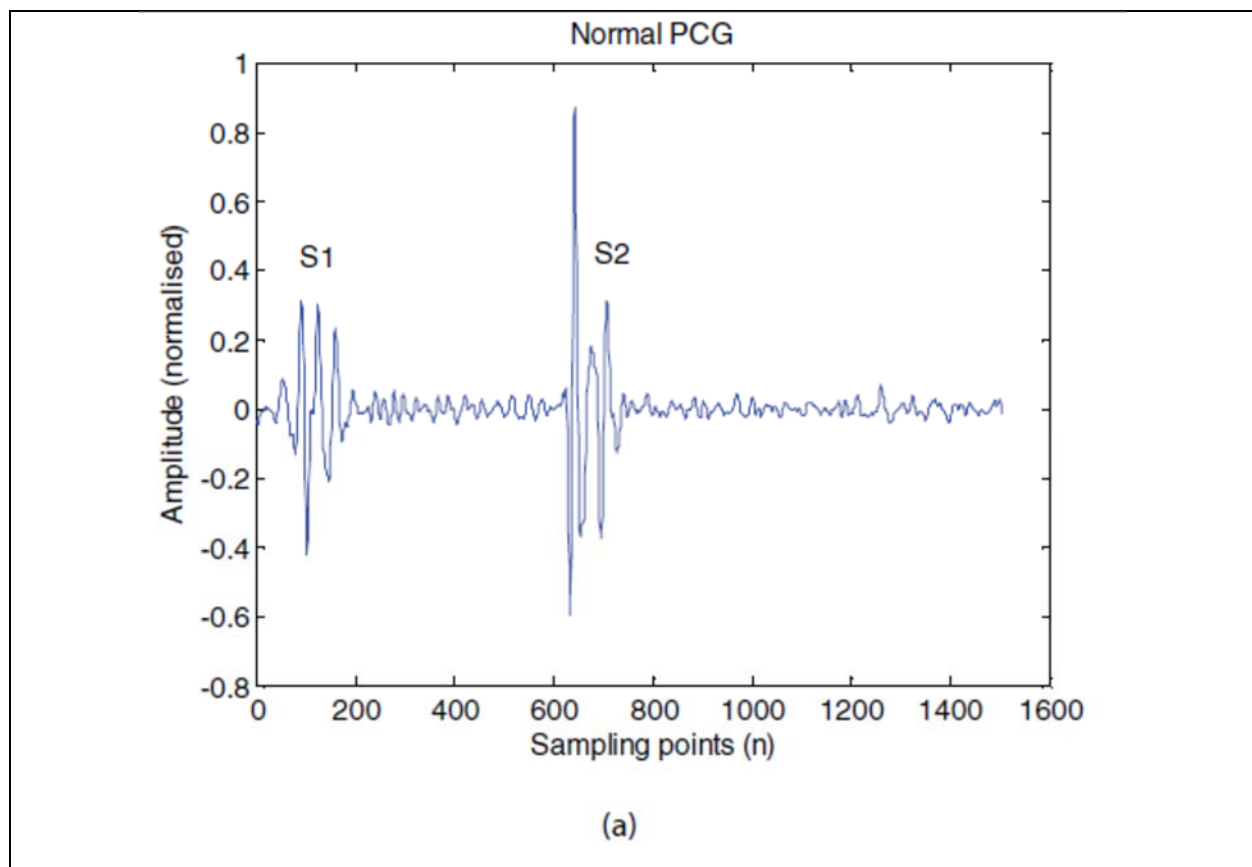


Introduction

Phonocardiogram

Phonocardiography is the vibration or sound of the heart when it pumps blood. Though the common cardiac analysis centers on ECG, phonocardiography can provide complementary valuable information concerning the function of heart valves and the hemodynamics of the heart as ECG can only detect faults in heart's electrical system.

The phonocardiography of a normal heart comprises of two distinct activities namely the first heart sound, S1 and the second heart sound, S2, which correspond to the 'lup' and 'dup' sounds, respectively. An abnormal heart, on the other hand, includes several other activities between S1 and S2 sounds. These abnormal sound activities (like S3, S4, murmurs, clicks and snaps) are useful in diagnosing heart diseases. Nowadays, the sound waves produced by the heart are not only heard using a stethoscope but also observed as phonocardiogram (PCG) signals on a monitor screen. Figure 10 shows PCG signals for a normal heart, systolic murmur (SM) and diastolic murmur (DM).





Introduction

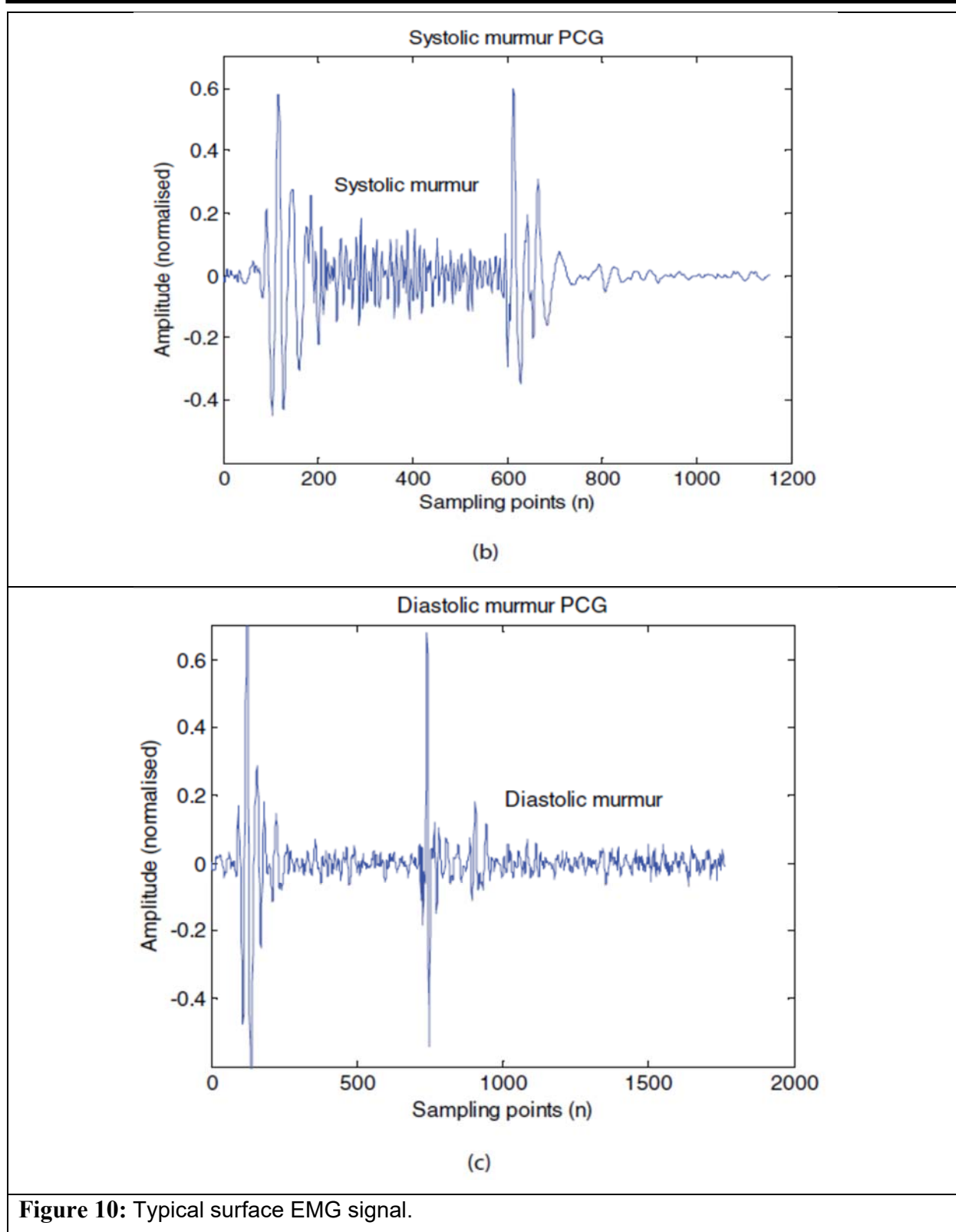


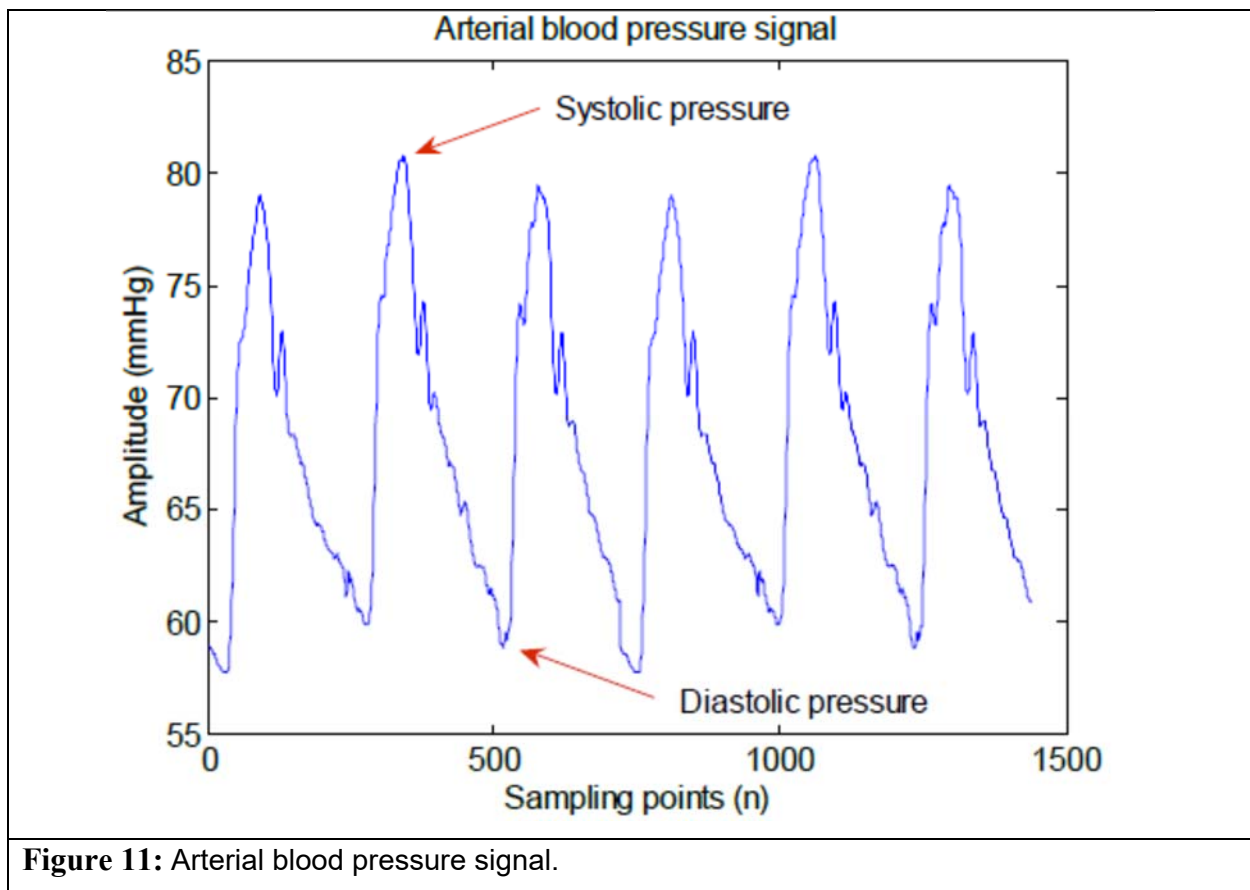
Figure 10: Typical surface EMG signal.



Introduction

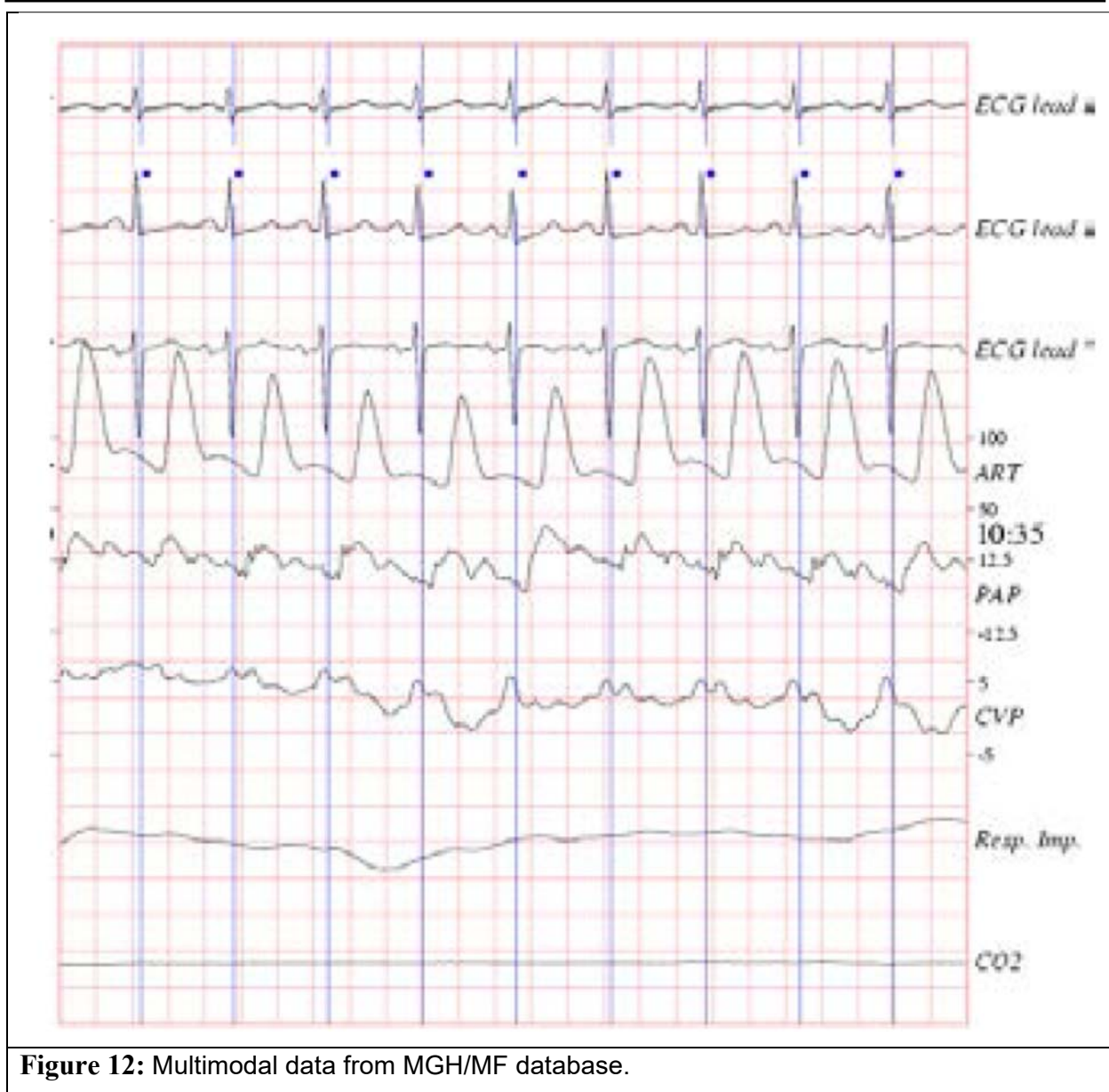
Other Biological Signals: -

There are many other biological signals such as arterial blood pressure signals (ABP, shown in Figure 11) generated by changes in blood pressure which are recorded on the upper arm (units-mmHg); electrooculogram (EOG) signals, which measure the eye movements and oxygen saturation (SpO₂) signals which measures the level of oxygen in blood. It is common to perform a multimodal signal analysis, where more than one signal modality is recorded. This is useful to perform a more thorough diagnosis. Figure 12 shows a typical example where three ECG leads, arterial pressure, pulmonary arterial pressure, central venous pressure, respiratory impedance, and airway CO₂ signals are recorded from a subject.





Introduction



References:-

1. "Biological Signal Analysis" by Ramaswamy Palaniappan.
2. "BIOMEDICAL SIGNAL ANALYSIS" by RANGARAJ M. RANGAYYAN.