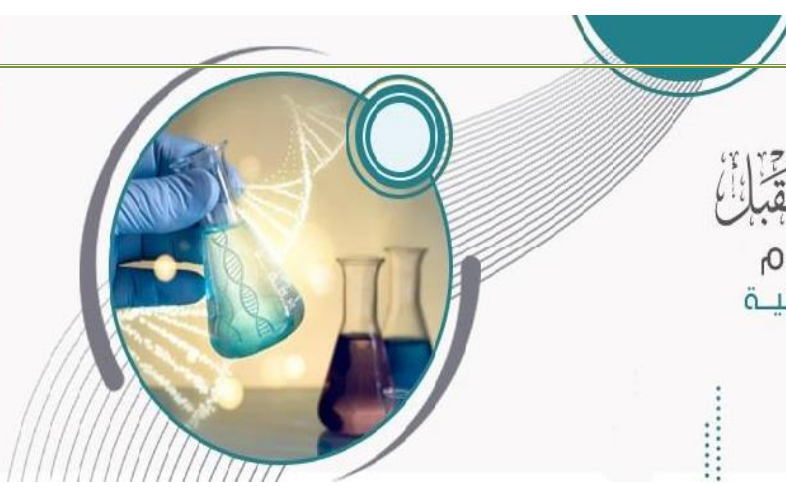



جامعة المستقبل
كلية العلوم
قسم الفيزياء الطبية



HUMAN ANATOMY

المرحلة الثالثة

Lec. 1 INTRODUCTION TO ANATOMY

BY
DR. MOHAMMED AL-MURIB

Why we study anatomy?

to provide a comprehensive understanding of how organisms work, from the microscopic level of cells and tissues to the macroscopic level of organ systems and the whole organism.

Animal Anatomy

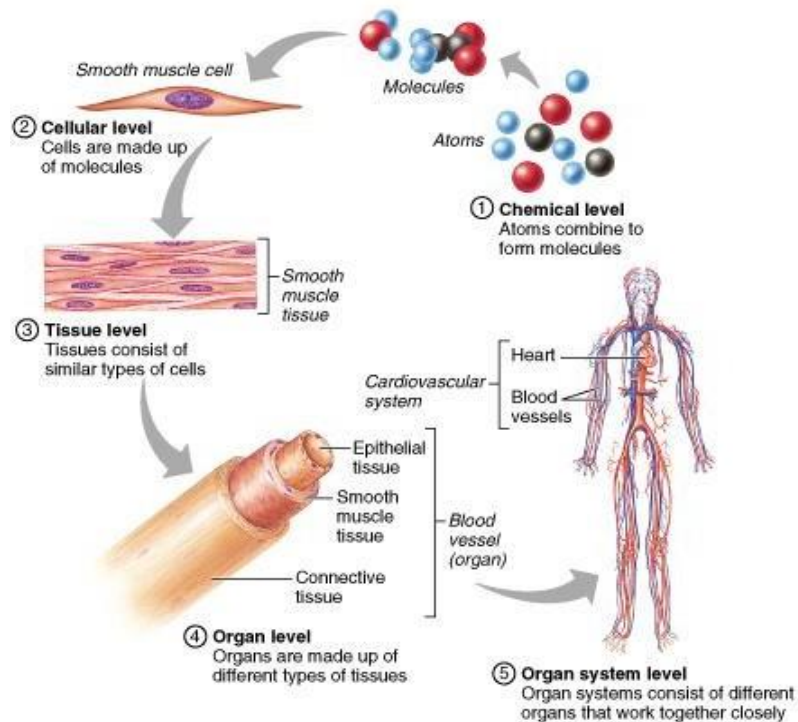
Definition - anatome = (ana) up + (tome) cutting

Disciplines of anatomy

- Gross Anatomy: structures studied with the naked eye.
 - Systematic anatomy: organized by systems, e.g., digestive, nervous, endocrine, etc.
 - Regional anatomy: study of all structures in an area of the body, e.g., upper extremity bones, muscles, blood vessels, etc.
- Microscopic anatomy (histology)
 - Cell biology
- Developmental anatomy (embryology)
 - Pathological anatomy
- Radiologic anatomy (x-ray, CT, MRI)
- Other areas? (surgery)

Levels of Structural Organization

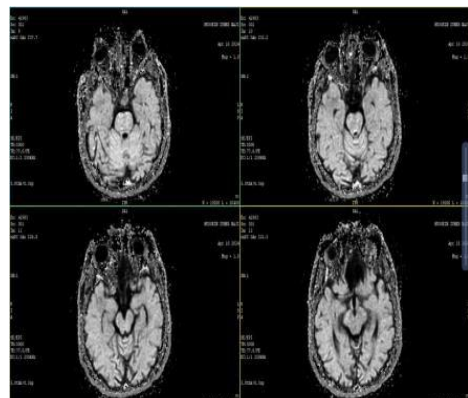
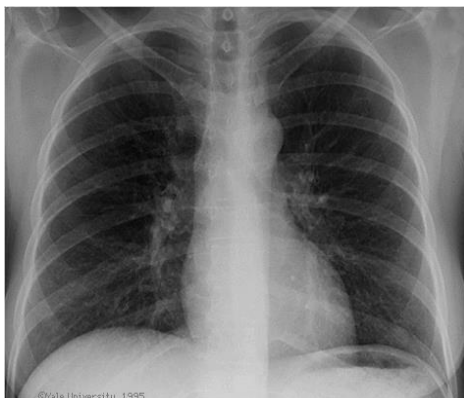
- Biochemical (atoms, molecules)
- Cellular
- Tissue
- Organ
- Organ system
- Organism



Copyright © 2001 Benjamin Cummings, an imprint of Addison Wesley Longman, Inc.

Medical Imaging Techniques

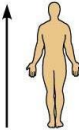
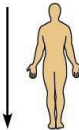


- X-rays
- CT Scan
- Ultrasound imaging
- MRI



Orientation and Directional Terms

TABLE

1.1 Orientation and Directional Terms

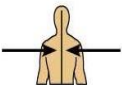
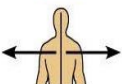


Term	Definition		Example
Superior (cranial)	Toward the head end or upper part of a structure or the body; above		The head is superior to the abdomen.
Inferior (caudal)	Away from the head end or toward the lower part of a structure or the body; below		The navel is inferior to the chin.
Anterior (ventral)*	Toward or at the front of the body; in front of		The breastbone is anterior to the spine.
Posterior (dorsal)*	Toward or at the back of the body; behind		The heart is posterior to the breastbone.

*Whereas the terms *ventral* and *anterior* are synonymous in humans, this is not the case in four-legged animals. *Ventral* specifically refers to the "belly" of a vertebrate animal and thus is the inferior surface of four-legged animals. Likewise,

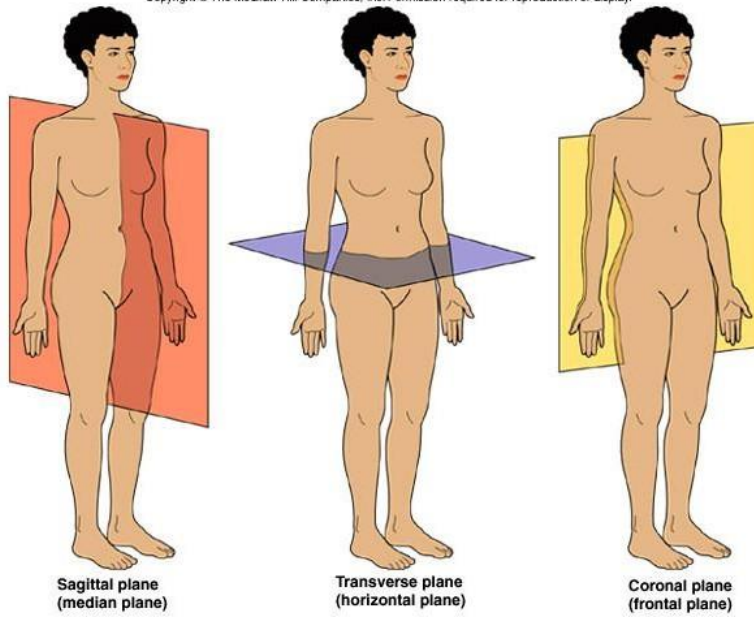
although the dorsal and posterior surfaces are the same in humans, the term *dorsal* specifically refers to an animal's back. Thus, the dorsal surface of four-legged animals is their superior surface.

TABLE

1.1 Orientation and Directional Terms

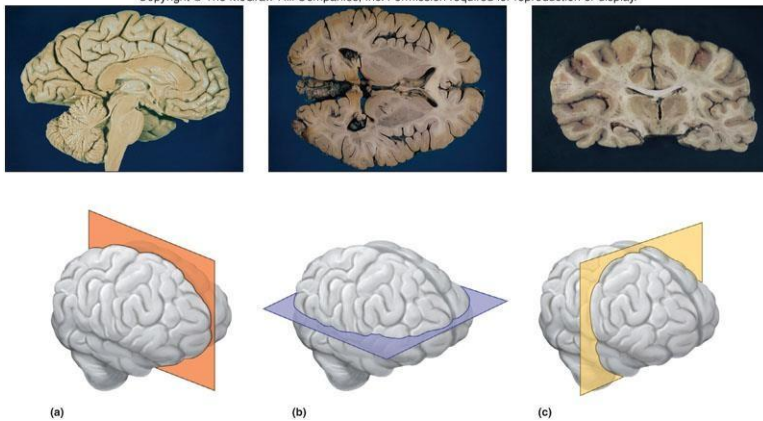
Term	Definition		Example
Medial	Toward or at the midline of the body; on the inner side of		The heart is medial to the arm.
Lateral	Away from the midline of the body; on the outer side of		The arms are lateral to the chest.
Proximal	Closer to the origin of the body part or the point of attachment of a limb to the body trunk		The elbow is proximal to the wrist.
Distal	Farther from the origin of a body part or the point of attachment of a limb to the body trunk		The knee is distal to the thigh.

Copyright © The McGraw-Hill Companies, Inc. Permission required for reproduction or display.

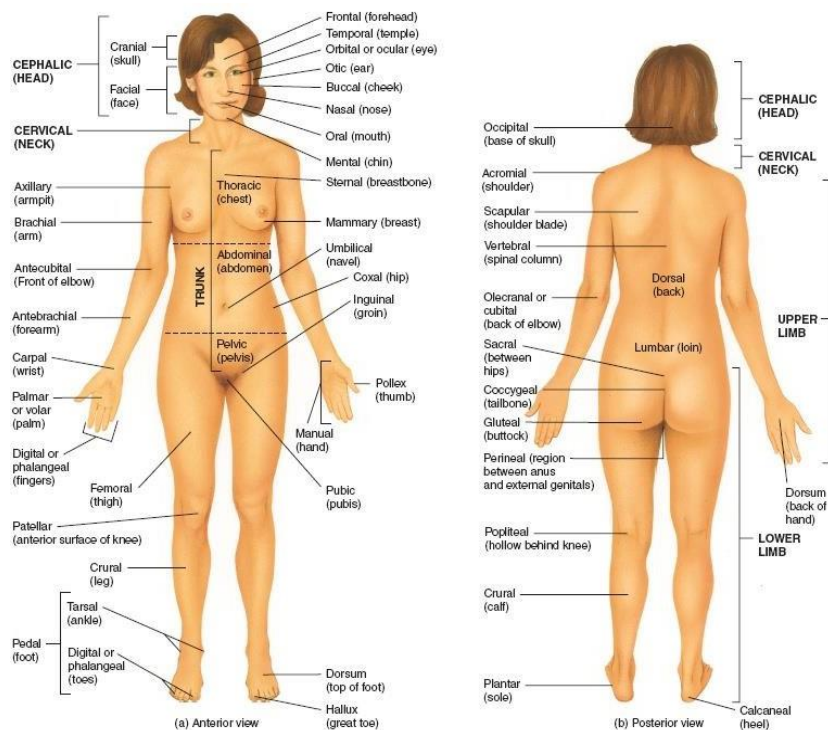
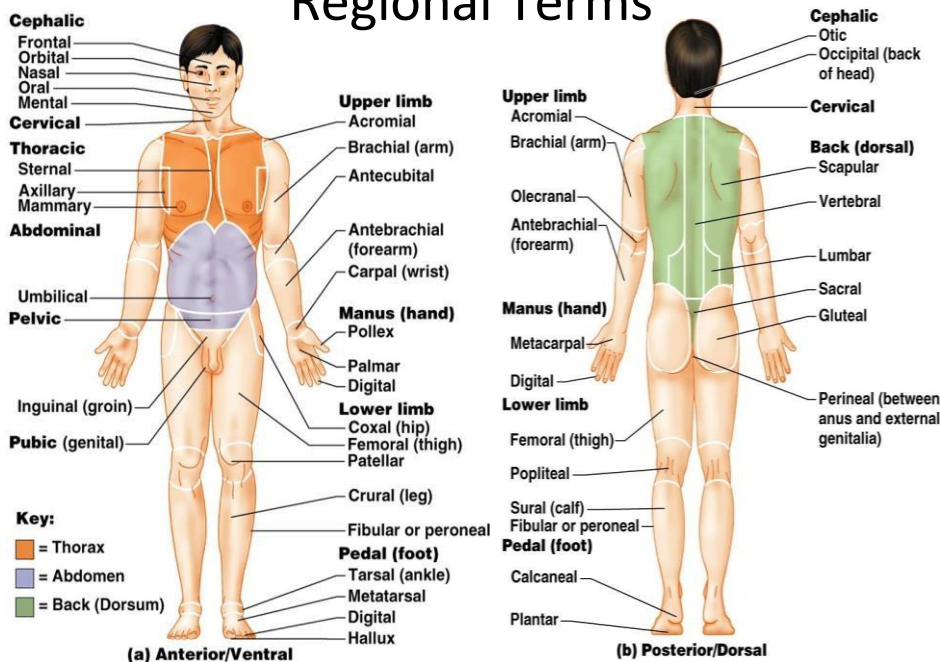


Body Sections

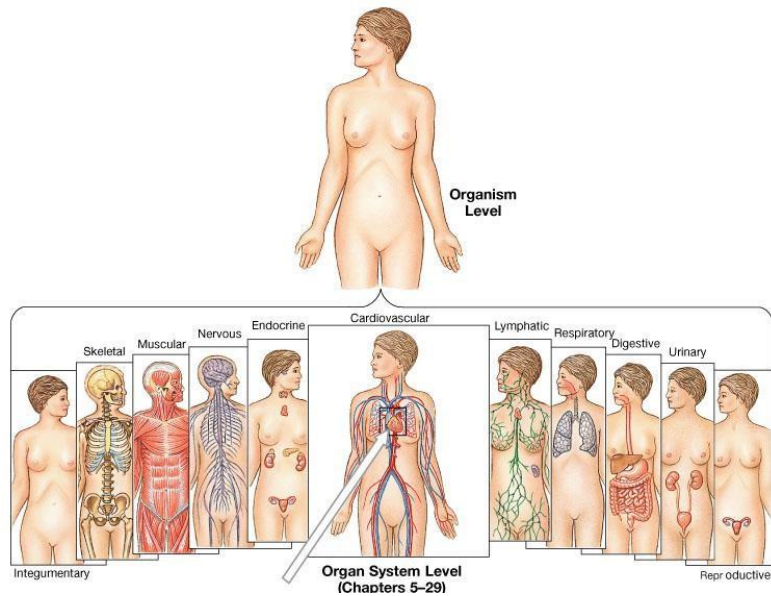
Copyright © The McGraw-Hill Companies, Inc. Permission required for reproduction or display.



Regional Terms



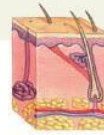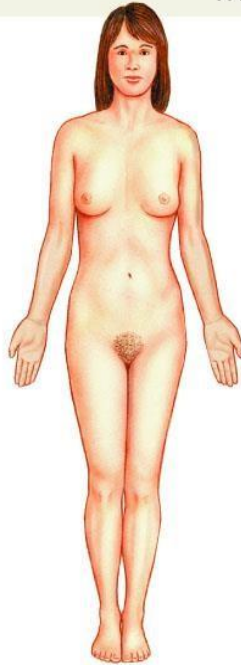
PHYSIOLOGY



Systems Physiology

- Integumentary system
- Nervous system
- Skeletal system
- Endocrine system
- Muscular system
- Cardiovascular system
- Lymphatic system
- Urinary system
- Respiratory system
- Digestive system
- Reproductive system

THE INTEGUMENTARY SYSTEM



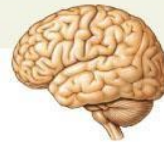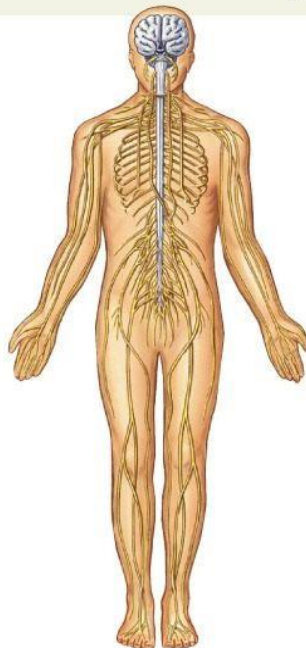
Major Organs:

- Skin
- Hair
- Sweat glands
- Nails

Functions:

- Protects against environmental hazards
- Helps regulate body temperature
- Provides sensory information

THE NERVOUS SYSTEM



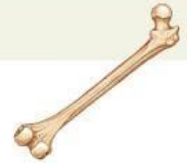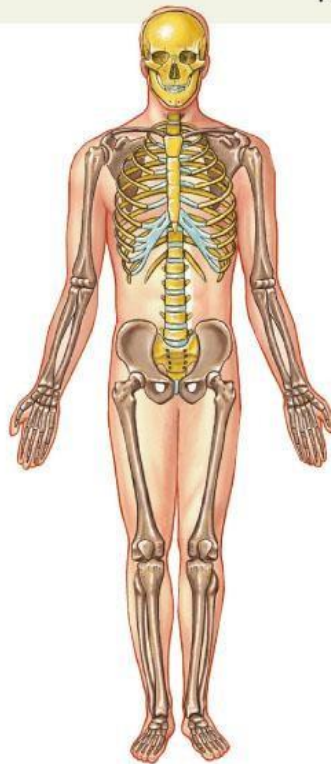
Major Organs:

- Brain
- Spinal cord
- Peripheral nerves
- Sense organs

Functions:

- Directs immediate responses to stimuli
- Coordinates or moderates activities of other organ systems
- Provides and interprets sensory information about external conditions

THE SKELETAL SYSTEM



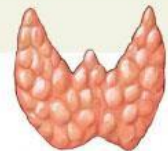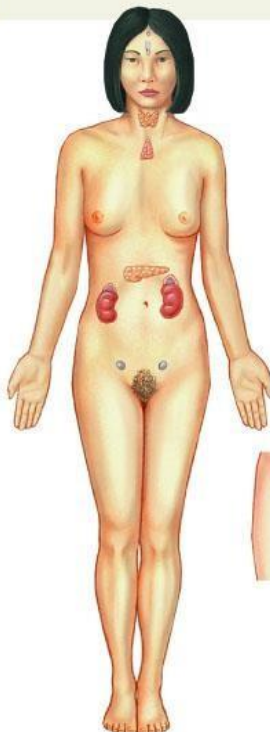
Major Organs:

- Bones
- Cartilages
- Associated ligaments
- Bone marrow

Functions:

- Provides support and protection for other tissues
- Stores calcium and other minerals
- Forms blood cells

THE ENDOCRINE SYSTEM

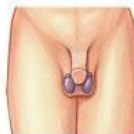

Major Organs:

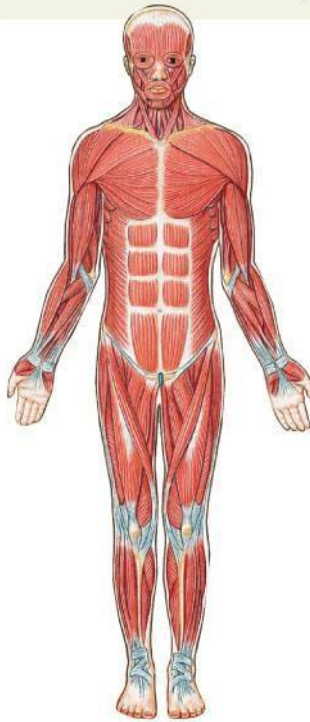- Pituitary gland
- Thyroid gland
- Pancreas
- Adrenal glands
- Gonads (testes and ovaries)
- Endocrine tissues in other systems

Functions:

- Directs long-term changes in the activities of other organ systems
- Adjusts metabolic activity and energy use by the body
- Controls many structural and functional changes during development



THE MUSCULAR SYSTEM



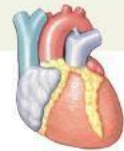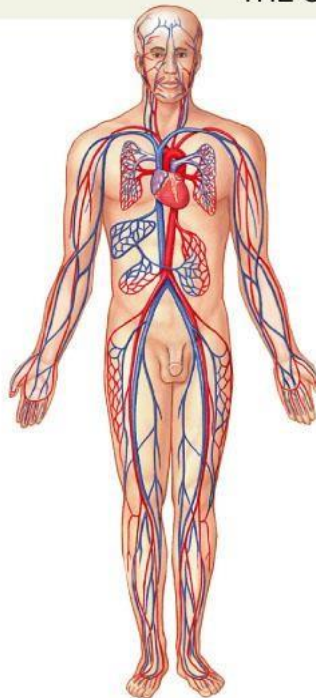
Major Organs:

- Skeletal muscles and associated tendons and aponeuroses (tendinous sheets)

Functions:

- Provides movement
- Provides protection and support for other tissues
- Generates heat that maintains body temperature

THE CARDIOVASCULAR SYSTEM



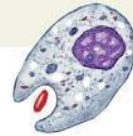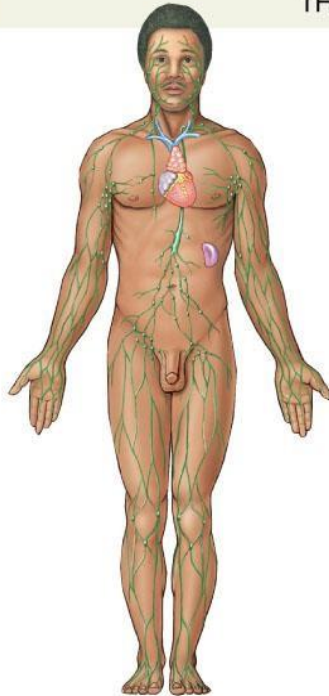
Major Organs:

- Heart
- Blood
- Blood vessels

Functions:

- Distributes blood cells, water, and dissolved materials, including nutrients, waste products, oxygen, and carbon dioxide
- Distributes heat and assists in control of body temperature

THE LYMPHATIC SYSTEM



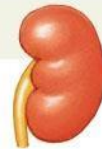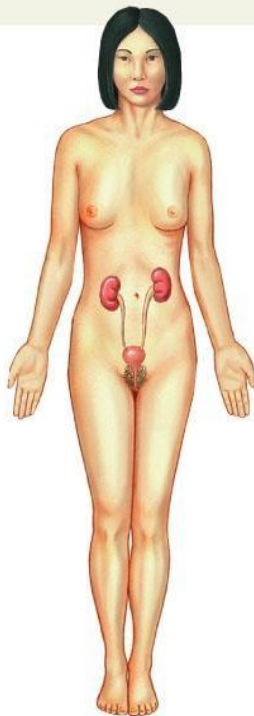
Major Organs:

- Spleen
- Thymus
- Lymphatic vessels
- Lymph nodes
- Tonsils

Functions:

- Defends against infection and disease
- Returns tissue fluids to the bloodstream

THE URINARY SYSTEM



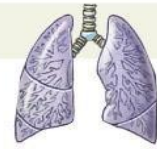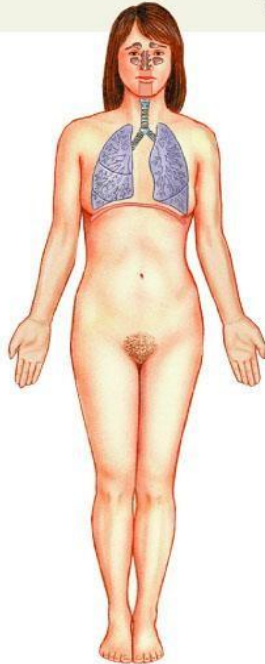
Major Organs:

- Kidneys
- Ureters
- Urinary bladder
- Urethra

Functions:

- Excretes waste products from the blood
- Controls water balance by regulating volume of urine produced
- Stores urine prior to voluntary elimination
- Regulates blood ion concentrations and pH

THE RESPIRATORY SYSTEM



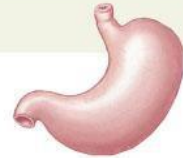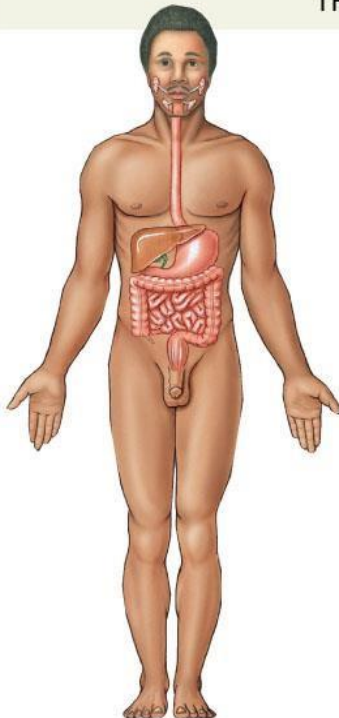
Major Organs:

- Nasal cavities
- Sinuses
- Larynx
- Trachea
- Bronchi
- Lungs
- Alveoli

Functions:

- Delivers air to alveoli (sites in lungs where gas exchange occurs)
- Provides oxygen to bloodstream
- Removes carbon dioxide from bloodstream
- Produces sounds for communication

THE DIGESTIVE SYSTEM



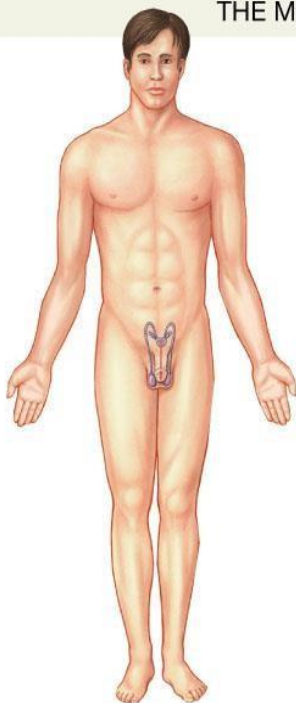
Major Organs:

- Teeth
- Tongue
- Pharynx
- Esophagus
- Stomach
- Small intestine
- Large intestine
- Liver
- Gallbladder
- Pancreas

Functions:

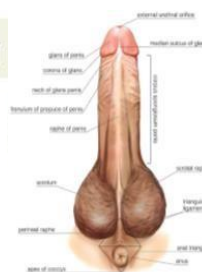
- Processes and digests food
- Absorbs and conserves water
- Absorbs nutrients (ions, water, and the breakdown products of dietary sugars, proteins, and fats)
- Stores energy reserves

THE MALE REPRODUCTIVE SYSTEM



Major Organs:

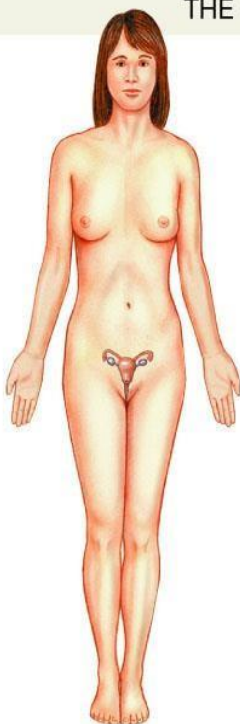
- Testes
- Epididymis
- Ductus deferens
- Seminal vesicles
- Prostate gland
- Penis
- Scrotum



Functions:

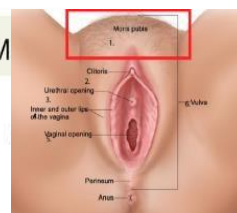
- Produces male sex cells (sperm) and hormones

THE FEMALE REPRODUCTIVE SYSTEM



Major Organs:

- Ovaries
- Uterine tubes
- Uterus
- Vagina
- Labia
- Clitoris
- Mammary glands



Functions:

- Produces female sex cells (oocytes) and hormones
- Supports developing embryo from conception to delivery
- Provides milk to nourish newborn infant