

Normal radiographic anatomy

The radiographic knowledge of disease requires a sound knowledge of the radiographic appearance of normal structures.

In this lecture we will study the normal anatomical landmarks of the teeth, supporting structure, maxilla, mandible and restorative materials in order to be able to distinguish the abnormal conditions.

The **density** of the structure being radiographed exerts a profound influence of the resultant image formed on a diagnostic radiograph

The greater density of an object, the greater attenuation of the x ray beam directed through the object which makes it a good absorber of x ray and such objects named radiopaque structures. On the other hand objects that are not a good absorber called radiolucent objects

Radiopaque: It refers to that portion of a processed radiograph that appear light or white. Radiopaque structures are dense and absorb or resist the passage of the x ray beam.

Radiolucent: refers to that portion of a processed radiograph that is dark or black. A structure that appears radiolucent on a radiograph lacks density and permit the passage of the x ray beam with little or no resistance such as air spaces.

****Teeth and supporting structures:****

Enamel:

Is the most radiopaque structure (most dense natural substance in the body).

Dentine: It appears less radiopaque than enamel and has the same radiopacity as the bone.

Cementum:

Is not usually apparent in the radiograph because there is a little difference between its density and that of dentin and also it is too thin layer.

Pulp:

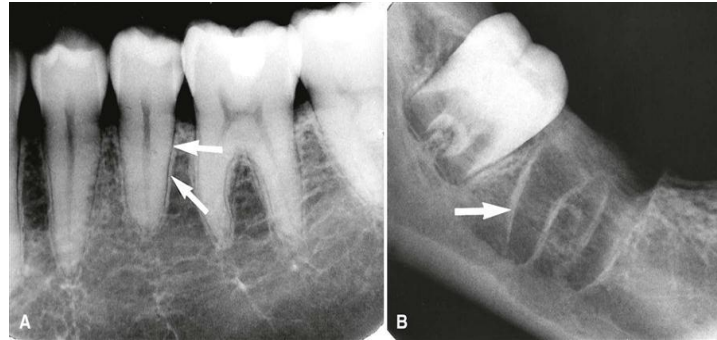
The pulp cavity consists of a pulp chamber and pulp canals. It contains blood vessels, nerves, and lymphatics and appears radiolucent on a dental image

Lamina dura:

The lamina dura is the wall of the tooth socket that surrounds the root of a tooth, it is made up of dense cortical bone. On a dental image, the lamina dura appears as a dense radiopaque line that surrounds the root of a tooth

Periodontal ligament space (PDL):

The periodontal ligament space (PDL space) is the space between the root of the tooth and the lamina dura. The PDL space contains connective tissue, blood vessels, and lymphatics. On a dental image, the PDL space appears as a thin radiolucent line around the root of a tooth

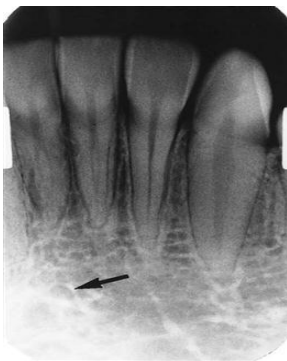

Lamina dura

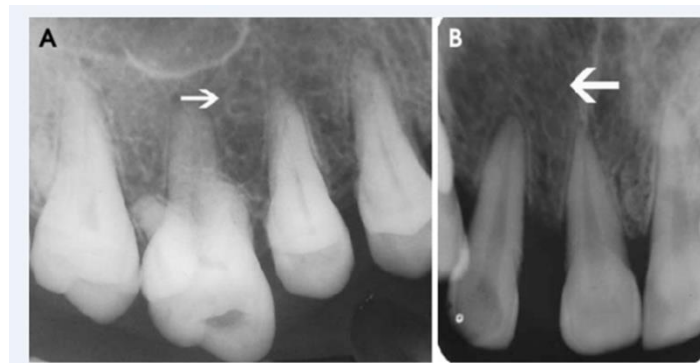Jaw bone:

The cancellous (trabecular) bone lies between the cortical plates in both jaws. It is a thin radiopaque plates (trabeculae) surrounding a small radiolucent pockets of marrow.

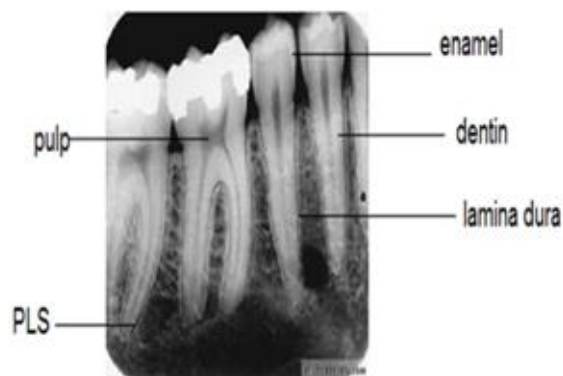
The trabeculae in maxilla are fine and arranged in a lace like pattern, where as in the mandible they are usually coarse and run in a horizontal pattern with larger space.



Mandible



maxilla



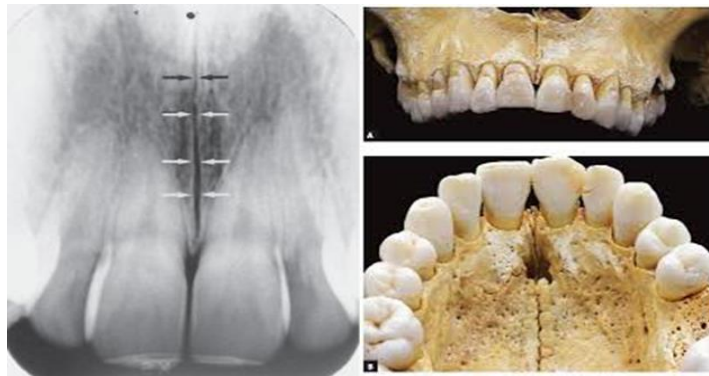
Normal tooth & supporting structures anatomy

****Normal landmarks in maxilla:****

Median palatine suture or intermaxillary suture:

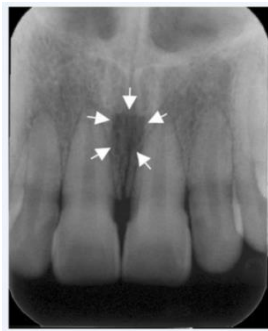
A thin radiolucent line in the midline between central incisors. It extends superiorly to the anterior nasal spine and posteriorly to the end of the hard palate.

This radiolucent line is bounded by two parallel radiopaque border of cortical bone.



Incisive foramen or nasopalatine foramen:

is an opening or hole in bone located at the midline of the anterior portion of the hard palate; the nasopalatine nerve exits the maxilla through the incisive foramen. Radiographically, it appears as a small, ovoid or round radiolucent area located between the roots of the maxillary central incisors



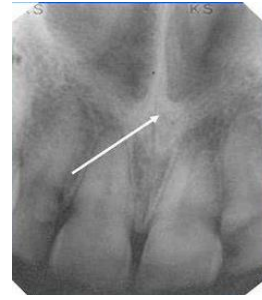
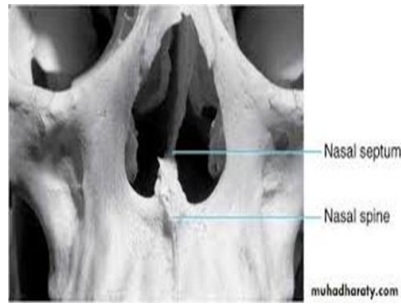
Incisive foramen

Anterior nasal spine:

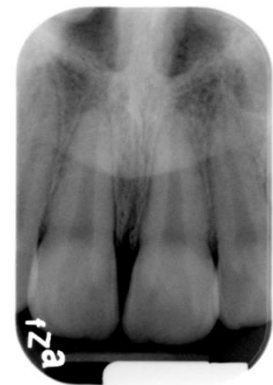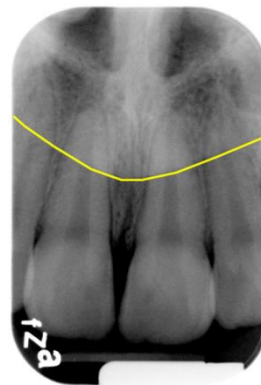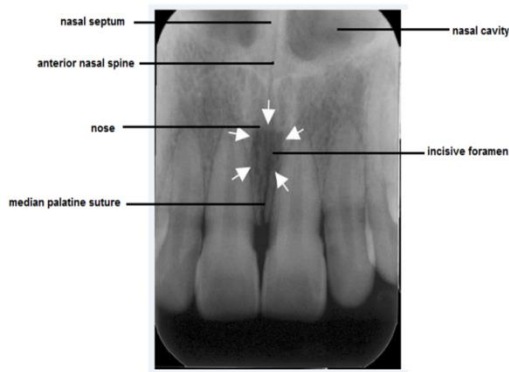
It is a sharp projection of the maxilla appears as a V shaped radiopacity located at the intersection of the floor of the nasal cavity and the nasal septum . It is located in the midline, approximately 1.5 to 2 cm above the alveolar crest.

Nasal septum: is a vertical bone that divides the nasal cavity into the right and left nasal fossae. It appears as vertical radiopaque line above central incisors that divides the nasal cavity. .

Nasal cavity: Bilateral radiolucency in radiograph of the incisors area. the floor of the nasal cavity appears as a dense radiopaque band of bone superior to the maxillary incisors



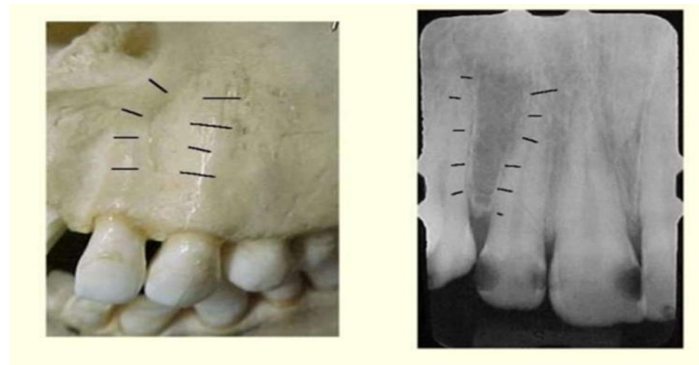
Nose: The soft tissue of the tip of the nose may be seen in the radiograph of the maxillary incisors. It has a uniform, slightly opaque appearance with a sharp border.



Radiograph of incisor area

Nose

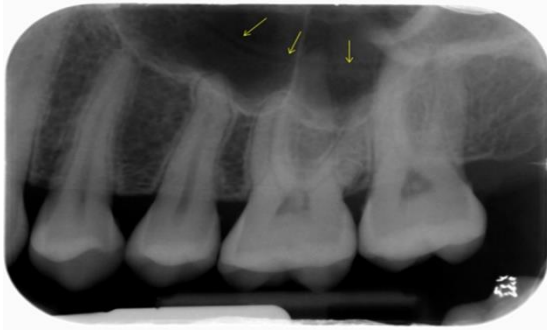Lateral fossa: is a smooth, depressed area of the maxilla located between maxillary canine and lateral incisors and appears as a radiolucent area.



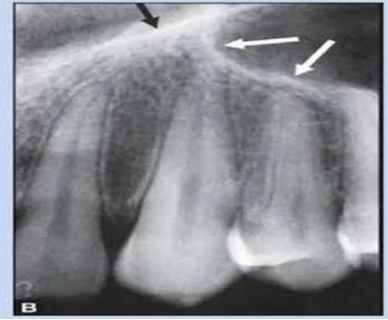Maxillary sinus:

It is a prominent radiolucency in radiograph of bicuspid area and molars and extends from the distal aspect of the canine to the tuberosity. The border of maxillary sinus appears as a thin radiopaque line (thin layer of cortical bone). Sometimes we can see thin folds of cortical bone project a few millimeters from the wall of the sinus or may extend across the sinus, these are named **septa**.

In the radiograph of canines the floor of the sinus and nasal cavity are superimposed forming an inverted Y shape in the area.

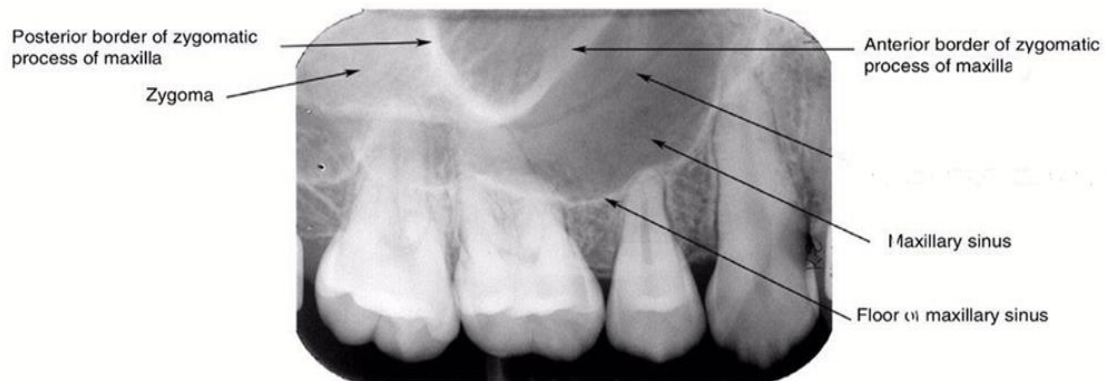


**Inverted Y-line
or Y line of
Ennis**



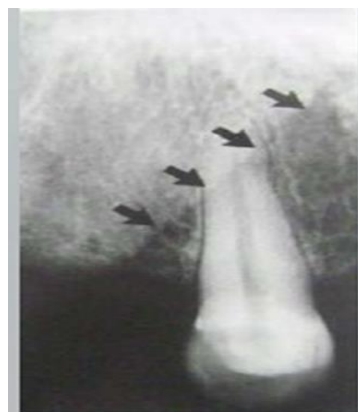Zygomatic process of maxilla and zygoma

is a bony projection of the maxilla that articulates with the zygoma. The zygomatic process of the maxilla appears as a J-shaped or U-shaped radiopacity located superior to the maxillary 1st molar region. The zygoma is extended as a radiopaque band posteriorly from this radiopacity to the zygomatic process of temporal bone.



Nasolabial fold:

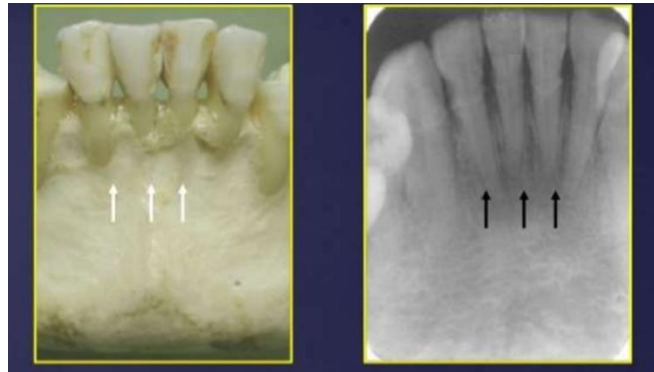It is an oblique line that can be seen in the radiograph of maxillary canine and premolar regions. It represents a difference in the thickness between labial and buccal fat pad.



Normal landmarks in mandible

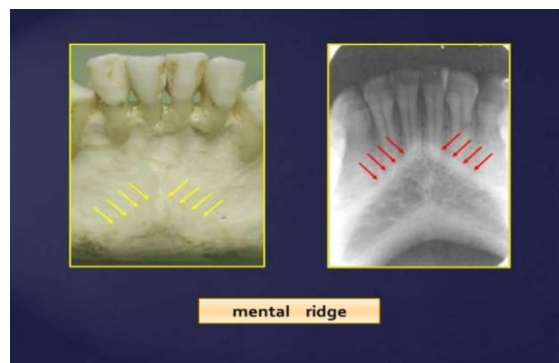
Mental fossae:

The mental fossa is a depressed area of bone located on the external (labial) surface of the anterior mandible above the mental ridge. Radiographically, the mental fossa appears as a radiolucent area overlying the roots of mandibular incisors.

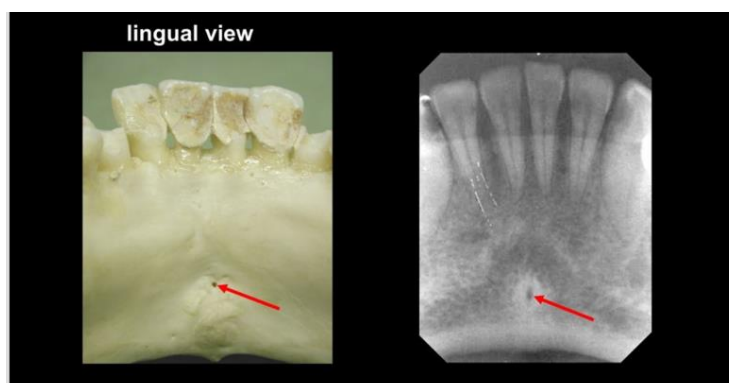


Mental ridge: It is a linear prominence of cortical bone located on the external surface of the anterior portion of the mandible.

On a mandibular periapical image, the mental ridge appears as a thick radiopaque band that extends from the premolar region to the incisor region

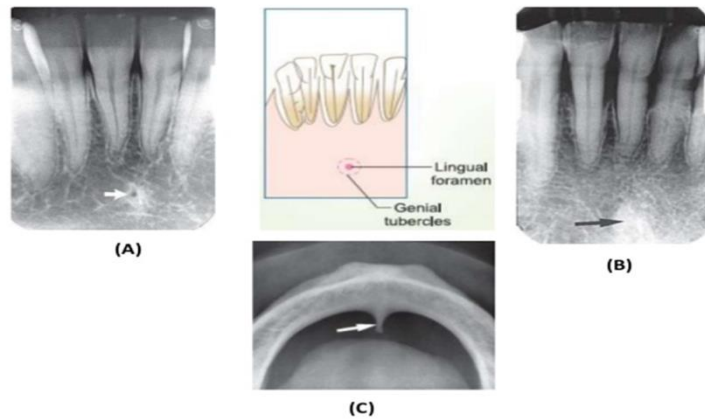


Lingual foramen: is a tiny opening or hole in bone located on the lingual surface of the mandible. The lingual foramen is located at the midline and is surrounded by genial tubercles. Radiographically, the lingual foramen appears as a small, radiolucent dot located inferior to the apices of the mandibular incisors.



Genial tubercles (also called mental spine) :

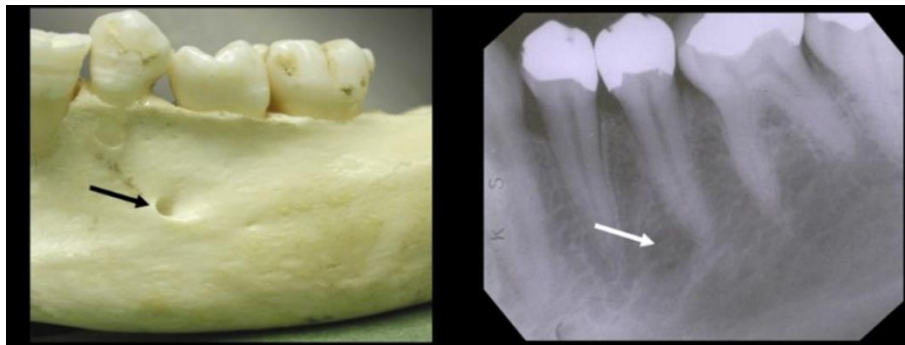
Is a bony protuberance located in the lingual surface of the mandible that serve as attachment sites for the genioglossus and geniohyoid muscles. On a periapical image, it appears as a ring-shaped radiopacity or as a radiopaque mass (3-4mm) inferior to apices of the mandibular incisors. They are well visualized on mandibular occlusal radiograph as one or more projections



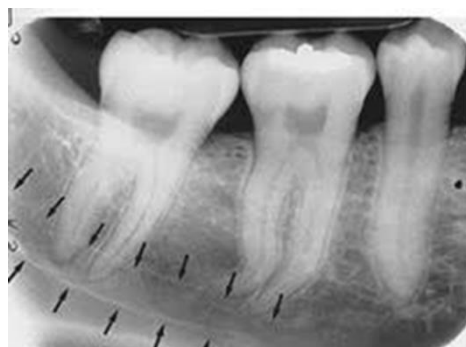(A) LINGUAL FORAMEN (B,C) GENIAL TUBERCLES

ANATOMICAL LANDMARKS, TOOTH AND ASSOCIATED STRUCTURES, SUNDARAM, II BDS, TMDC&H

Mental foramen: The mental foramen is an opening or hole in bone located on the external surface of the mandible in the region of the mandibular premolars. Radiographically; it appears as a small, ovoid or round radiolucent area located in the apical region . When superimposed on the apex of the tooth it may misdiagnosed as periapical pathology so a second radiograph from another angle will be helpful in reaching the correct diagnosis.

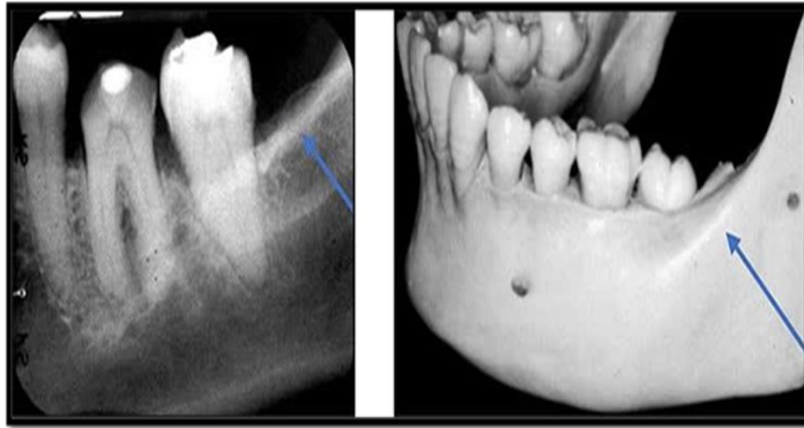


Mandibular canal (inferior dental canals): it extends from the mandibular foramen to the mental foramen and houses the inferior alveolar nerve and blood vessels . It appears as a radiolucent band extends with thin radiopaque superior and inferior borders.



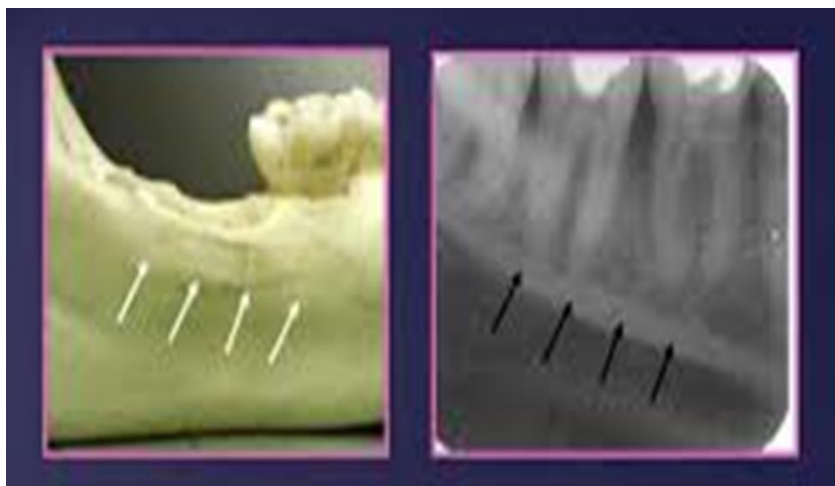External oblique ridge:

It is a continuation of the anterior border of the mandibular ramus appears as a linear prominence of bone on the external surface of the mandible. This bony elevation is gradually flattened until it disappeared in the area of first molar. It appears as a radiopaque line of varying width, density and length. It runs superior to the mylohyoid ridge in a parallel course



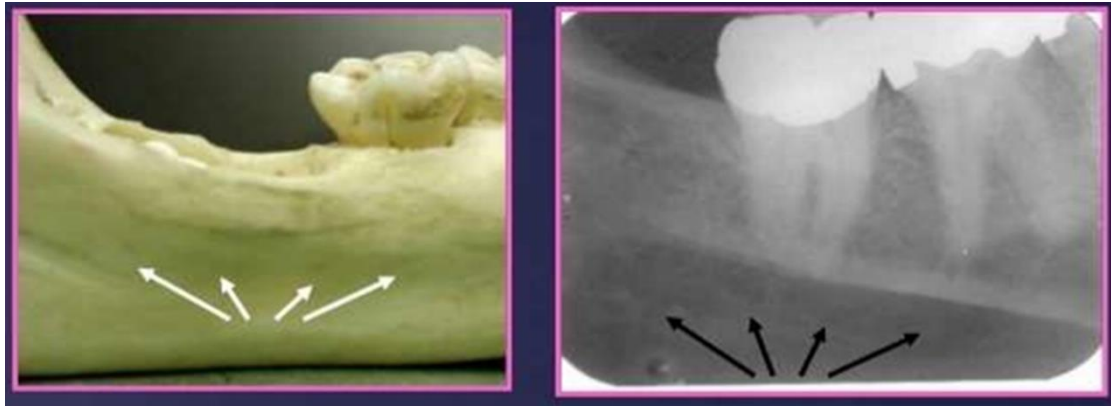
Internal oblique ridge (mylohyoid ridge):

It is a slightly irregular crest of bone on the lingual surface of the mandible, The mylohyoid ridge serves as an attachment site for a muscle of the same name. Radiographically it appears as a radiopaque structure below the external oblique ridge extending from the area of the third molar to the second premolar region, at approximately the level of the apices of the mandibular posterior teeth.



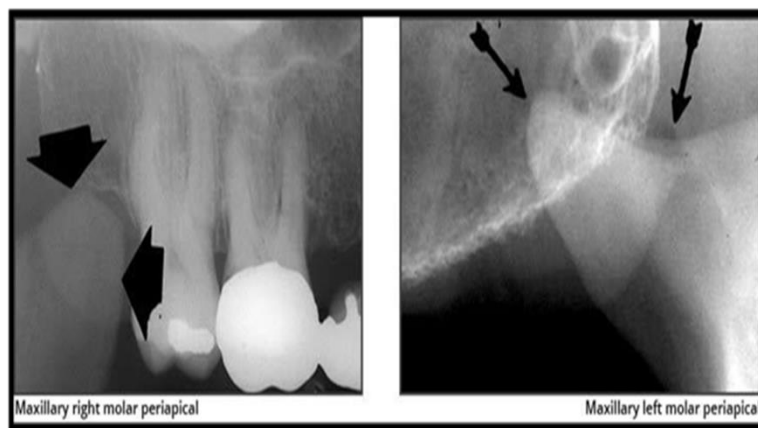
Submandibular gland fossa:

On the lingual surface of the mandibular body, immediately below the mylohyoid ridge in the molar area, there is frequently a depression in the bone. This concavity accommodate the submandibular gland and often appears as a radiolucent area in the molar region.



The coronoid process:

is not seen on a mandibular periapical image but may appear on a maxillary molar periapical image. The coronoid process appears as a triangular radiopacity superimposed to the maxillary tuberosity region.



*****Radiographic appearance of restorative materials:*****

1. Radiopaque restorative materials:

Amalgam, zinc oxide eugenol, zinc phosphate cement, gutta – percha, silver point, dental implant, metal crowns, metal wires and brackets.

. **2 . Radiolucent restorative materials:** Acrylic, silicate and porcelain.