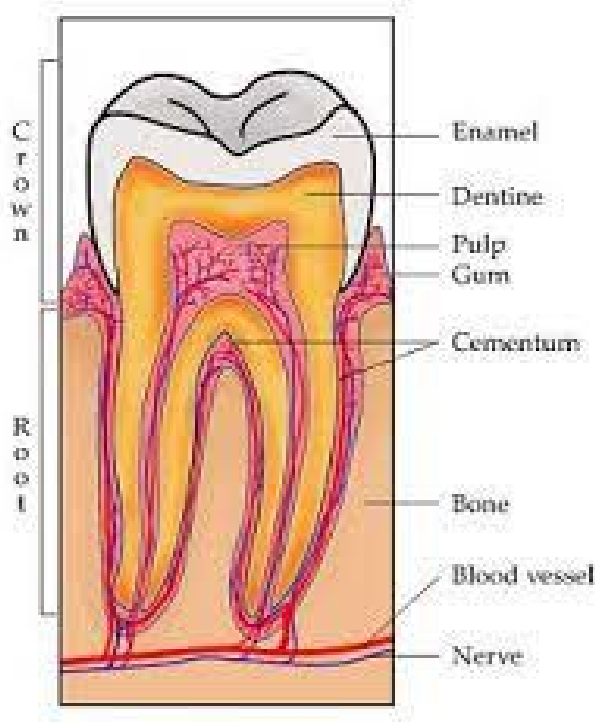


## Dentin

Dentin provides the bulk and general form of the tooth .It is a hard tissue contain tubules which it contains within it the processes of the specialized cells . It surround the pulp cavity and support the E. which covering the crown and it separated from E, by D.E.J.

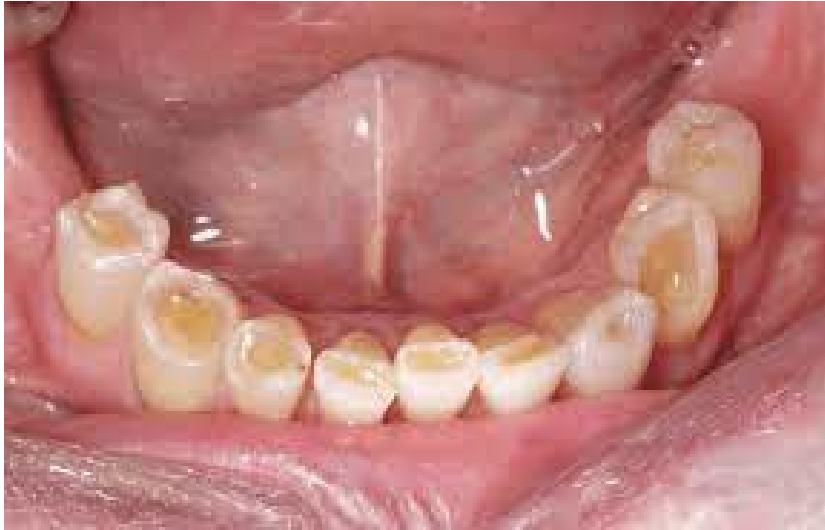

**Physically and chemically the dentin closely resembles bone.**  
The main difference between bone and dentin is that osteoblast that formed the bone become enclosed within bone matrix as osteocyte whereas the dentin contains only the processes of odontoblast cells.

### Physical properties;

- 1- Its slightly harder than bone and softer than E. This differences can be distinguished on radiograph on which D. appears more radiolucent(darker) than E. and more radio opaque(lighter) than pulp-

- 2- D. has an elastic quality that is important for the proper functioning of the tooth, because this provide flexibility and prevents fractures of overlying brittle E,
- 3- D. is pale yellowish in color



### **Chemical composition:**

- 1- Mature D, chemically composed of 70% inorganic **hydroxyapatite crystals  $\text{Ca}_3(\text{PO}_4)_2 \cdot \text{Ca}(\text{OH})_2$** , The crystals of D. are much smaller than those of E.  
30% organic (10% water by weight 20 %organic material consists of collagenous fibrils mostly type I collagen and ground substance of mucopolysaccharides).

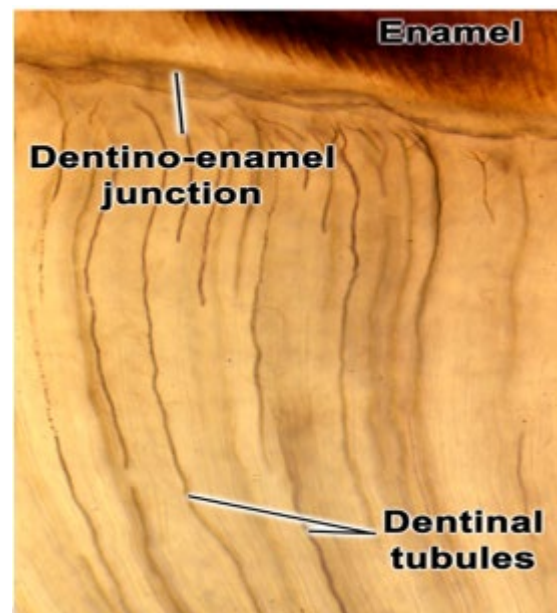
### **Dentinal tubule(D.T.):**

- D.T. are fine canals that contain tissue fluid and protoplasmic process of odontoblast cell (odontoblastic process).
- D.T, make the D. permeable and providing a pathway for entrance or invasion of bacteria caused dental caries and also

play an important role in D, sensitivity.

- The course of D.T. is somewhat curved, resembling an S shape known as primary curvature. Starting at right angles from pulpal surface, the first convexity of this doubly curved course directed toward the apex of the root ending perpendicular to D.EJ., this configuration indicate the course taken *by* odontoblasts during the dentinogenesis. Secondary curvature also can be distinguished over the entire length of D.T., they probably reflect the minor changes in the direction of movement of odontoblasts.
- In the root and in the area of incisal edge and cusps, the tubules are almost straight.
- « The ratio between surface areas at the outside and inside of the D, is about 5:1, so the tubules are farther apart in the peripheral layers and are more closely packed near the pulp. In addition they are larger in diameter near the pulpal cavity (3-4 micrometers) and smaller at their outer ends (1 micrometer).
- The terminal part of D.T, branched into 2-3 branches near D.EJ. resulting in the increase number of tubules in this area. Also there are lateral branches of D.T. which called canaliculi or microtubules.

#### 'S' CURVATURE OF DENTINAL TUBULES

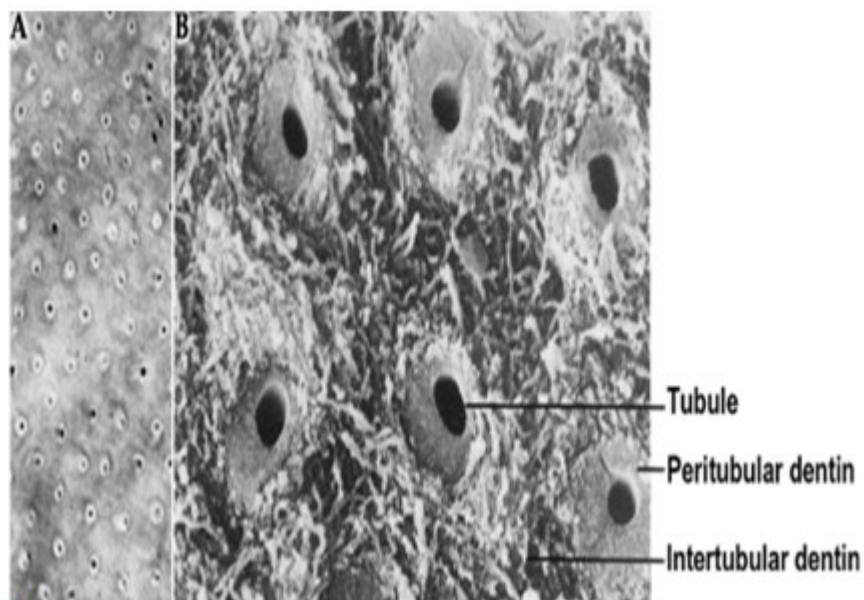


### **Peritubular Dentin:**

- \* it's the D, that surrounds the D.T. and form 1 micrometer thick sheath around each tubule. Peritubular D. is missing in D.T, in interglobular D. indicating that this is a defect of mineralization in this area.
- \* Peritubular D, is highly calcified and more calcified than adjacent intertubular D.

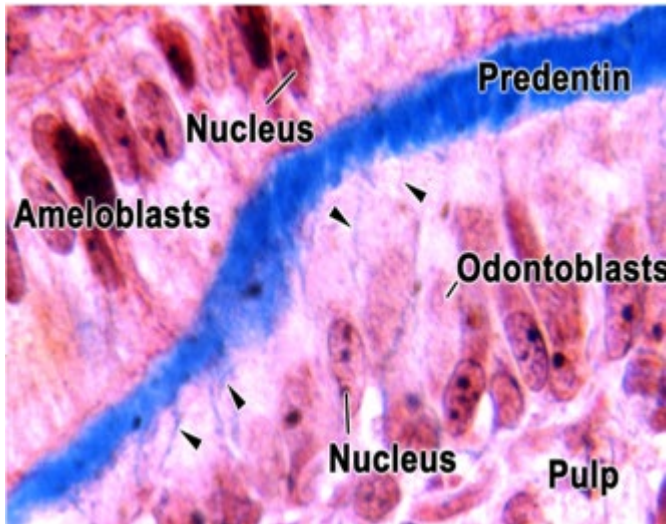
### **Intertubular D.:**

- It's the D. located between the D.T., and its formed the most of the body of D,
- Its less mineralized than the peritubular D., and it consist of network course of collagen fibers in which apatite crystals deposited on it.

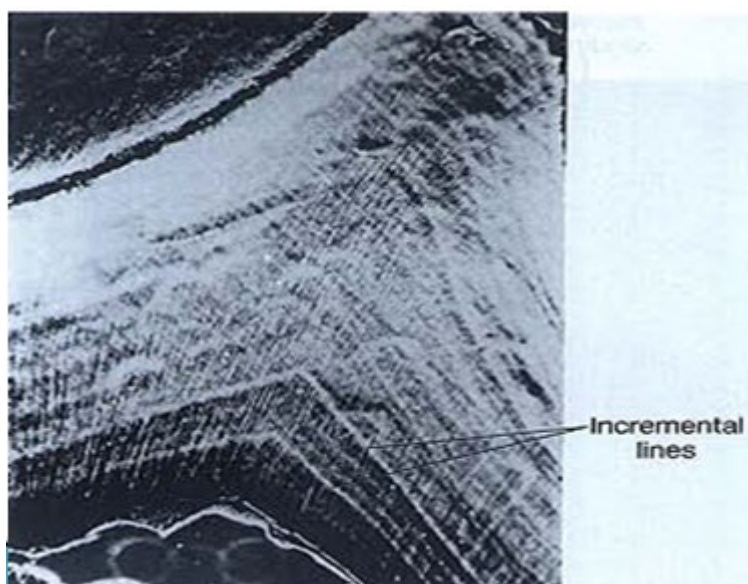


**Predentin:**

- Its unmineralized D. produced by odontoblasts and located adjacent to it in most of pulpal portion of D,
- Its thickness about 25-30 micrometer,
- \* It stained fighter than mineralized D. by H. and E. stain

**Incremental lines in D.:****1- Imbrication or von Ebner lines:**

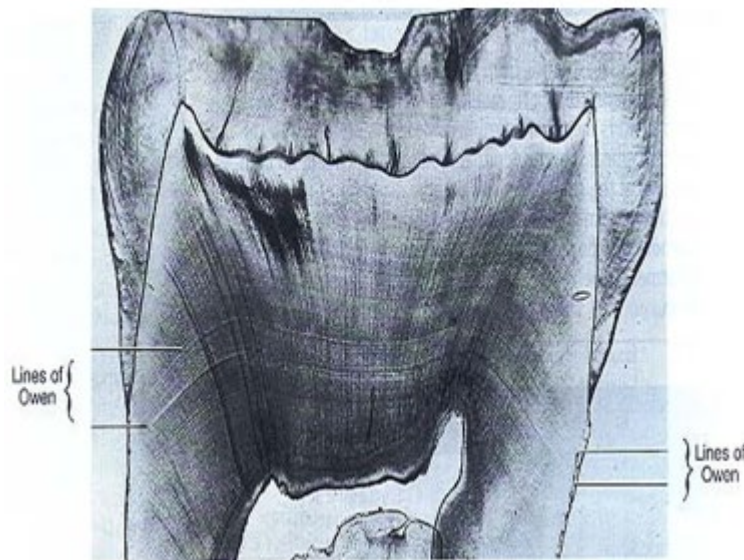
It appear as fine lines , which in cross section run at right angles to the D,T. The course of the lines indicates the growth pattern of the D. The distance between the lines corresponds to the daily rate of apposition, which in crown varies from 4-5 micrometers and becomes decreasingly less as root formation progress.





## 2-Contour lines of Owen:

Its hypo calcified line, it distinguish in longitudinal ground section as accentuated few lines .These lines arises due to disturbances in D. matrix and mineralization process.

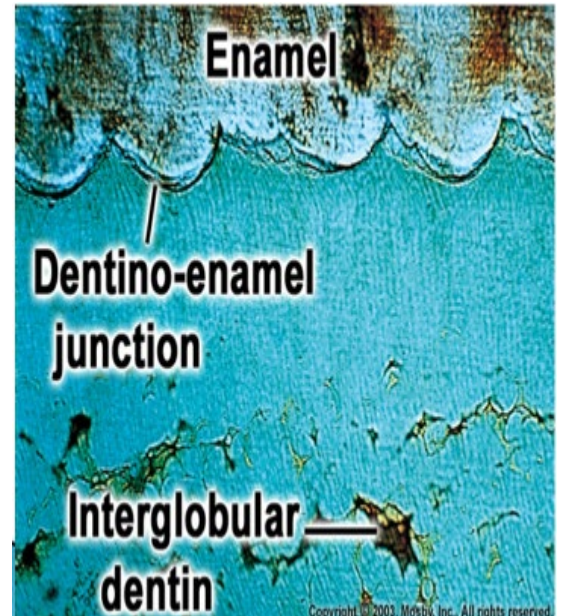
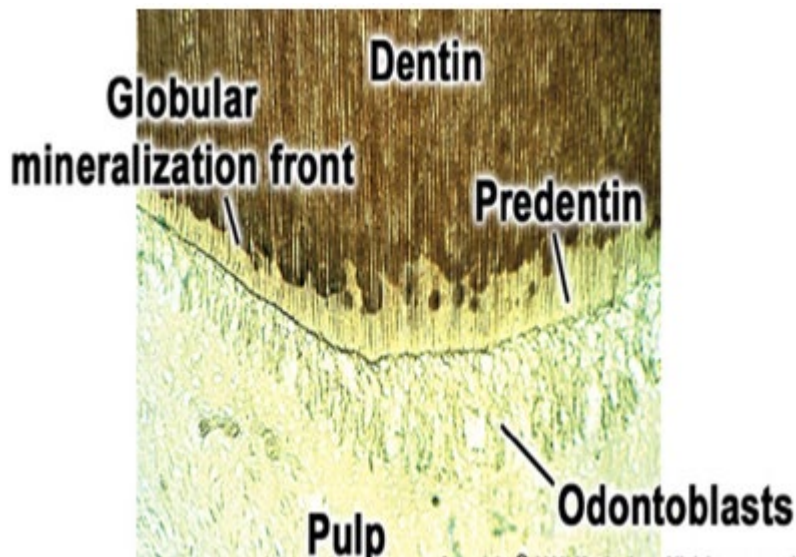


## 3-Neonatal lines:

This line separating between prenatal and post natal D., and mostly found in deciduous and first permanent molar. This line is the result of incomplete calcification, due to metabolic disturbances at the time of birth to the abrupt changes in environment and nutrition.

## Interglobular D.:

Mineralization of the D, sometimes begins in small globular areas that normally fuse to form a uniformly calcified D. layer. If fusion does not take place, unmineralized or hypomineralized regions remain between the globules, which termed interglobular D. This type of D. found in the crown in both sections (decalcified and ground sections) near the D.EJ. and in root near C.D.j, In ground sections is sometimes lost and replaced by air, so it appear black.



### **Tomes' granular layer:**

in the ground sections a thin layer of D. adjacent to cementum almost appears granular and only found in the root, this is known as Tomes' granular layer. It is believed to be caused by a coalescing and looping of the terminal portions of the D.T.

