

## LEC 5

# Periodontal surgery

Successful cause-related therapy (by the removal of plaque and calculus) will reduce gingival inflammation (edema, hyperemia and flabby tissue) thereby making assessment of true gingival contour and pocket depth possible.

In addition the soft tissue will be **more fibrous and thus firmer**, which facilitate surgical handling of the soft tissues. **The propensity for bleeding is reduced, making the inspection of the surgical field easier.**

The effectiveness of the patient's home care which is of decisive importance for the long term prognosis must be properly evaluated; **lack of effective self-performed plaque control** will often mean that the patient should be **excluded from surgical treatment.**

Transient root **hypersensitivity and recession** of the gingival margins frequently accompany the healing process following close and open scaling and root planning, thus the patient should be awarded that these results may happen.

## Objectives of periodontal surgery

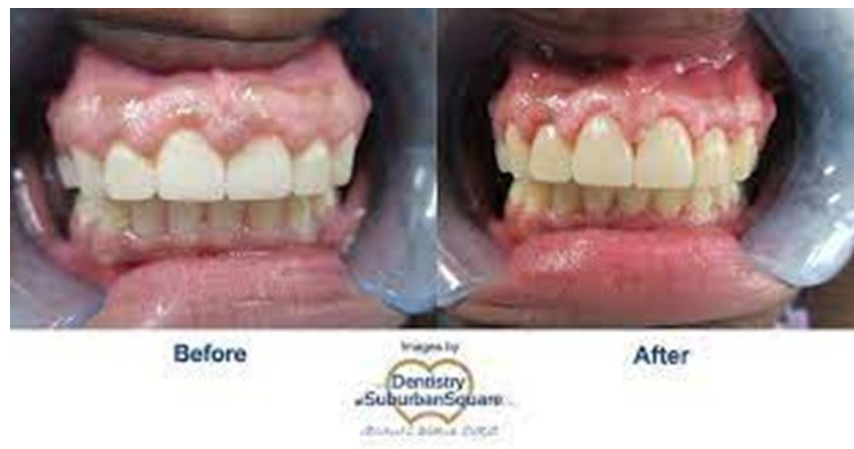- 1-Accessibility and direct vision for proper S+ RP
- 2-Reduction or elimination of plaque retentive area especially periodontal pockets that have not responded to initial therapy.
- 3-Eliminate inflamed periodontal tissue
- 4-Enhancing the regeneration of periodontal tissue
- 5-Create a physiologic morphology of the dentogingival area that will facilitate efficient self performed plaque control
- 6-Correct mucogingival defect and improve periodontal aesthetic
- 7-Provide access to correct bony defects

## **Surgical treatment include**

- 1-Gingivectomy for the removal of the over growth gingival tissues
- 2-Flap surgery
- 3-Distal wedge procedure
- 4-Mucogingival surgery for correction of mucogingival and aesthetic defect
- 5-Crown lengthening to increase clinical crown length
- 6-Guided tissue regeneration (GTR) to regenerate periodontal supporting structures

## **Gingivectomy**

This surgical procedure aimed at the **excision of the soft tissue wall of pathologic periodontal pocket** and this pocket elimination was usually combined with recontouring of the diseased gingiva to restore physiologic form(e.g. Drugs induced gingival enlargement and the resulting **false pocket** can be removed by this method)



## **Indication**

- 1-Gingival enlargement or over growth
- 2-Idiopathic gingival fibromatosis.
- 3-Shallow suprabony pocket

4-Minor corrective procedure

### **Contraindication**

1-Infrabony pocket

2-Thickening of marginal alveolar bone and the need for bone surgery

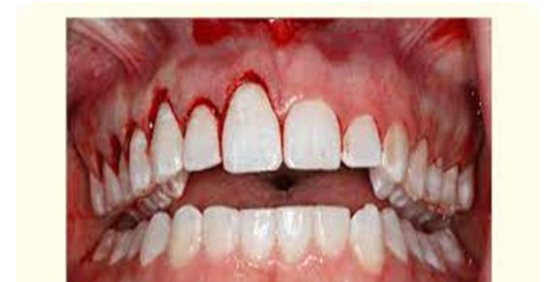3-Attached gingiva is narrow or absent

### **Advantage**

1-Technically simple, good visual access

2-Complete pocket elimination

3-Restoration of a physiologic gingival contour



### **Disadvantage**

1-Gross wound, post operative pain

2-Healing by secondary intention

3-Danger of exposing bone

4-Loss of attached gingiva

5-phonetics and aesthetic problem in the anterior area with sensitivity due to exposure of the cervical area of tooth

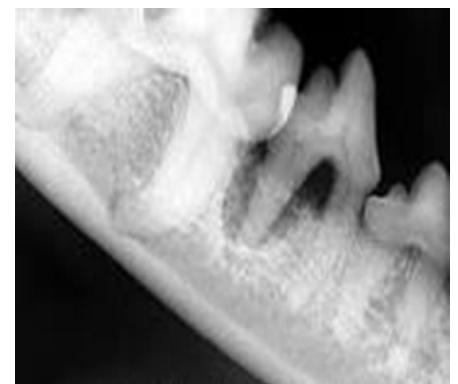
### **Flap surgery**

#### **Indications**

1-In treatment of infrabony pockets

2-When the gingivectomy will lead to an unacceptable aesthetic results

3-Osseous recontouring (elimination of bony defect)



## The Modified Widman flap

### Advantages

1-good access to root surface to facilitate S+ RP as well as the removal of the pocket epithelium and the inflamed connective tissue.

2-width of keratinized gingiva is maintained

3- replacement of the flap at presurgical location leads to less exposure of the root surfaces thus minimizes problem of aesthetic (especially anteriorly) and root hypersensitivity.

4-cause minimal amount of trauma to the periodontal tissues and discomfort to the patient.

5-the possibility of obtaining a close adaptation of the soft tissues to the root surfaces.

6-provides better access to re-establish proper contour of the alveolar bone as well as the potential for bone regeneration in sites with angular bony defect.

7-furcation areas can be exposed.

- Following flap procedures and the removal of plaque, calculus and chronically inflamed granulation tissue, healing occurs by the formation of a **long junctional epithelium**, this lead to reduced probing depth but that epithelium is more susceptible to plaque induced breakdown than the original connective tissue attachment and consequently **post-operative plaque control must be a very high standard**, a new connective tissue attachment may form following flap procedures, although this cannot be predicted with certainty.
- Modified widman flap ; reported in 1974 by Ramfjod and Nissle,it is a replaced flap. There are **three incisions** in this flap ,it is usually conducted as following:

## **Primary incision:**

### **A: scalloping incision**

The scalloped incision is performed on both labial and palatal aspects, using the double-edge 12B scalpel. It is an inverse bevel incision extending to the alveolar crest. This incision thins the gingival tissue and permits complete closure of the interdental osseous defects postoperatively. **The distance of the incision from the gingival margin may vary from 0.5 to 2mm.**

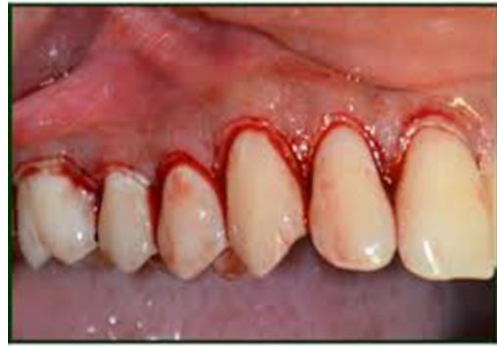

Fig 2: Inverse bevel incision on buccal side

**B: Flap reflection** An elevator is used to raise a **full thickness mucoperiosteal flap**. The flap is reflected only to permit direct visualization of the root surface and the alveolar crest. In most cases it is possible to stay within the boundaries of the attached gingiva, without extending beyond the mucogingival line.

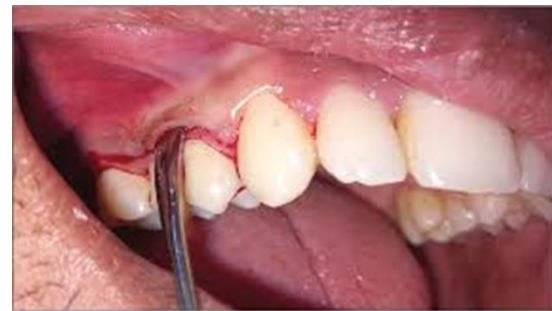

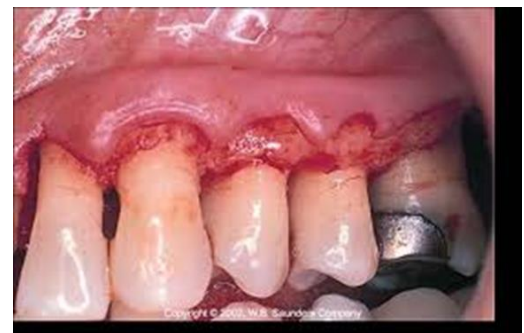Figure 3: Internal bevel incision given – Group 1

## **Secondary incision: Crevicular incision**

This incision is carried around each tooth, between the hard tooth structure and the diseased pocket epithelium, to the depth of the junctional epithelium. The 12B scalpel is used.

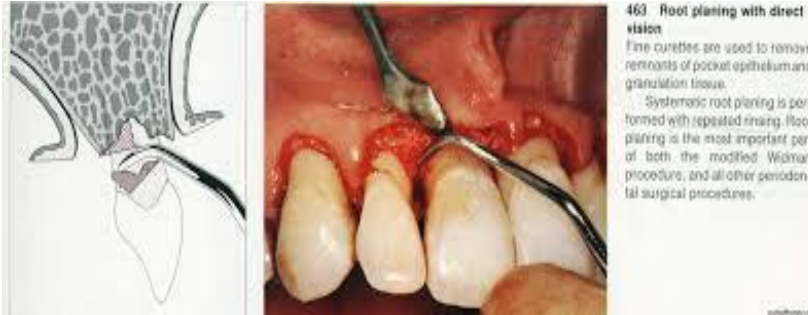### **Third incision: Horizontal incision**

The horizontal incision is carried along the alveolar crest thus separating the infiltrated tissue from healthy supporting connective tissue, specially in the interdental area. The incision also permits atraumatic removal of the diseased tissue.



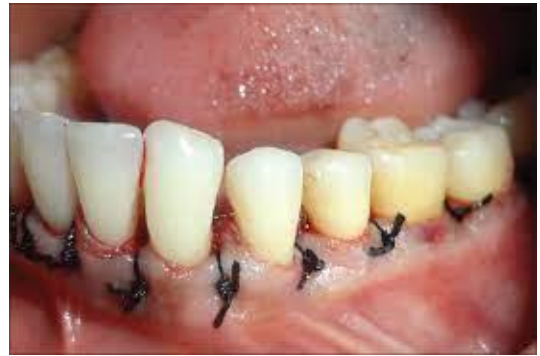### **Direct root planning:** Root planning with direct vision

Fine curettes are used to remove remnants of pocket epithelium and granulation tissue, calculus necrotic cementum to obtain **smooth, hard, clean surface**. Root planning is performed with repeated rinsing. **Root planning is the most important part of both the modified Widman procedure and all other periodontal surgical procedures.**



### **Suturing:**

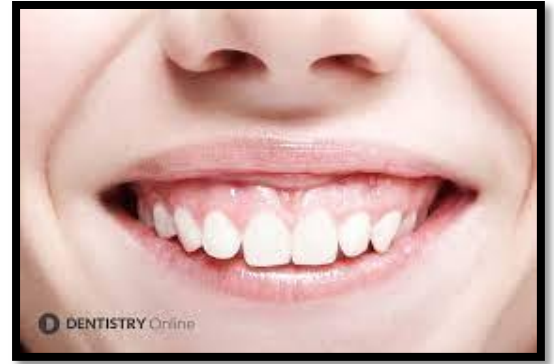Complete coverage of interdental defects  
The labial and palatal flaps are closed over the interdental areas without tension, using interrupted sutures. The flaps should be adapted to the underlying bone and the necks of the teeth. New papillae where created by the scalloped form of the initial incision. These make it possible to cover interdental defects (e.g. Bony defects) even when the interdental space is wide. For this reason, placement of a periodontal dressing is not absolutely necessary.



### **Gummy smile diagnosis and treatment**

- Gummy smile or “high smile line” or “gingival smile line” is a condition characterized by **excessive exposure of maxillary gingiva during smiling**. Excessive gingival display / Gummy smile is a **descriptive term rather than a diagnosis**, which would mandate the initiation of a specific therapy.

**When planning a treatment for gummy smile the key is to diagnose the reason for excessive gingival margin to lip distance when the patient smiles.**



A gummy smile is a highly **subjective** diagnosis that shows tremendous variability over dental and non-dental populations.

When patients identify gingival display as an area of concern, a restorative dentist has to be able to determine the etiology prior to investigating treatment options. **The gingival level is the gingiva to lip relationship.** A study conducted asked a group of lay people, orthodontists and general practitioners what they thought about acceptable gingiva levels for smiles. The results are somewhat surprising.

**Lay people:** Those who were not professionals viewed the threshold at 3mm; when the gums hit the 3 mm mark they rated the smile as less attractive.

**Orthodontists:** Orthodontists rated their threshold at 2 mm, the strictest requirement in the study group.

**General practitioners:** Surprisingly, the threshold was 4 mm, the most lenient of the study group.

The important question is: When do we treat a gummy smile? When it bothers the patient.

The ideal target is to get somewhere under 3 mm for patients who desire to change their smiles. Before treatment, it's necessary to understand exactly what causes a gummy smile.

There are at least seven different causes, and if you don't diagnose the cause correctly, you're going to pick the wrong treatment for your patients.

## The Seven Causes

1. Short upper lip (if a patient has an extremely short upper lip it's not going to cover gingiva and their upper teeth)
2. Hypermobile lip (lip moves too much)
3. Vertical maxillary excess VME (short ramus and overgrowth of maxilla)
4. Anterior over-eruption (excess overbite)
5. Wear and compensatory eruption
6. Altered active eruption (the teeth don't make it out of bone)
7. Altered passive eruption (gingiva doesn't recede as the person matures)

## **Three Traditional Methods for Treating a Gummy Smile**

**Orthodontics:** Intrudes over erupted teeth and levels them to correct position so that it eliminates gingival display.

**Periodontal surgery:** Crown lengthening to move gingival levels apically, typically performed on short teeth.

**Orthognathic surgery:** Moves the maxilla in an apical direction impacting the maxilla.

- For instances when these traditional methods of treatment won't work, such as a **patient has a hypermobile lip**, there are a couple of non-traditional methods:

**Botox:** Studies suggest Botox, when injected into the muscles of the upper lip can to be an effective method; however, the improvement is temporary and must be repeated every three to six months.

**Lip repositioning surgery:** Severs the muscles that elevate the lip so it can no longer rise as far in a smile. An irreversible solution diagnosis is the key to a successful outcome

