



## Department of biology



## Department of biology

((Invertebrates))

2 stage

**Lab 6**

**Dissect a rabbit**

**By**

**Duha Abd Al-ameer**



## Department of biology



### **Rabbit**

A rabbit is a small mammal, characterized by its long ears, short and thin tail, and strong hind legs. The rabbit carries four incisors in its mouth, two of which are located in front of two other smaller incisors. This feature distinguishes rabbits from rodents, which carry only two incisors. There are two groups of rabbits: domestic rabbits and wild rabbits. Wild rabbits do not differ much from domestic rabbits, as their entire body is oval, and the color of their soft fur tends to be brown or gray, with the presence of other colors. Domestic rabbits, in general, are smaller than wild rabbits, and their length ranges between 20 and 50 cm, and their weight ranges between 0.4 and 2 kg. The rabbit can see at an angle of up to 360 degrees, and has a blind area only at the level of the nasal septum.

Some rabbits are about the size of a cat, some may be as big as a small child, and there are some dwarf rabbits Which may reach a length of 20 cm, and weigh approximately less than 405 grams, while the length of the larger species reaches up to 50 cm, and weighs more than 4.5 kg

### **Steps to dissect a rabbit**

#### **Tools and materials used**

Live rabbit - dissecting board - dissection tools - dissecting microscope - chloroform - cotton

Autopsy steps:

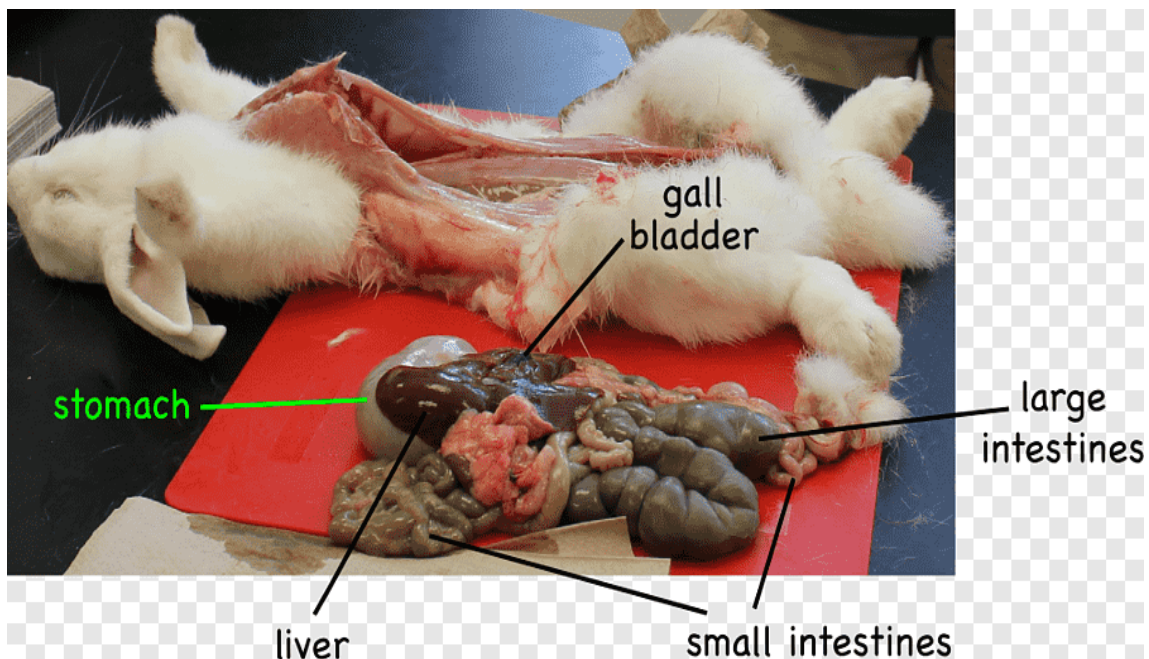
- 1- Anesthetize the rabbit with chloroform and place it on its back on a dissecting board.
- 2- Secure its edges with nails.



## Department of biology



- 3- Lift the abdominal skin with forceps and cut it with scissors, lengthwise, facing forward, until it reaches near the mouth.
- 4- Cut the skin crosswise along the front and back limbs.
- 5- Separate the skin from the muscles using your finger and scalpel and secure the skin on both sides with nails.
- 6- Cut the abdominal muscles, starting from back to front, using tweezers and scissors
- 7- Cut the abdominal wall behind the chest from the ventral-dorsal side, parallel to the ribs.
- 8- Open the chest space by cutting along the sternum and on both sides of the ribs.
- 9- Examine the internal organs



Dissect a rabbit