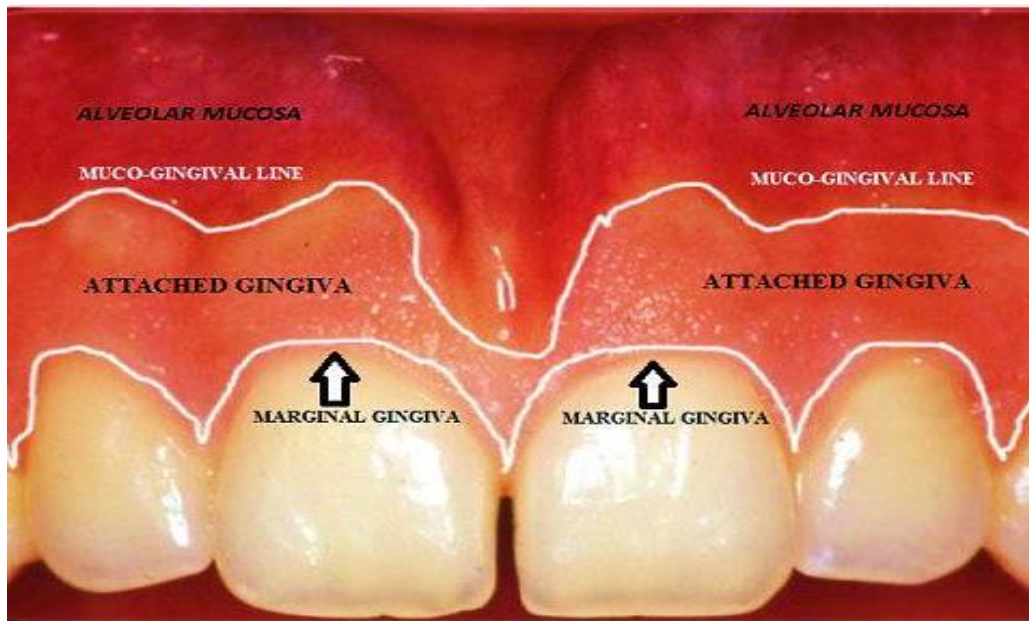


## Correlation between the clinical and microscopic features of the gingival tissue

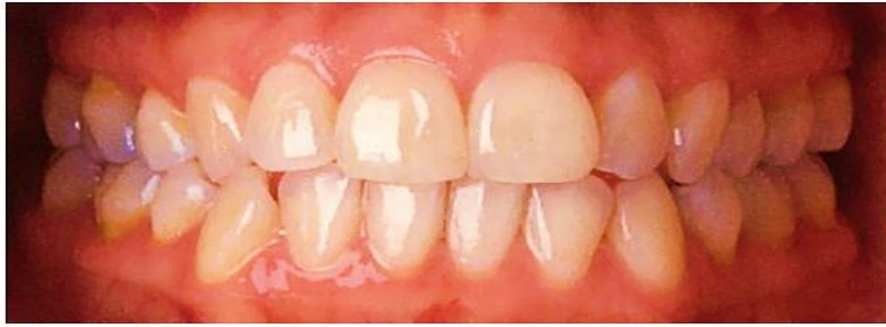### ❖ Color

The color of the attached and marginal gingiva displays a range from brown, orange to pink; **it results from** the colors of the vascular supply, the thickness and degree of keratinization of the epithelium, and the pigment-containing cells. The attached gingiva is demarcated from the adjacent alveolar mucosa on the facial aspect by a clearly defined **mucogingival line**. The alveolar mucosa is red, smooth, and shiny rather than pink and stippled. A comparison of the microscopic structure of the attached gingiva with that of the alveolar mucosa provides an **explanation for the difference in appearance**. The epithelium of the alveolar mucosa is thinner and non-keratinized, and it contains no rete pegs. The connective tissue of the alveolar mucosa is loosely arranged, and the blood vessels are more numerous. The color of **inflamed gingiva** may vary from red to bluish red **due to** vasodilatation which leads to bleeding tendency.

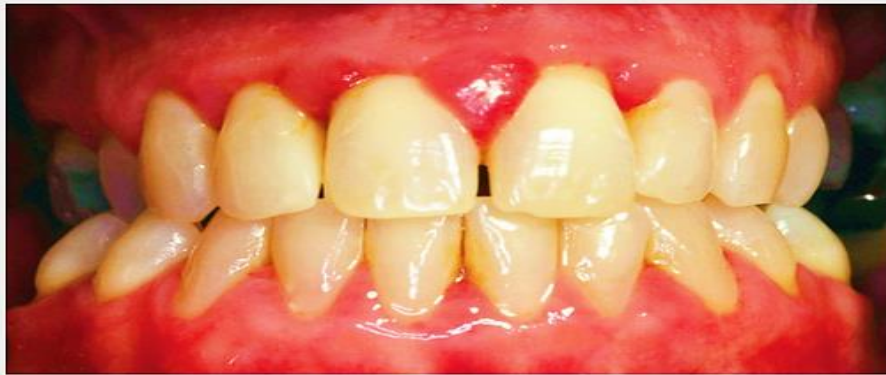

**Fig. Features of the attached gingiva and alveolar mucosa.**

Healthy Gums:



Unhealthy Gums:



**Fig. The differences between the healthy and diseased gingiva.**

**Physiologic Pigmentation (Melanin):-** Melanin is a non–hemoglobin-derived brown pigment with the following characteristics:

- ❖ It is located in the intercellular vesicles of melanosomes.
- ❖ It is responsible for the pigmentation of the skin, the gingiva, and the remainder of the oral mucous membrane.
- ❖ It is present in all individuals (often not in sufficient quantities to be detected clinically), but it is absent or severely diminished in individuals with genetic pigmentation disorders.
- ❖ Color variations relate to the quantity of melanin synthesized and degraded.
- ❖ **Ascorbic acid** directly down regulates melanin pigmentation in gingival tissues.

**☒ Size**

The size of the gingiva corresponds with the sum total of the bulk of cellular and intercellular elements and their vascular supply. **Alteration in size** is a common feature of gingival disease.

## ☒ Contour

The contour of the gingiva **depends on** the shape of the teeth and their alignment in the arch, the location and size of the area of proximal contact, and the dimensions of the facial and lingual gingival embrasures. The gingiva **usually ends coronally** in knife edged margins and scalloped in contour. In **inflamed gingiva**, the contours are often rounded and enlarged **because** of vascular stagnation and increases formation of collagen fibers.

## ☒ Shape

The shape of the interdental gingiva is **administrated by** the contour of the proximal tooth surfaces and the location and shape of the gingival embrasures. When the proximal surfaces of the crowns are relatively flat faciolingually, the roots are close together, the interdental bone is thin mesiodistally, and the gingival embrasures and interdental gingiva are narrow mesiodistally. Conversely, with proximal surfaces that flare away from the area of contact, the mesiodistal diameter of the interdental gingiva is broad. The height of the interdental gingiva varies with the location of the proximal contact. Thus in the **anterior region** of the dentition, the interdental papilla is pyramidal in form, whereas the papilla is more flattened in the **molar region**. The lateral border and tip of the interdental papilla are formed by continuation of marginal gingiva and the intervening portion by the attached gingiva. In the presence of diastema the Interdental papilla will be absent.

The shape of Interdental gingiva depends on:-

- ❖ The contact relationship between the teeth.
- ❖ The width of the proximal tooth surfaces
- ❖ The course of the cemento-enamel junction.

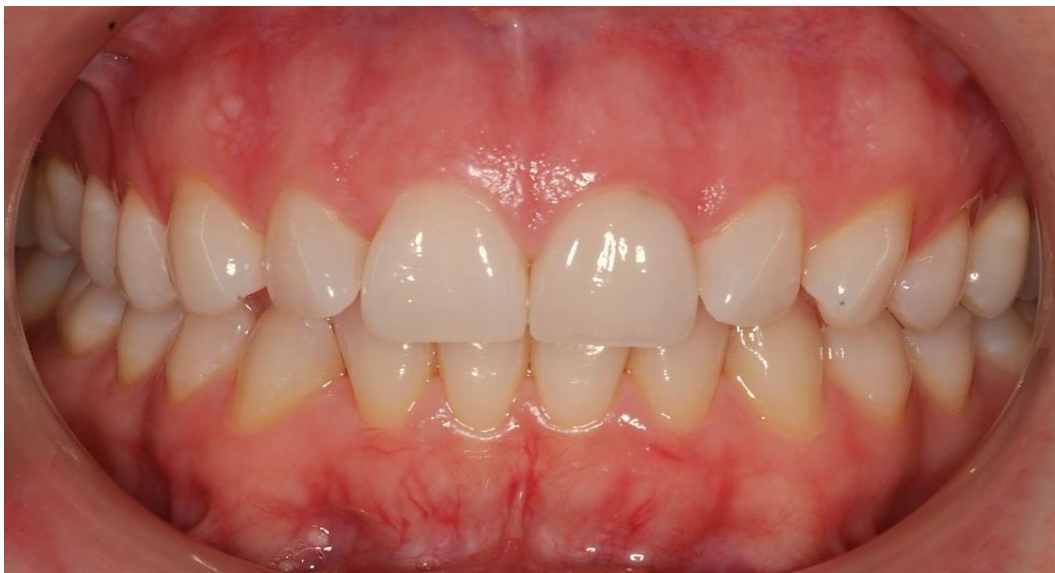## ☒ Consistency

The gingiva is firm and resilient and, with the exception of the movable free margin, tightly bound to the underlying bone. The collagenous nature of the lamina propria and its contiguity with the mucoperiosteum of the alveolar bone determine the firmness of the attached gingiva. The gingival fibers contribute to the firmness of the gingival margin.

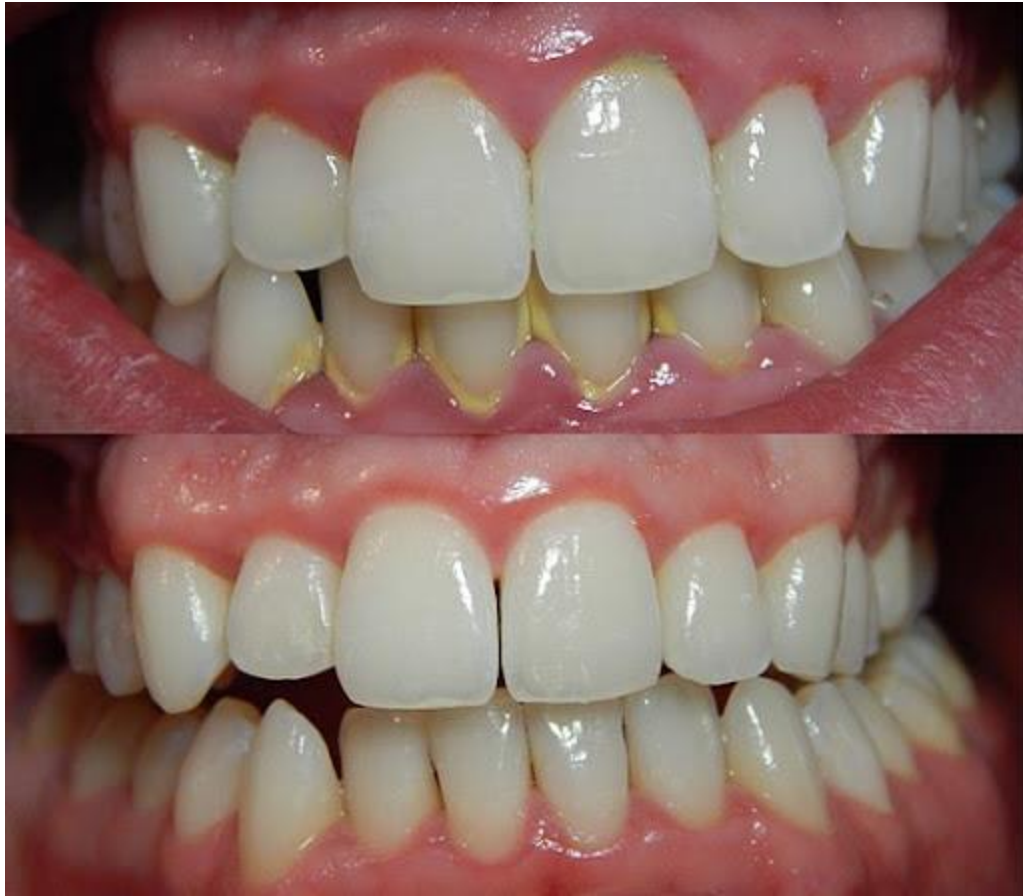In inflamed gingiva, the consistency may be **soft and spongy** because of the vascular stagnation and decrease in the amount of gingival collagen fibers or **extremely firm** because of excessive formation of collagen fibers (fibrosis), this is in case of chronic inflammation.

### ☒ Surface Texture

The gingiva presents a textured surface similar to that of an orange peel and is referred to as stippled. Stippling is **best viewed** by drying the gingiva. The attached gingiva is stippled; the marginal gingiva is not. The central portion of the interdental papillae is usually stippled, but the marginal borders are smooth. Stippling is less prominent on lingual than facial surfaces and may be absent in some persons. Stippling varies with age. It is absent during infancy, it appears in some children at about 5 years of age, it increases until adulthood, and it frequently begins to disappear during old age. The degree of keratinization and the prominence of stippling appear to be related.



**Fig. Clinical health gingival tissue.**



**Fig. Periodontitis & gingivitis features.**

Table 1.1: Differences between alveolar mucosa and attached gingiva		
	<i>Alveolar mucosa</i>	<i>Attached gingiva</i>
Color	Red	Pink
Surface texture	Smooth and shiny	Stippled
Epithelium	Thinner Nonkeratinized Rete pegs absent	Thicker Parakeratinized Rete pegs present
Connective tissue	More loosely arranged More blood vessels	Not so loosely arranged Moderate blood vessels

## **Periodontal ligament (PDL)**

The periodontal ligament is the soft, richly vascular and cellular connective tissue which surrounds the roots of the teeth and joins the root cementum with the socket wall. The periodontal ligament space has the shape of an hourglass and is narrowest at the mid-root level. The width of the periodontal ligament is approximately **0.25 mm**.

**Cellular composition:** cells of PDL are categorized as:

### **1. Synthetic cells**

- A. Osteoblast
- B. Fibroblast ( most prominent cells 65%)
- C. Cementoblasts

### **2. Resorptive cells**

- A. Osteoclasts
- B. Cementoclasts
- C. Fibroblasts

### **3. Progenitor cells**

### **4. Epithelial rest of malassez**

### **5. Connective tissue cells (mast cells and macrophages)**

### **Synthetic cells:-**

**1-Osteoblasts:** Covers the periodontal surface of the alveolar bone. It responsible for the formation of alveolar bone.

**2-Fibroblasts:** The most prominent connective tissue cells (**65%**). The main function of the fibroblasts is the production of several types of fibers (Collagen fibers, Reticulin fibers, Oxytalan fibers and Elastin fibers). Fibroblasts are also instrumental in the synthesis of connective tissue matrix.

**3-Cementoblasts:** Lining the cementum and are responsible for cementum deposition.



## **Resorptive cells:-**

**1-Osteoclasts:** these are the cells that resorb the bone and tend to be large and multinucleated.

**2-Fibroblasts:** Synthesize collagen and also resorb and degrade the old collagen fibers.

**3-Cementoclasts:** Cementum undergoes continual deposition during life. However resorption of cementum occurs in certain circumstances by cementoclasts.

**Progenitor cells:** It differentiate into functional type of connective tissue cells.

**Epithelial rest of Malassez:** Appear as either isolated clusters of cells or interlacing strands, The epithelial rests are considered remnants of the Hertwig root sheath, which disintegrates during root development. Epithelial rests are distributed close to the cementum throughout the periodontal ligament of most teeth; they are most numerous in the apical area and the cervical area. They diminish in number with age by degenerating and disappearing or by undergoing calcification to become cementicles. Although their functional properties are still considered to be unclear, the epithelial rests are reported to contain keratinocyte and growth factors. In addition, epithelial rests proliferate when stimulated, and they participate in the formation of periapical cysts and lateral root cysts. Found close to cementum, when certain pathologic conditions are present, cells of epithelial rest can undergo rapid proliferation and can produce a variety of cysts and tumors of the jaws.

**Mast cells:** Play a role in inflammatory reaction.

**Macrophages:** Capable of phagocytosis.

## **Extracellular components:**

**1. Fibers**            A. Collagen    B. Oxytalan

**2. Ground substances**            A. Proteoglycans    B. Glycoproteins

**Periodontal fibers:** the most important elements of the periodontal ligament are the principal fibers. They are **collagenous** in nature and are arranged in bundles following a **wavy course**. The terminal portion of the principal fibers insert into the cementum and bone are termed **Sharpey's fibers**.

**The principal fibers of the PDL are arranged in five groups: (Fig.9)**

**1- Alveolar crest fibers:** extend obliquely from the cementum just beneath the junctional epithelium to the alveolar crest.

**Function:** retain tooth in socket and resist lateral movement.

**2- Horizontal group:** extends from cementum to the alveolar bone at right angle to the long axis of the tooth.

**Function:** resist lateral tooth movements.

**3- Oblique group:** the largest group extending coronally in an oblique direction from the cementum to the bone.

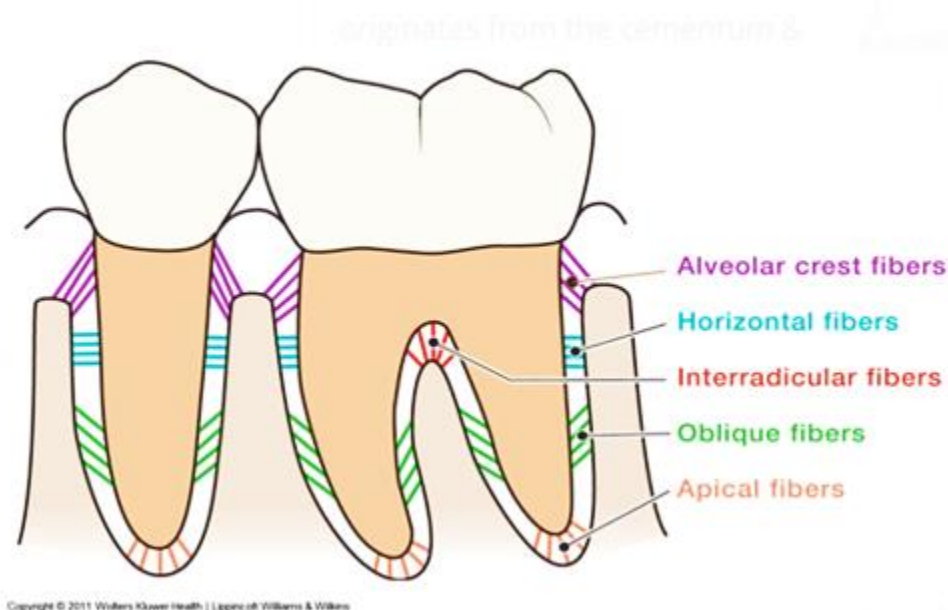
**Function:** tolerate with the effect of vertical masticatory stresses and transform such stresses into the alveolar bone.

**4- Apical group:** they radiate from the cementum of root apex to the bone.

**Function:** it prevents tooth tipping, resists luxation, and protects blood, lymph and nerve supply of the tooth.

**5- Inter-radicular fibers:** Extends from cementum of bifurcation areas into furcal bone.

**Function:** it resists luxation and also tipping and torquing.



**Fig.9:- The principal fibers of the PDL groups.**



**Ground substance:** The ground substance is made up of two major groups of substances:-

1-Glycosaminoglycans: such as hyaluronic acid, proteoglycans.

2- Glycoproteins: such as fibronectin and laminin

It also has high water content (**70%**).

### **Development of principal fibers of PDL:-**

**It will be as follows:**

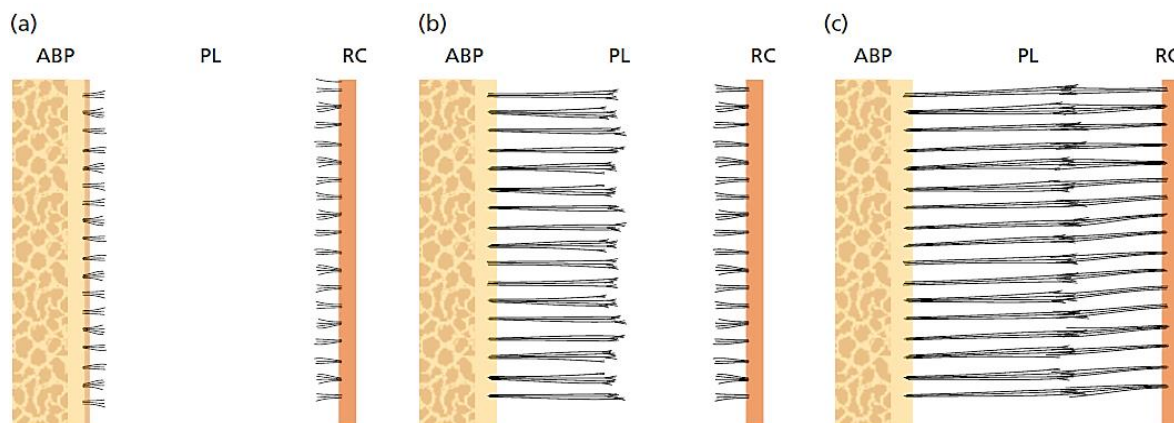
**1-**Small, fine brush like fibrils are detected arising from the root cementum (RC) and projecting into the PDL space.

**2-**Small fibers are seen on the surface of the alveolar bone proper (ABP) but only in thin, small numbers.

**3-**The number and thickness of fibers originating from the bone increase and elongate. They radiate towards the mid portion of the periodontal ligament space.

**4-**The fibers originating from the cementum also increase in length and thickness and fuses with the fibers originating from the alveolar bone in the periodontal ligament space.

**5-**Following tooth eruption, the principal fibers become organized in bundles and run continuously from bone to cementum.



**Fig:- The development of the principal fibers of the periodontal ligament. The alveolar bone proper (ABP), the periodontal ligament (PL), and the root cementum (RC).**

## **Structures present in the periodontal ligament connective tissue:-**

**1-Blood vessels:** periodontal ligament is supplied by branches derived from three sources dental, inter-radicular and Interdental arteries.

**2-Lymphatics:** lymphatic vessels follow the path of blood vessels in the periodontal ligament.

**3-Nerve intervention:** periodontal ligament is mainly supplied by dental branches of the alveolar nerve. The periodontal ligament has mechanoreceptors providing sense of touch, pressure, pain and proprioception during mastication.

**4-Cementicles:** calcified masses adherent to or detached from the root surface.

### **Functions of the PDL:**

1. Physical function
2. Formative and remodeling
3. Nutritional and sensory function

#### **Physical function**

1. Provision of a soft-tissue “casing” to protect the vessels and nerves from injury by mechanical forces
2. Transmission of occlusal forces to the bone
3. Attachment of the teeth to the bone
4. Maintenance of the gingival tissues in their proper relationship to the teeth
5. Resistance to the impact of occlusal forces (**shock absorption**).

#### **Resistance to Impact of Occlusal Forces (Shock Absorption)**

Two theories pertaining to the mechanism of tooth support have been considered: the **tensional theory** and the **viscoelastic system theory**.

The **tensional theory** of tooth support states that the principal fibers of the periodontal ligament are the major factor in supporting the tooth and transmitting forces to the bone. When a force is applied to the crown, the principal fibers first unfold and straighten, and they then transmit forces to the alveolar bone, thereby

causing an elastic deformation of the bony socket. Finally, when the alveolar bone has reached its limit, the load is transmitted to the basal bone.

Many investigators find this **theory insufficient** to explain available experimental evidence.

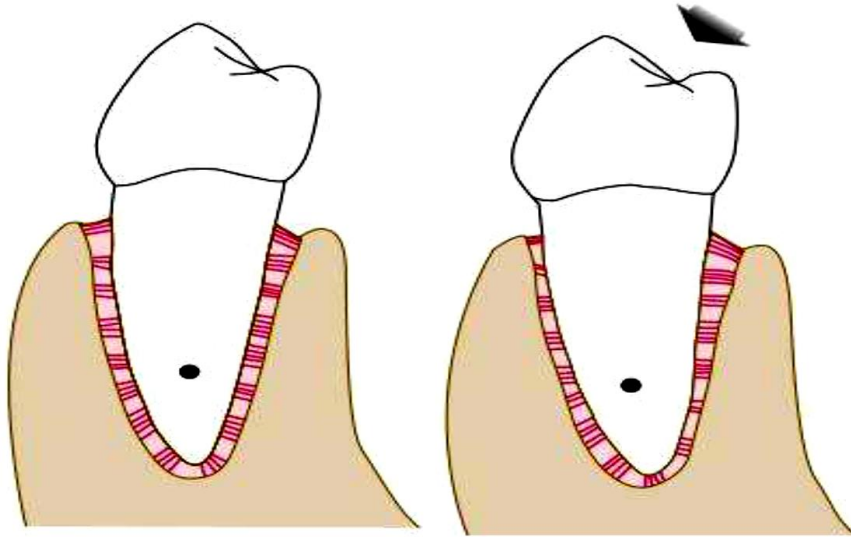
The **viscoelastic system theory** states that the displacement of the tooth is largely controlled by fluid movements, with fibers having only a secondary role. When forces are transmitted to the tooth, the extracellular fluid passes from the periodontal ligament into the marrow spaces of the bone through the foramina in the cribriform plate. These perforations of the cribriform plate link the periodontal ligament with the cancellous portion of the alveolar bone; they are more abundant in the cervical third than in the middle and apical thirds. After the depletion of tissue fluids, the fiber bundles loose and tighten. This leads to a blood vessel stenosis. Arterial back pressure causes ballooning of the vessels and passage of the blood ultrafiltrates into the tissues, thereby replenishing the tissue fluids.

### **Transmission of Occlusal Forces to Bone**

The arrangement of the principal fibers is similar to that of a suspension bridge. When an **axial force** is applied to a tooth, a tendency toward a displacement of the root into the alveolus occurs. The oblique fibers alter their wavy, untensed pattern, assume their full length, and sustain the major part of the axial force.

When a **horizontal or tipping force** is applied, two phases of tooth movement occur. The first is within the confines of the periodontal ligament, and the second produces a displacement of the facial and lingual bony plates. The tooth rotates about an axis that may change as the force is increased. The apical portion of the root moves in a direction that is **opposite** to the coronal portion.

In **areas of tension**, the principal fiber bundles are stretched rather than wavy. In **areas of pressure**, the fibers are compressed, the tooth is displaced, and a corresponding distortion of bone exists in the direction of root movement. In **single-rooted teeth**, the axis of rotation is located in the area between the apical third and the middle third of the root. In **multi-rooted teeth**, the axis of rotation is located in the bone between the roots. In compliance with the physiologic mesial migration of the teeth, the periodontal ligament is thinner on the mesial root surface than on the distal surface.



**Fig.:- Left, Diagram of a mandibular premolar in a resting state. Right, When a force is exerted on the tooth—in this case, in faciolingual direction (arrow)—the tooth rotates around the fulcrum or axis of rotation (black circle on root). The periodontal ligament is compressed in areas of pressure and distended in areas of tension.**

### **Formative and Remodeling function.**

Cells of the periodontal ligament have the capacity to control the synthesis and resorption of the cementum, ligament and alveolar bone. Periodontal ligament undergoes constant remodeling; old cells and fibers are broken down and replaced by new ones.

**Nutritive functions :-** Since PDL has a rich vascular supply, it provides nutrition to the cementum, bone, and gingiva.

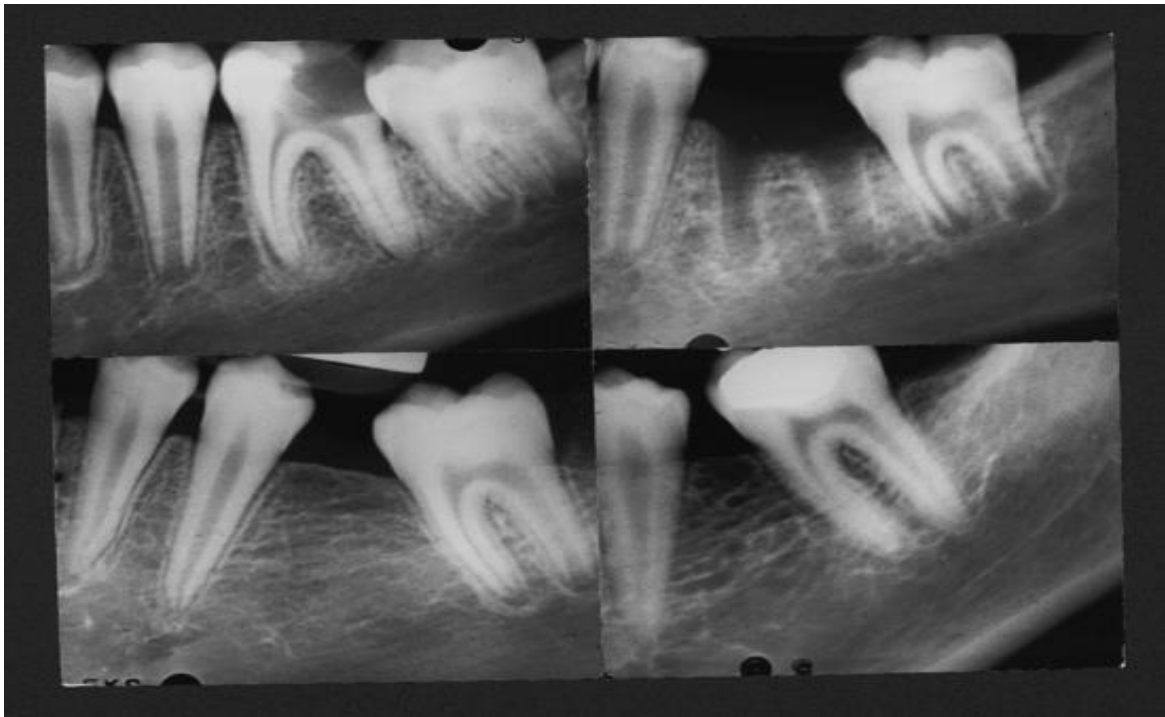
### **Sensory functions**

The PDL is supplied with sensory nerve fibers which transmit sensation of touch, pressure and pain to higher centers.

**Clinical consideration:**

The width of PDL space **varies** with age, location of tooth, degree of stress to which the tooth was subjected. In compliance with the physiologic mesial migration of the teeth the PDL is **thinner** on the mesial root surface than on the distal surface.

A tooth in hyperfunction may have a wider PDL space and a tooth in hypofunction may have a narrow PDL space. The width of PDL space is about **0.25mm** in normal functions. It is **widest** at the cervical and apical portions of the root and **narrowest** at the middle.



**Fig.:- Physiologic mesial migration.**