

# Anatomy Of The Skull

Lec. 2

Dr.Farqaad Salih

# 1- The skeleton of the head consist

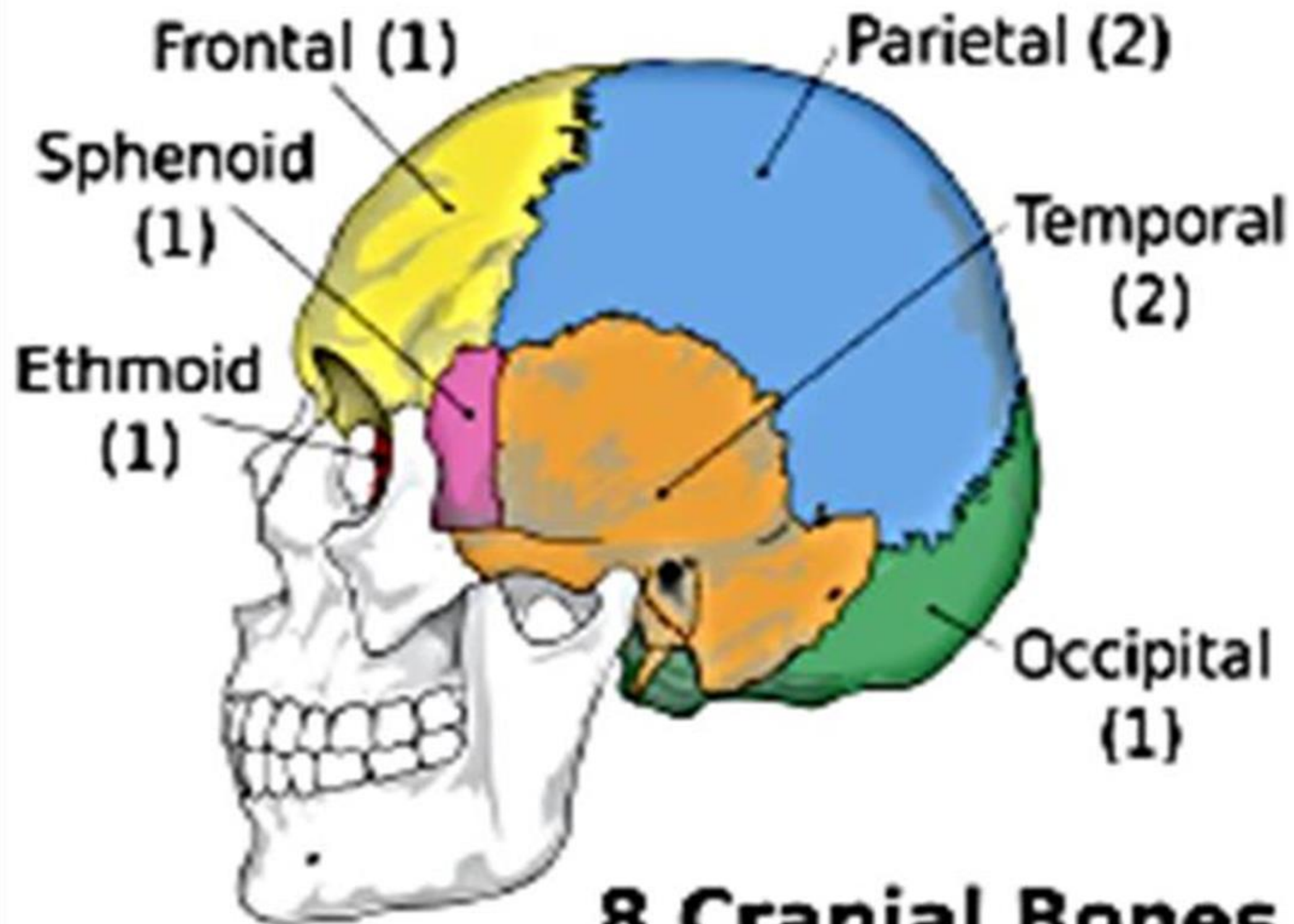
of the skull that consists of number of bones that attached to each other without movement except the lower jaw.

The area at which the bones joined with each other called sutures. The bones of the head can be divided **into two essential parts:**

1- Cranium.

2- The skeleton of face.

**Cranium:** is the large bony box which encloses the brain inside, it has a base and vault قبة ( it has arched shape forms the roof of the skull ).



**8 Cranial Bones**

## It composed of 8 bones (cranial bones):

**Frontal bone:** الجبهي is one bone in anterior part of the cranium.

**Parietal bones:** الجداري are two bones in upper sides of the cranium.

**Temporal bones:** الصدغي are two bones in lower sides of the cranium (ear region).

**Occipital bone:** القذالي is one bone in the posterior part of cranium.

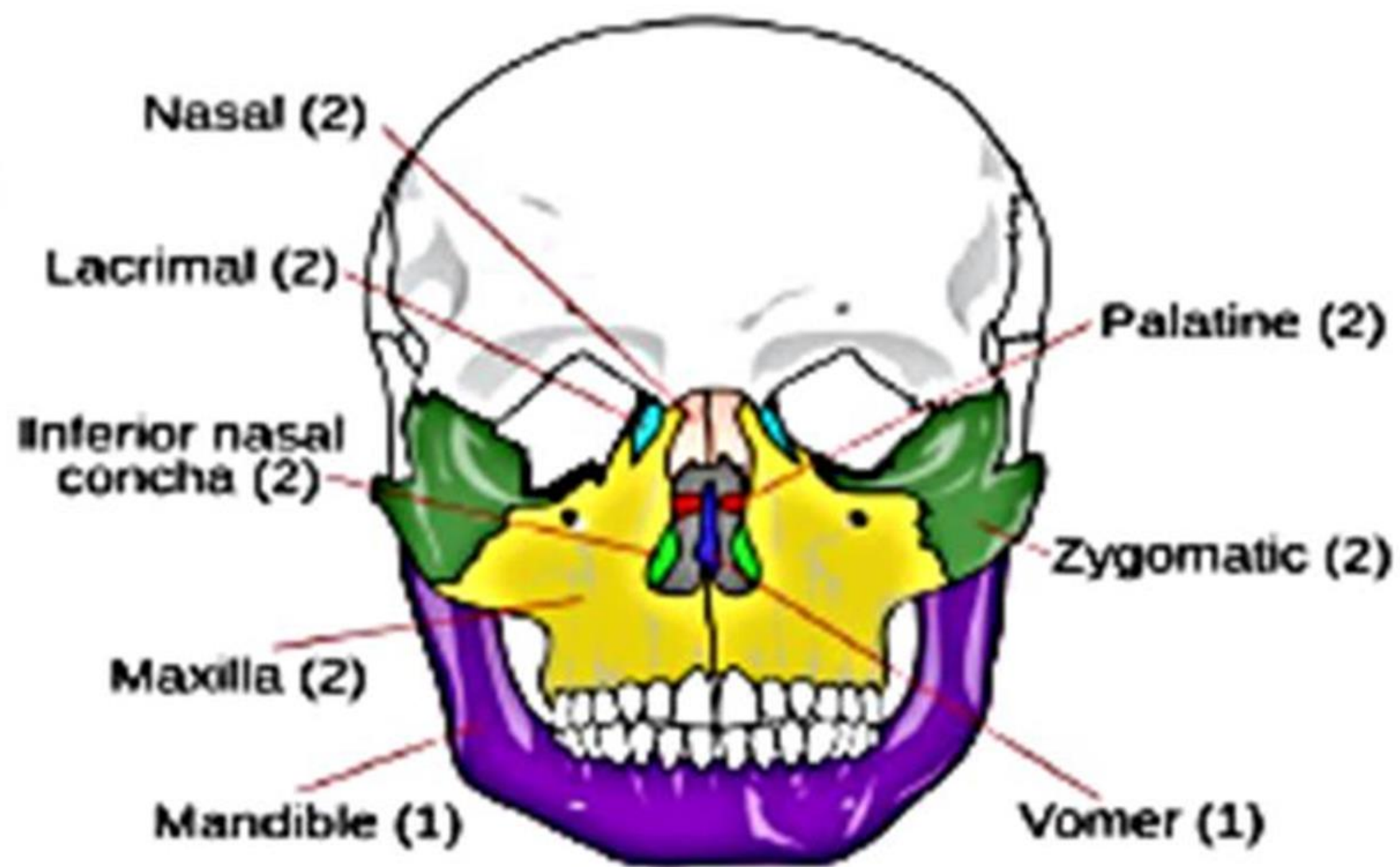
**Ethmoid bone:** العظمي is one bone lies in the middle anterior part of the cranium.

**Sphenoid bone:** الوتدي is one bone lies in middle.

## 2. The skeleton of face:

It composed of 14 bones (facial bones) as following:

- ▶ Two Maxillary bones (maxilla). الفك العلوي
- ▶ Two zygomatic bones. الوجنتان
- ▶ Two Lacrimal bones. الدمعي
- ▶ Two palatine bones. الحنطي
- ▶ Two inferior nasal conchae. المحارة
- ▶ One vomer bone. الحاجزي
- ▶ One mandibular bone ( mandible). الفك السفلي



## 14 Facial Bones



## Superior view of the skull:

If we see the skull from the above we have the vault which is form the upper part of cranium there is 4 bones from the anterior to the posterior :

- 1- Frontal bone (in front).
- 2- Two parietal bones (right and left each sides).
- 3- Occipital bones (behind).

These bones articulated by 3 sutures are:

1- **Coronal suture:** الدرز التاجي this suture situated between the parietal bones and frontal bone.

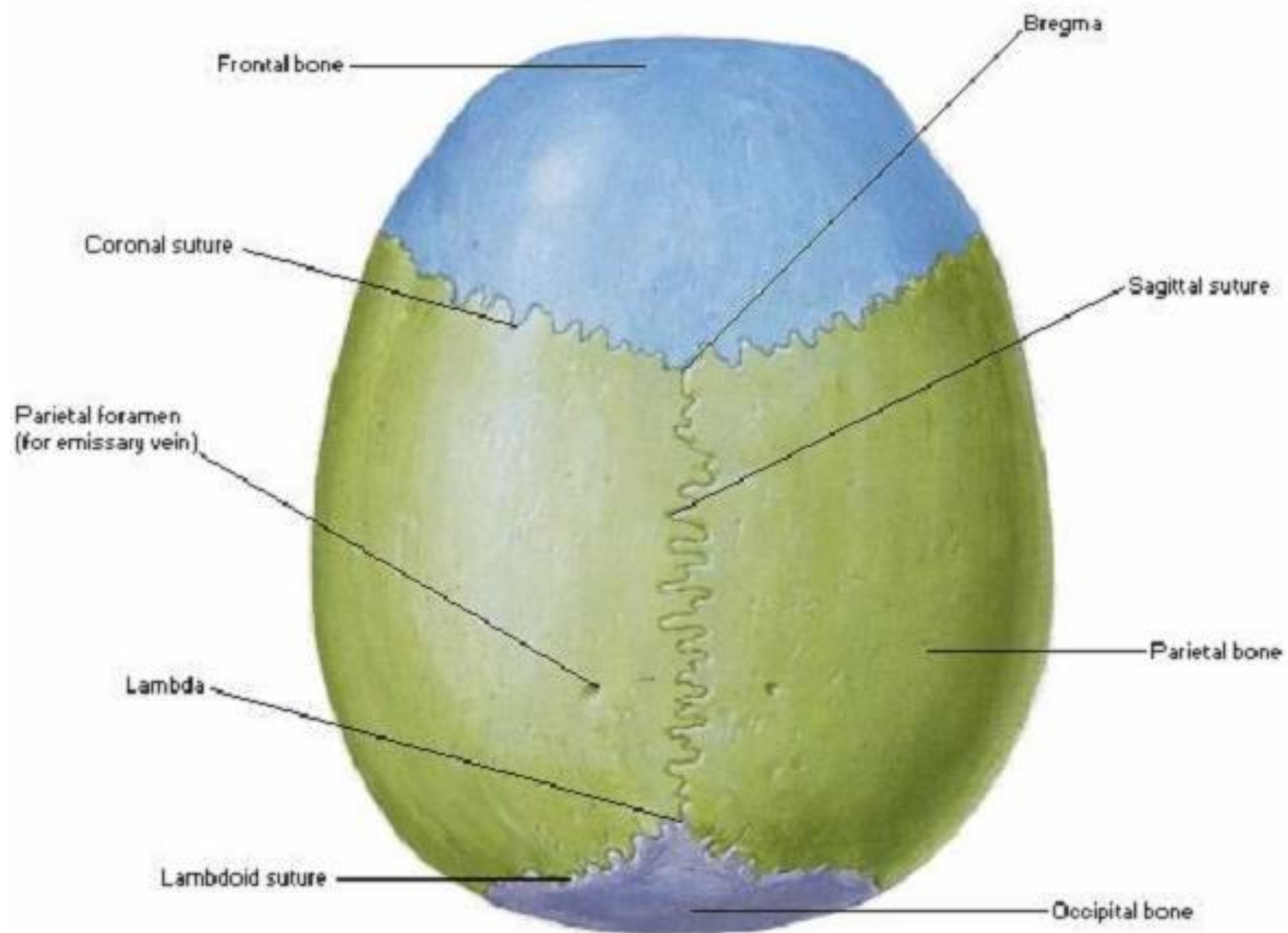
2- **Sagittal suture:** السهمي this suture situated between the two parietal bones.

3- **Parieto-occipital suture (Lambdoid suture):** الجدرائي القذالي

this suture situated between the parietal bones and occipital bone.



## Superior View



## Frontal view of the skull (anterior view):

If we see the skull from the anterior we see facial bones from the upper to the lower:

- 1- Frontal bone: form the forehead.
- 2- Two nasal bones with nasal cavity in the middle.
- 3- Lacrimal bones.
- 4- Zygomatic bones.
- 5- Maxillary bones: formed the upper jaw that carries the upper teeth.
- 6- Mandibular bone: formed the lower jaw that carries the lower teeth.
- 7- Part of the parietal bone. الجداري
- 8- Part of temporal bone. الصدغي

## ► Lateral view of the skull:

1. Squamous حشفي part of the temporal bone: in the middle.
2. Facial bones: anteriorly.
3. Parietal bone: superiorly.
4. Occipital bone: posteriorly.
5. Zygomatic arch: in the middle.
6. External auditory meatus.
7. Mastoid process. النتوء الخشائي.
8. Styloid process. الابري.

## ► Posterior view of the skull:

1. Large part of the occipital bone. القذالي.
2. Parietal bones in the upper lateral part.
3. External occipital protuberance. نتوء.
4. lambdoid suture.

