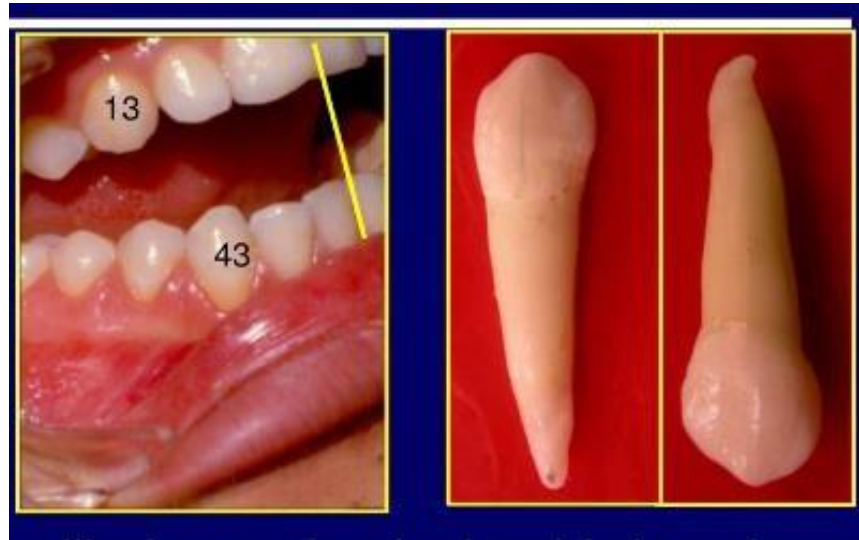

Mandibular canine

- ❖ The mandibular canines are similar to maxillary canines but **narrower** mesiodistally and labiolingually.
- ❖ The crown height of the mandibular canine is slightly longer than that of the maxillary canine



Labial Aspect

The essential differences between **mandibular** and **maxillary** canines viewed from the **labial aspect** are as follows:

MAXILLARY CANINE	MANDIBULAR CANINE
Crown wider mesiodistally	Crown narrower mesiodistally
Cusp angle is sharper, more acute	Cusp angle more blunt
Mesial cusp ridge is shorter than distal	Mesial cusp ridge much shorter than distal
	Mesial cusp ridge almost horizontal
Mesial, distal proximal contacts more cervical	Mesial, distal proximal contacts more incisal
More pronounced labial ridge	Less pronounced labial ridge
More pointed root tip	More blunt root tip

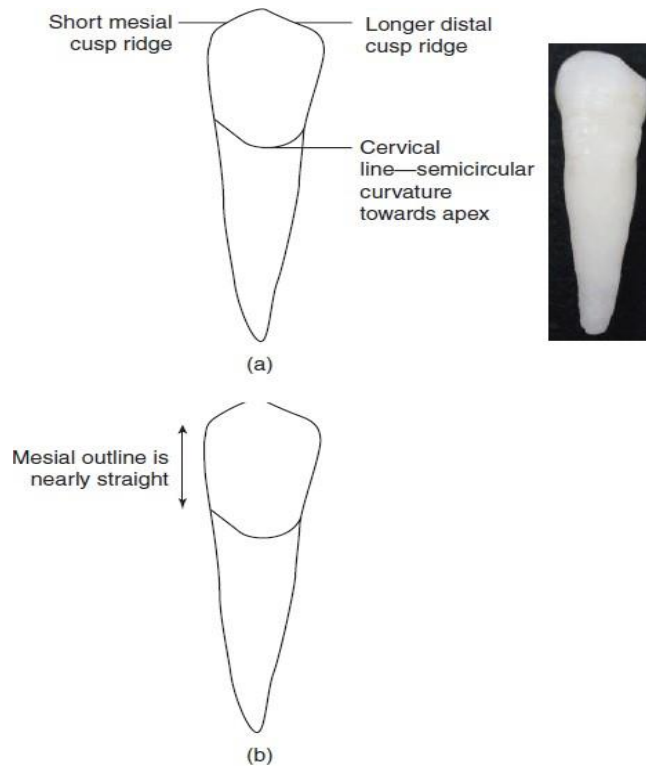


Figure 15.10 Labial aspect of the mandibular canine.

Lingual Aspect

In comparing the lingual aspect of the mandibular canine with that of the maxillary canine, the following differences are noted:

MAXILLARY CANINE	MANDIBULAR CANINE
More prominent anatomy on lingual:	Smoother lingual surface:
Lingual marginal ridges pronounced	Lingual marginal ridges less pronounced
Prominent lingual ridge and fossae	Less prominent lingual ridge and fossae
Cingulum centered	Cingulum centered or to distal

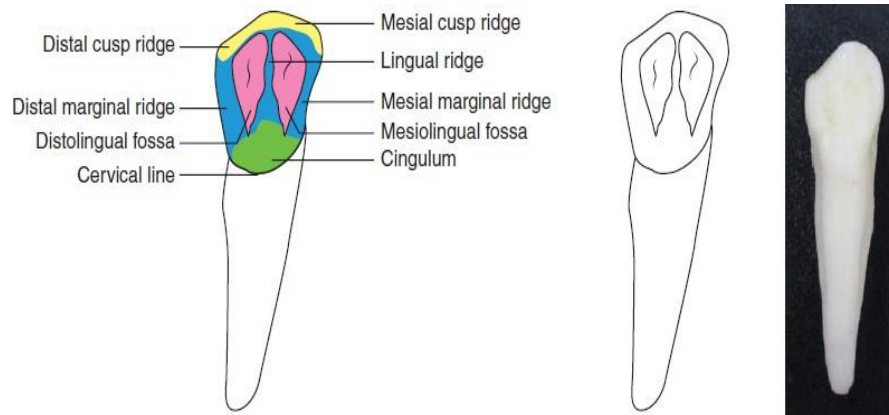


Figure 15.11 Lingual aspect of the mandibular canine.

Mesial Aspect:

- The lingual outline of the crown is curved in the same manner as that of the maxillary canine.
- The cingulum is not as pronounced, and the incisal portion of the crown is thinner labiolingually, which allows the cusp to appear more pointed and the cusp ridge to appear more slender.
- The tip of the cusp is more nearly centered over the root.
- The cervical line curves more toward the incisal portion than does the cervical line on the maxillary canine.
- The roots of the two teeth are quite similar from the mesial aspect, except for a more pointed root tip on the mandibular canine.
- The developmental depression mesially on the root of the mandibular canine is more pronounced and sometimes quite deep.



Figure 15.12 Mesial aspect of the mandibular canine.

Distal Aspect

Little difference from the distal aspect can be seen between mandibular and maxillary canines except for those features mentioned under the mesial aspect that are common to both.

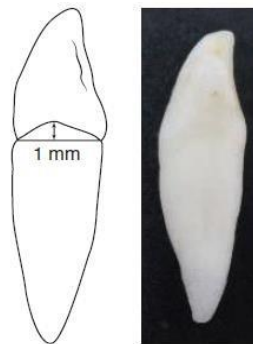


Figure 15.13 Distal aspect of the mandibular canine.

Incisal Aspect

The outlines of the crowns of mandibular and maxillary canines from the incisal aspect are often similar. The main differences to be noted are as follows:

1. The mesiodistal dimension of the mandibular canine is less than the labiolingual dimension. A similarity is evident in this, but the outlines of the mesial surface are less curved.
2. The cusp tip and mesial cusp ridge are more likely to be inclined in a lingual direction in the mandibular canine, with the distal cusp ridge and the contact area extension distinctly so.
3. Note that the cusp ridges of the maxillary canine with the contact area extensions are more nearly in a straight line mesiodistally from the incisal aspect.

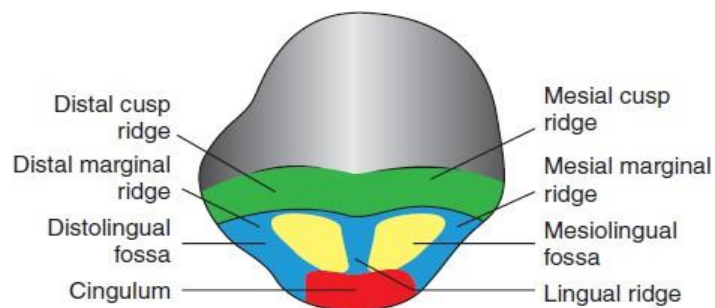


Figure 15.14 Incisal aspect of the mandibular canine.

THANK YOU