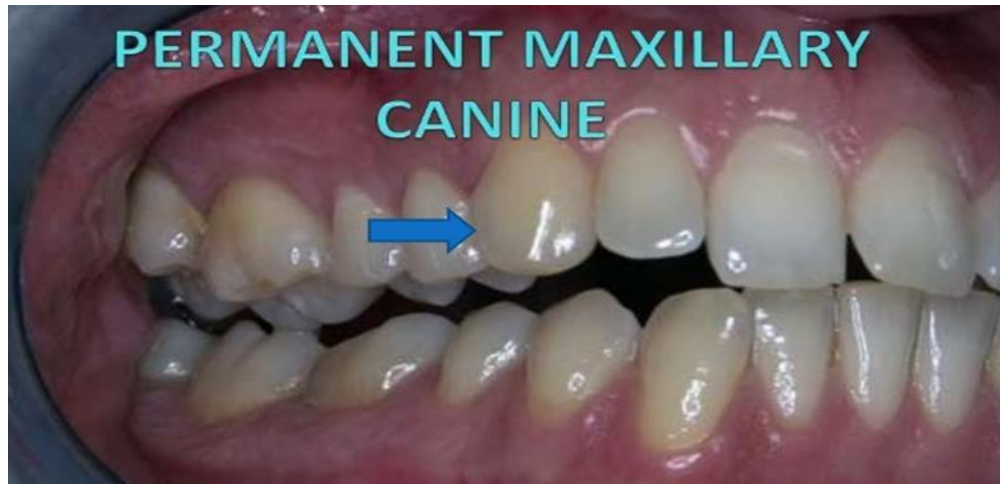

Maxillary canine

It is located at the **corner** of the mouth and they have the **longest root** in the dental arch.



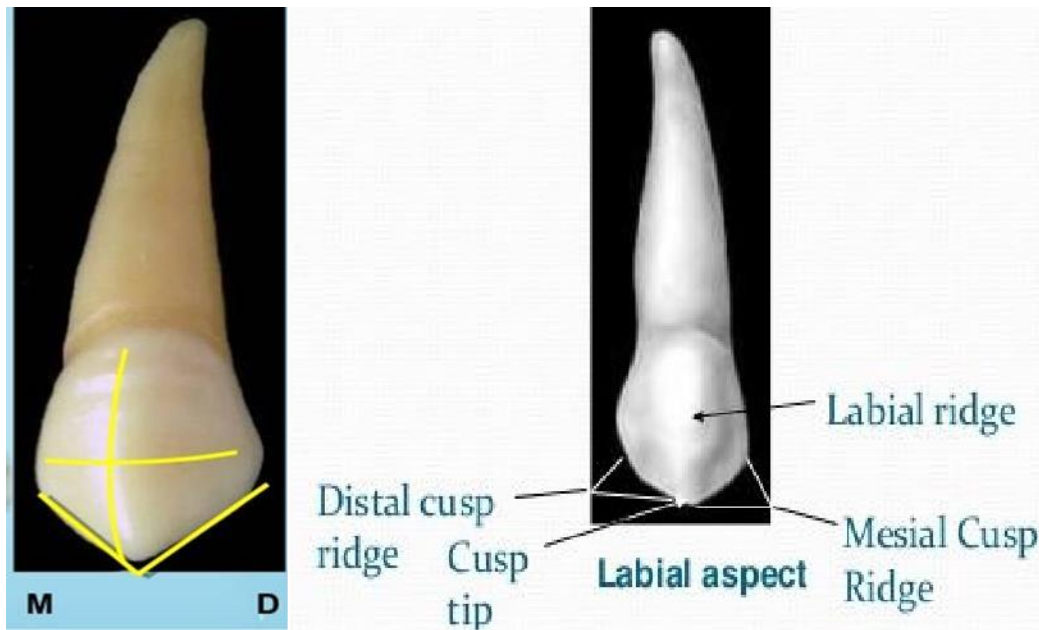
Importance of canine:

1. It gives support to the facial muscles.
2. Their stability in the alveolar process of the jaw makes it very important as an assistant in stabilizing, it is the most prominent tooth in the mouth.

In function, it gives support to the incisor and premolar. It erupts at **12-13** years.

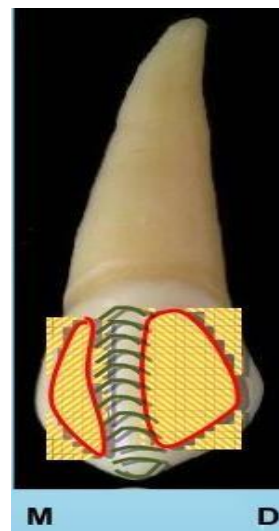
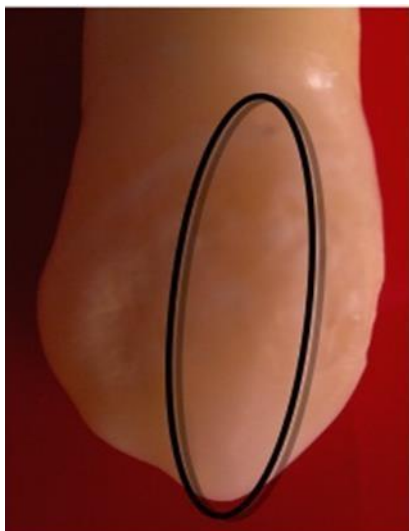
Labial aspect:

1. The crown is narrower mesio–distally than the central incisor
2. The cervical line is convex toward the root.
3. The contact area mesially **at the junction of the middle and incisal third** while the distal contact area is usually at the center of the middle third of the crown .



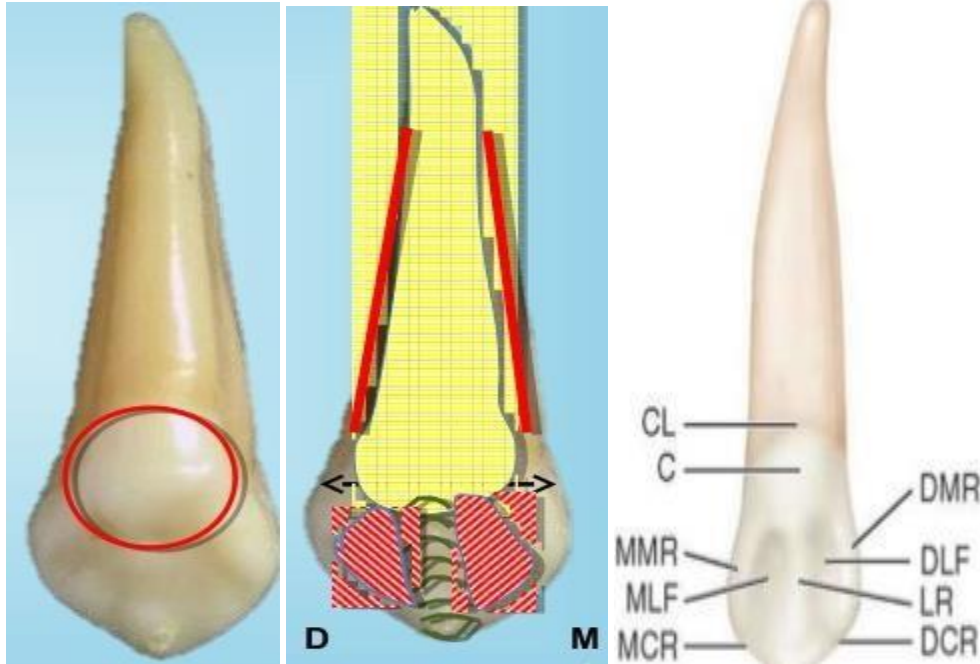
4. It is convex from mesial and distal sides with slight convexity at the area between the cervical line and distal contact point.
5. The tip of the cusp is on the line with the center of the root.
This cusp has two slopes **mesial slop shorter than the distal slop**.
6. The labial aspect is smooth with depression mesially and distally, dividing the aspect into the three lobes the middle lobe is much greater developed than the other, which produces **a labial ridge**.

The root is conical with a blunt apex, sometimes it is curved mesially or distally.



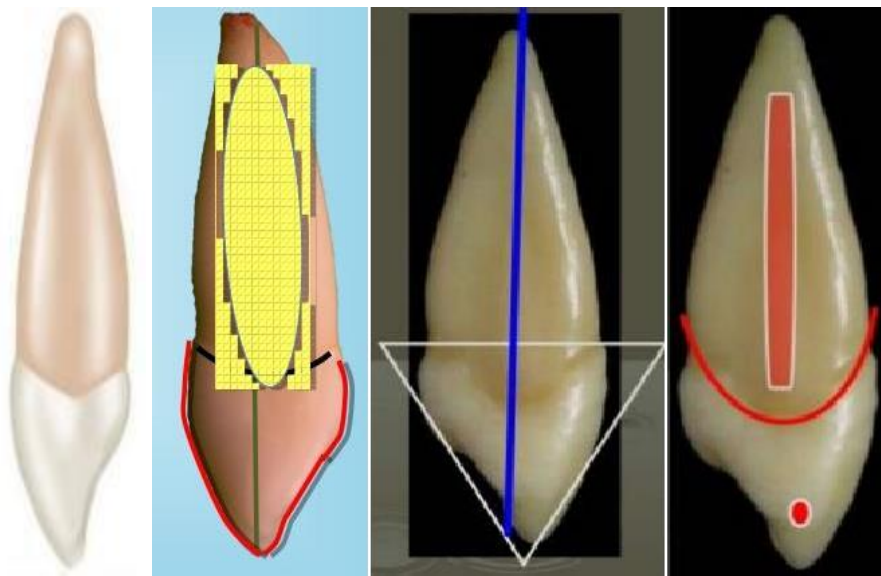
Lingual aspect:

1. Crown and root tapered lingually
2. The cervical line is more curved than labially
3. Well-developed cingulum.
4. There is a lingual ridge extending below the cingulum.
5. There are two fossae mesial and distal fossa between the two marginal ridge
6. There is a mesial and distal developmental depression on the most of root length.



Mesial aspect

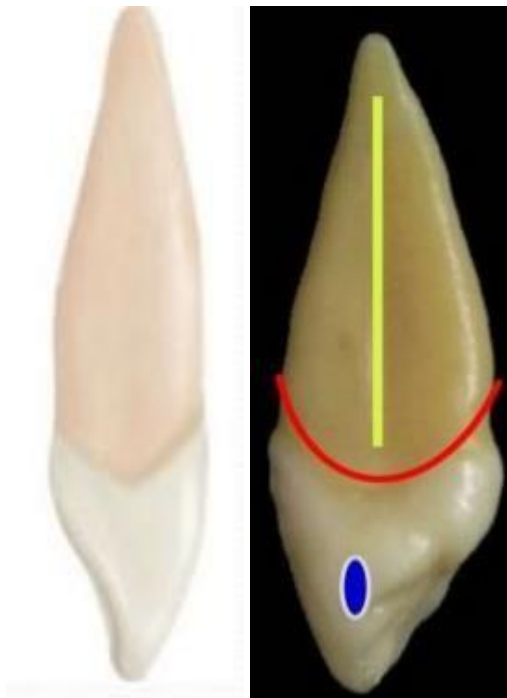
1. The labial and lingual outlines are convex and this convexity is located within the curvature of the cervical line.
2. From the labial aspect, it has slight convexity at the cervical third to the tip of the cusp.
3. From the lingual aspect represent the convexity at the cervical third (cingulum) then be small concavity at the middle third then be straight at the incisal third.
4. The cervical line curved to word the cusp.
5. The root is blunt and conical in shape.



Distal aspect:

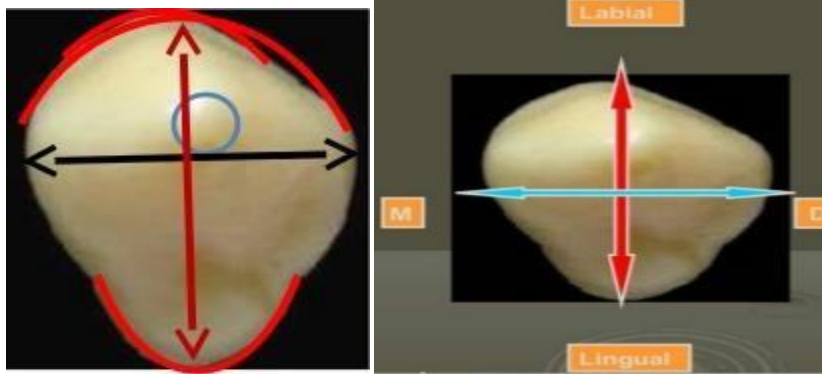
Similar to the mesial aspect with some differences:

1. The cervical line is less curved.
2. Distal marginal ridges are more **irregular** than the mesial marginal ridge.
3. Deeper concavity above the contact point.



Incisal aspect

1. The labio-lingual dimension is greater than mesio- distal dimension.
2. The tip of the cusp is labial to the center of the crown (labio-lingually) and mesial to the center (mesio-distally).
3. The ridge of the middle lob is very prominent.
4. Cingulum is more prominent lingually.



Differences between maxillary incisor and canine:

1. Canine has single pointed cusp; the central incisor doesn't have a cusp.
2. Canine has distal slope of cusp longer than mesial slope.
3. Canine has convexity at the labial and bulk cingulum at the palatal surface than the central incisor
4. Canine has a longer root with a triangular cross-section.
5. Canine has well-developed grooves at the mesial and distal side of the root.
6. Canine crown narrower mesio-distally and wider labio-lingually than central incisor.
7. Canine has narrower root at lingual surface than central incisor.

THANK YOU