



Pediatric Dentistry

5th Year

Lec. 2

Examination of the Mouth (Continued)

Assistant Professor Aseel Haidar



Assist. Prof. Dr. Aseel Haidar

INTRA ORAL EXAMINATION

The intraoral examination of a pediatric patient should be comprehensive. There is a temptation to look first for obvious carious lesions. Although controlling carious lesions is important, the dentist should first evaluate the condition of the oral soft tissues and the status of the developing occlusion (**Why?**). If the soft tissues and the occlusion are not observed early in the examination, the dentist may become so engrossed in charting carious lesions and in planning for their restoration that other important anomalies in the mouth are overlooked. In addition, any unusual breath odors and abnormal quantity or consistency of saliva should also be noted.






Soft tissue examination

An underlying systemic disease or nutritional deficiency can be indicated through the abnormal appearance of the oral mucosa. It is, therefore, very important to examine carefully the lips, palate and oropharynx, tongue, floor of the mouth, buccal mucosa.





It includes examination of the oral mucosa and examination of periodontal tissues. Complete inspection and palpation of all the oral soft tissues is important to evaluate the condition of the oral soft tissues and the status of developing occlusion. In addition, unusual breath odors or abnormal quantity or consistency of saliva should be noted.

During examination of intraoral soft tissues,

Gingiva should be examined:

-  High maxillary labial frenal attachment may be responsible for abnormal spacing between the central incisors.
-  Redness and swelling of gingiva may be seen associated with gingivitis.
-  Draining fistula on the attached gingiva accompanied by a tooth that is tender, painful and mobile are usually diagnostic of abscessed teeth.
-  Assessment of the oral cleanliness and the presence of plaque and calculus should be done. (*Where you could found this point in the case sheet?*)
-  The presence of profound gingival inflammation in the absence of gross plaque deposits, prematurely exfoliating teeth, or mobile permanent teeth may indicate a serious underlying disease.

Tongue should be examined:

-  The size, shape, color and movement of the tongue should be noted.
-  Dryness of tongue—indicates dehydration.
-  Tongue is coated in febrile state.
-  Abnormal lingual frenum can result in 'tongue tie' or ankyloglossia

Check the salivary flow rate and quality:

It may be thin, normal or viscous.



Altered secretions are seen in systemic conditions such as mumps, Sjogren's syndrome, etc...

Check the tonsils:

Enlarged tonsils with purulent exudates may be the initial sign of streptococcal infection leading to rheumatic fever. When streptococcal throat infection suspected immediate referral of the child to the physician is indicated. Obtaining throat culture while the child is on the dental chair is helpful for the physician.

**Notes:**

1. Soft tissue should be examined for 3C's, change in the color, contour and consistency.

Change in the color:

It may be a change to red (inflammation), blue (hematoma, bruise) or white (electric or thermal burns, candida infection).

Change in the contour: It may be due to either a swelling (abscess, papilloma) or ulcer (aphthous, traumatic).

Change in the consistency: It may be soft (inflammation), firm (mucocele) or hard (bony exostosis).

2. The use of the periodontal screening and recording program (PSR) is often a useful adjunct in children.

3. Halitosis may be due to poor oral hygiene, blood in mouth, dehydration, sinusitis, infection of adenoid tissue, disturbances of alimentary tract, etc.

Hard tissue examination

Evaluation of the overall dentition can be made before the examination of individual teeth. These include variations in number, morphology, color and surface structure. These should be observed under good light and after careful isolation and dryness.

A) Careful evaluation and inspection of individual teeth should be done for:

Teeth number—any missing/extra teeth (supernumerary)



Evidence of carious lesions

The teeth should be cleaned thoroughly before attempting to check for decay. Refer for diagnosis of: caries (active lesion/ arrested), restorations—(intact/ deficient).



Hereditary or acquired anomalies

Visual examination with explorer can detect any morphological defects and incomplete coalescence of enamel at the base of pits and fissure in molar teeth. Tooth structure—record any localized or generalized defect, e.g. fluorosis.



Trauma—note the extent, site or signs of loss of vitality.




Tooth mobility—physiological/pathological.



Discoloration

Difference should be made regarding discoloration, which may be due to extrinsic, or an intrinsic reason. Food stains or tobacco stains cause discoloration on the surface of the tooth. The cause for discoloration in a non-vital tooth is due to intrinsic reasons. Other reasons that cause intrinsic change in the color are enamel hypoplasia, fluorosis, etc.



Identification of carious lesion is important in patients of all ages but it is especially critical in young patients because the lesion may progress rapidly in early childhood caries if not controlled. Elimination of caries, restoring the teeth as needed, can prevent pain and the spread of infection and contribute to the stability of the developing occlusion



Examinations of teeth start in upper right quadrant work around the maxillary arch move down to the lower left and end in the lower right.

B) Examination of occlusion

Inspect occlusion and note any dental or skeletal irregularities. Dental or skeletal abnormalities may undergo considerable changing during childhood and early adolescence. This dynamic developmental process occur in all three planes of space and with periodic evaluation, the dentist can intercept and favorably influence undesirable changes. Early recognition of malocclusion will help to formulate a treatment plan in a very young age.

Monitoring of patient facial profile and symmetry, molar, canine, and anterior segment relationship, dental midlines, overjet and overbite, physiological spacing, presence of crowding/spacing; severe skeletal abnormalities, arch length to tooth mass comparison should be routinely included, diagnostic casts, cephalometric analysis indicated early in mixed dentition and sometime in the primary dentition.

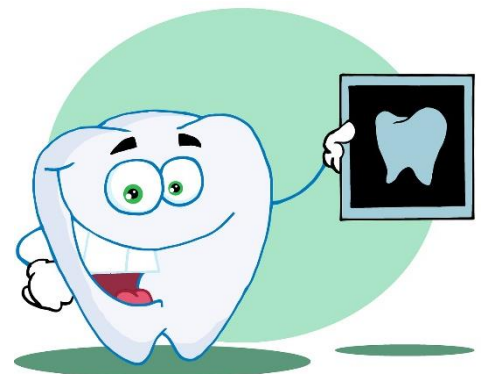
**** Breathing pattern of the child can be nasal, oral or combination. *(If you detect that the child you examined is a mouth breather, What is your duty?)***

Radiological examination

Radiograph should be taken before comprehensive oral health care plan can be developed and subsequent radiographs are required periodically to detect incipient caries or other developing anomalies.

A child should be exposed to dental ionizing radiation **only** after the dentist has determined that radiography is necessary to make an adequate diagnosis for the individual child at the time of the appointment.

Sometimes, obtaining isolated occlusal, periapical or bitewing radiograph is indicated in very young children (even infants) because of trauma, toothache, suspected developmental disturbances, or proximal caries. Carious lesions appear smaller on radiographs than



they actually are. If the pediatric patient can be motivated to adopt a routine of good oral hygiene supported by competent supervision, many of these initial lesions can be arrested.

FINAL DIAGNOSIS

This is the final conclusive answer, which can be reached upon by applying investigative reports to our differential diagnosis options. It is a more confirmed diagnosis analyzing all the available data including the results of investigation.

Treatment priorities

Planning the treatment can be made based on different phases:

- 1) Emergency phase
- 2) Medical/referral phase
- 3) Systemic phase
- 4) Preventive phase
- 5) Corrective phase
- 6) Maintenance and recall

Emergency phase

All the problems that require immediate actions, such as relieving the child from pain, infection, attending due to a trauma, etc. should be done in this stage. Conservative treatment approach at an emergency visit is advantageous because the child is often under stress and of low tolerance level. If possible, delay extraction or extensive pulpal therapy, if the pain can be relieved by some other means.

Medical/referral phase

In this phase, patients with positive medical history should be referred to pediatrician for evaluation and consent. It may also be required to modify the dosage or change a particular drug as per the requirement of the treatment. Sometimes, modification to the type of the treatment is needed according to the underlying systemic condition.

Systemic phase

Any medication given to modify dental treatment is included in this phase, such as premedication for behavior management or antibiotic prophylaxis to a child with congenital cardiac defect.

Preventive phase

This phase is the first phase of treatment. It is aimed at providing preventive therapy to prevent or minimize dental disease. A plaque control program should be done that includes plaque identification and removal, diet counseling, topical fluoride application and child-parent education on home care oral hygiene practice. This phase includes:

- 1) Oral prophylaxis and fluoride treatment
- 2) Pit and fissure sealant application
- 3) Oral hygiene counseling
- 4) Diet counseling
- 5) Orthodontic consultation



Corrective phase

It includes providing treatment or management of the disease process. It includes:

- 1) **Extractions**
- 2) **Restorations**
Restorative therapy : A procedure that is short and simple should be selected first during this initial appointment to allow the development of patient trust and confidence.
- 3) **Minor surgical procedures**
- 4) **Space maintainers**
- 5) **Minor orthodontic corrections**
- 6) **Prosthetic rehabilitation**

****** Orthodontic and prosthodontic care following the completion of the restorative phase of treatment that may be rendered if needed. Although minor oral surgical procedures are accomplished during the restorative phase of treatment using the quadrant approach, complex surgical procedure should be delayed until this phase.



Maintenance and recall

Patients are recalled at regular intervals following the completion of the required treatment for evaluation and necessary follow up. This is done as a preventive measure for early detection of disease and for biannual topical fluoride application. Patients at high risk are maintained at 2-3 months recall and low risk at 6 months recall.

****** No treatment plan is completed until provision is made to provide a recall appointment for evaluation and necessary follow up care

Presentation of treatment plan to parents

The dentist should inform the parents for:

1. The dental need of their child
2. The restorative procedures that required
3. The amount of time required to perform the projected procedures
4. The total cost of the services
5. Preventive measures that are necessary to maintain the completed treatment

Each problem should be discussed with the parents in the following manner:

- 1) Point out the problem-using cast, radiograph or the patient mouth.
- 2) State the probable cause of the problem such as plaque or insufficient arch length.
- 3) State the outcome of the problem such as its effect on function, health or appearance.
- 4) Show the parents how the problem will be resolved.
- 5) Stress the benefit that the patient will receive from the treatment.

