



Department of Anesthesia Techniques

Title of the lec1: ECG

Assist. Prof. Dr. Aqeel H. Al-Jothery

Dr. Sajad A. Al-ghazali

Dr. Amasee Falah

Dr. Noor Kareem

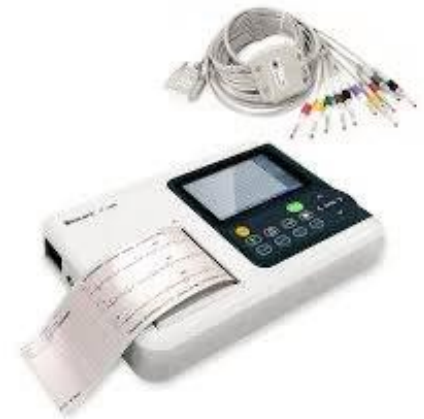

Electrocardiogram (ECG)

تخطيط القلب

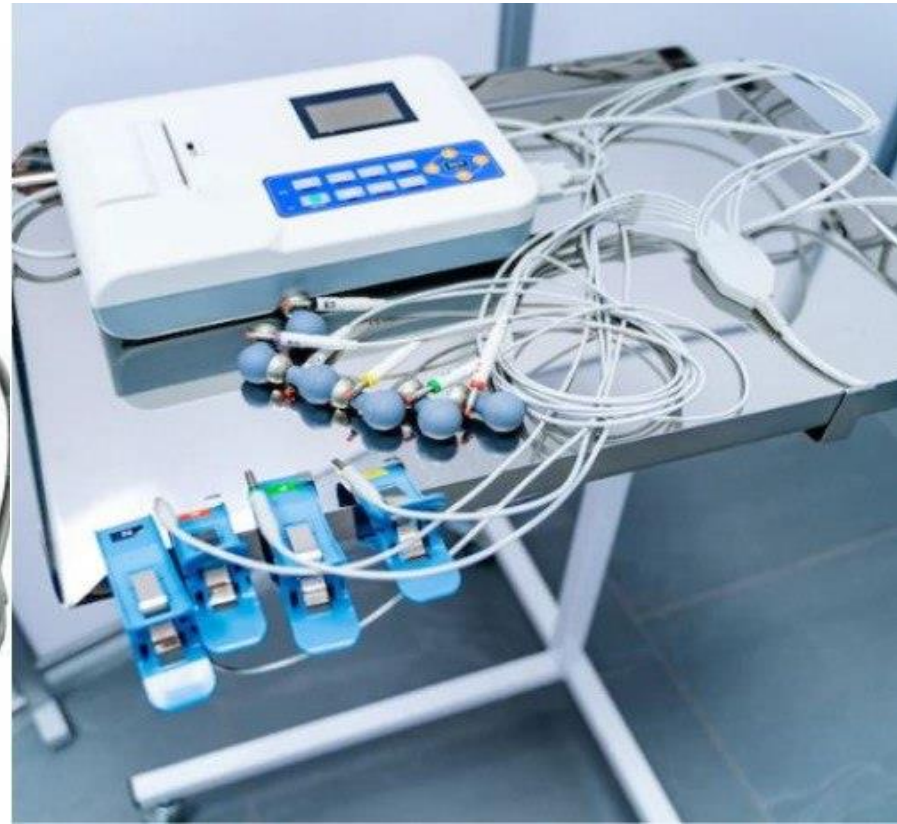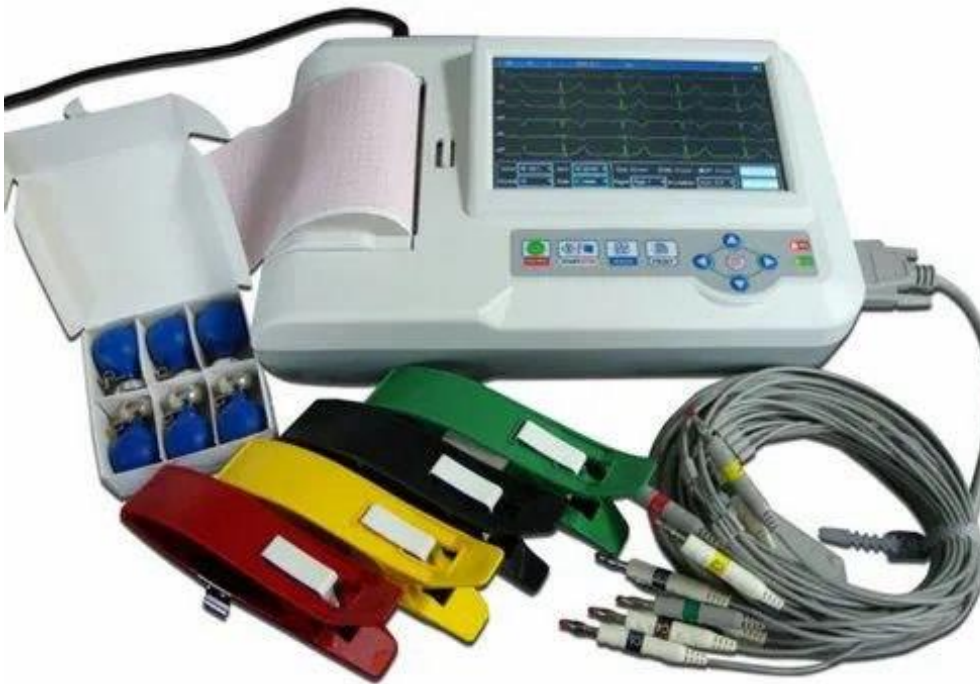Practical Applied physiology

عملي المحاضرة الاولى



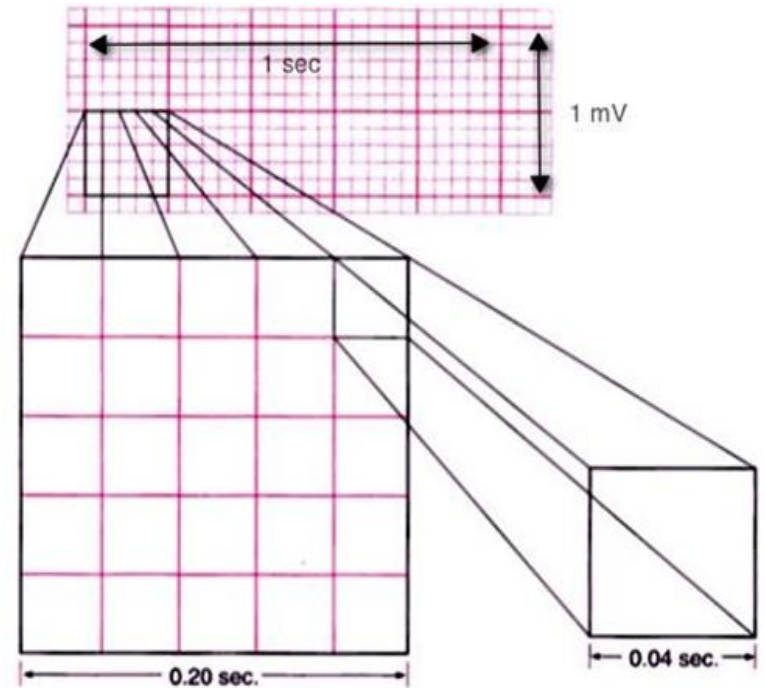
Introduction

- **Electrocardiography** is a process of recording electrical activities of heart muscle at skin surface.
- **Electrocardiograph** the name of the machine
- **Electrocardiogram** the record from this procedure

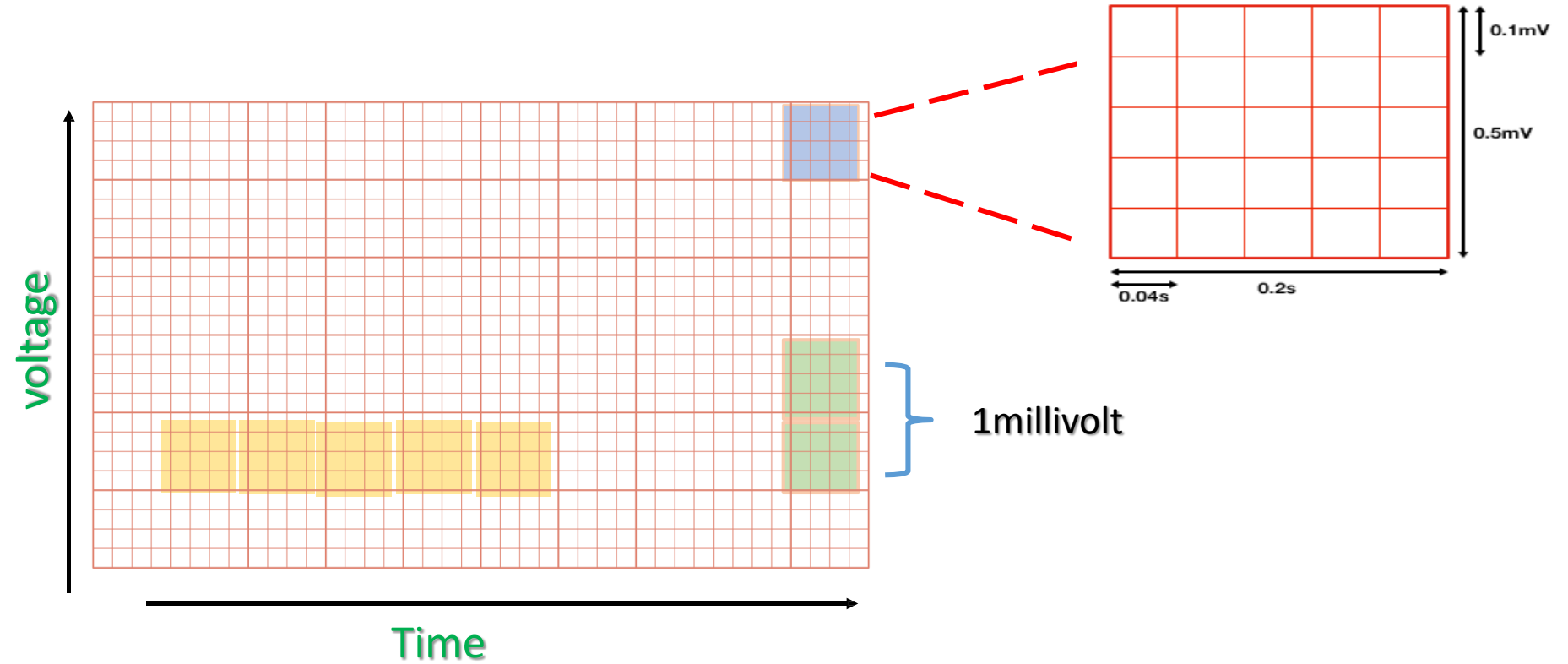


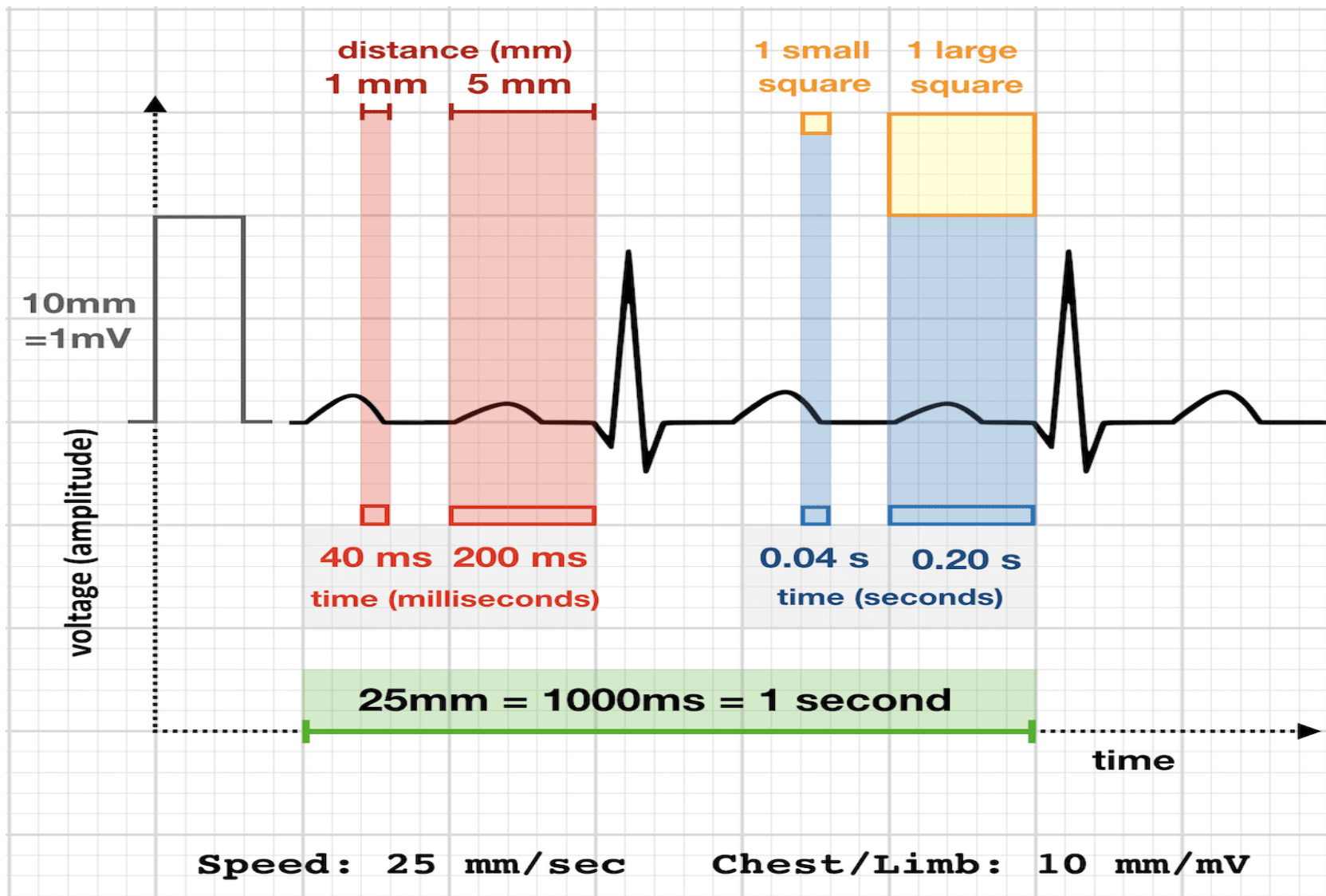
Introduction

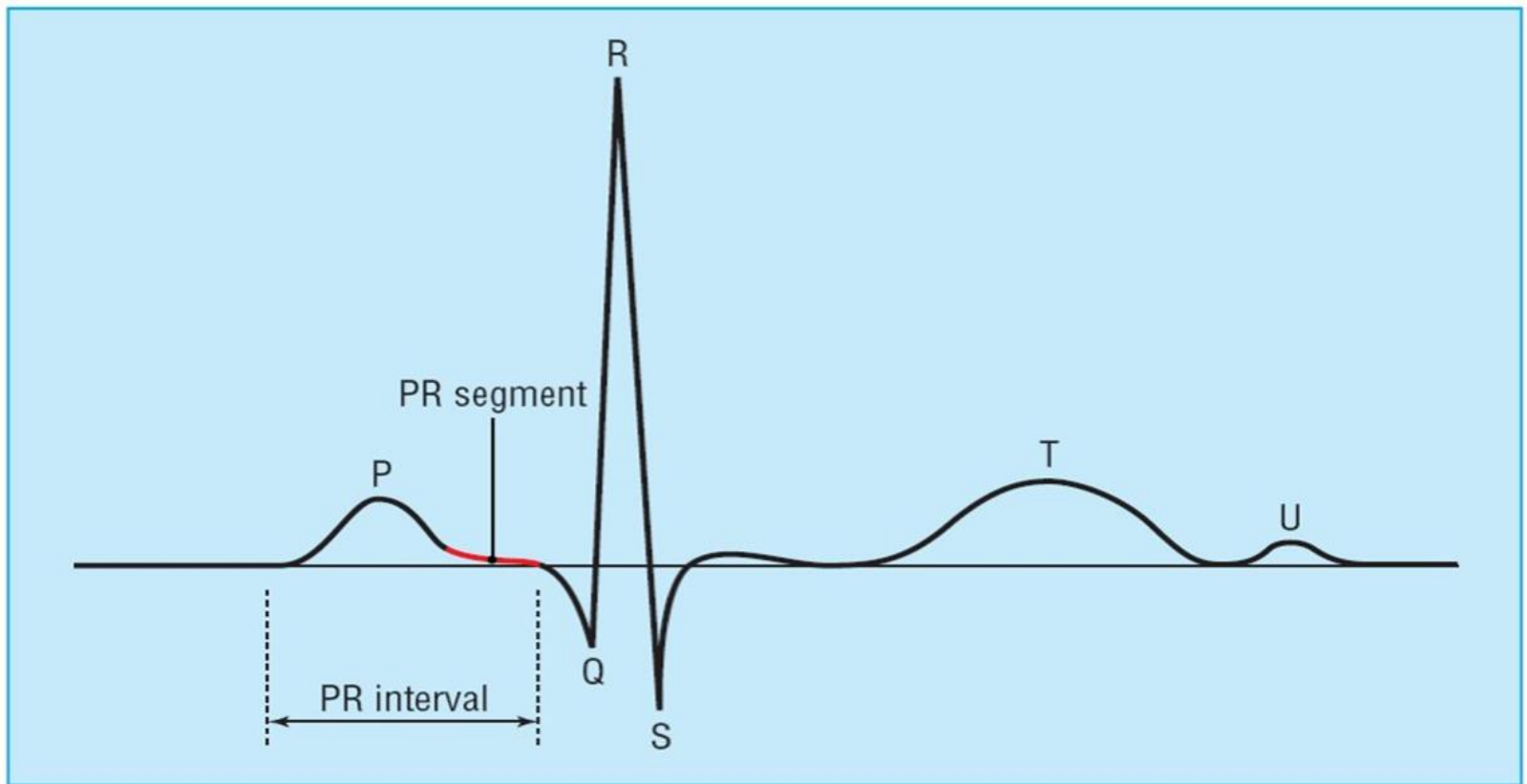
- The horizontal axis of the ECG paper records time,
 - 1 large square = 5 small squares
 - 1 small square = 1 millimeter
 - 5 large squares = 25 millimeters = 1 second
 - 5 millimeters (5 small squares) = 0.20 second
 - 1 small square = 0.04 second.
- The vertical axis records ECG amplitude (voltage).
 - 1 large square = 0.5 mV
 - 2 large square (10 small squares) = 1 mV



ECG paper

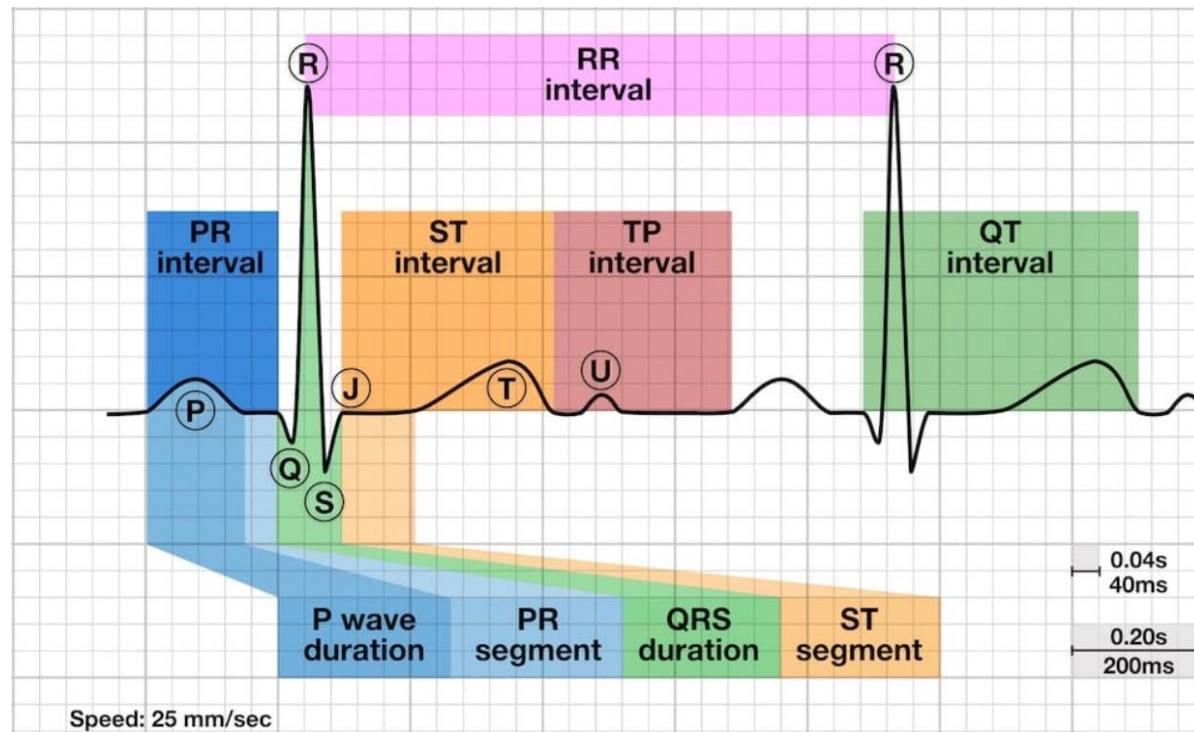




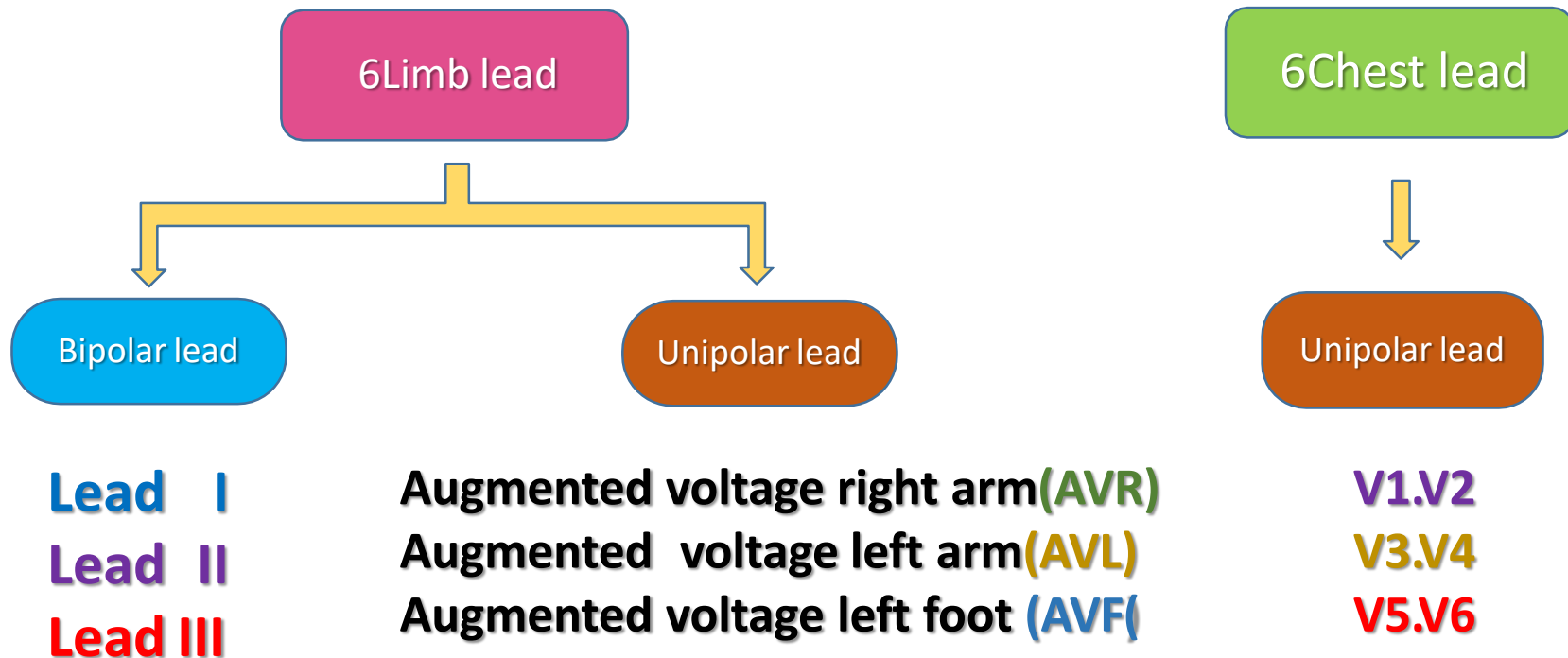


Normal duration of PR interval is 0.12-0.20 s (three to five small squares)

The normal electrocardiogram of one cardiac cycle is composed of:

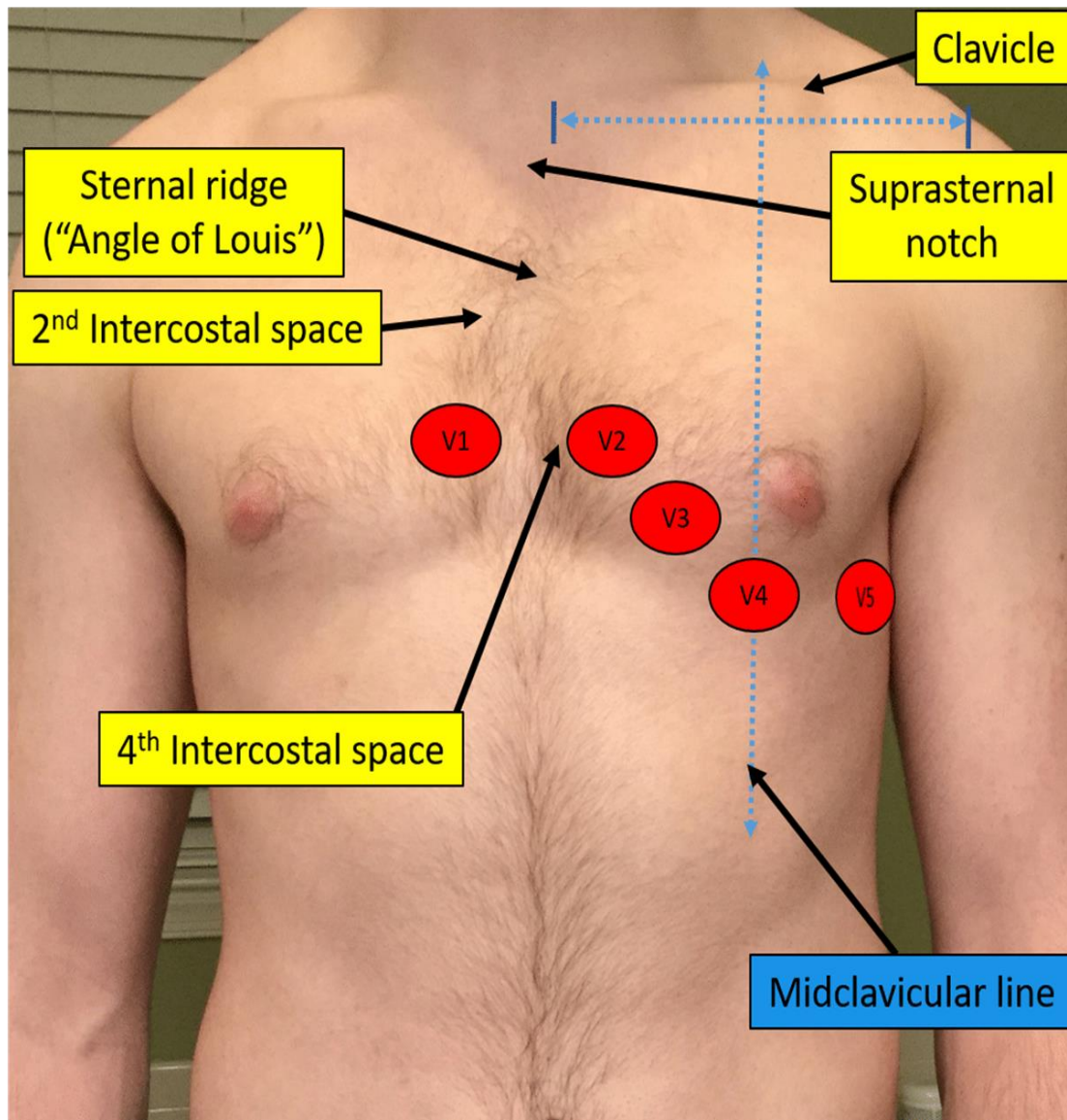


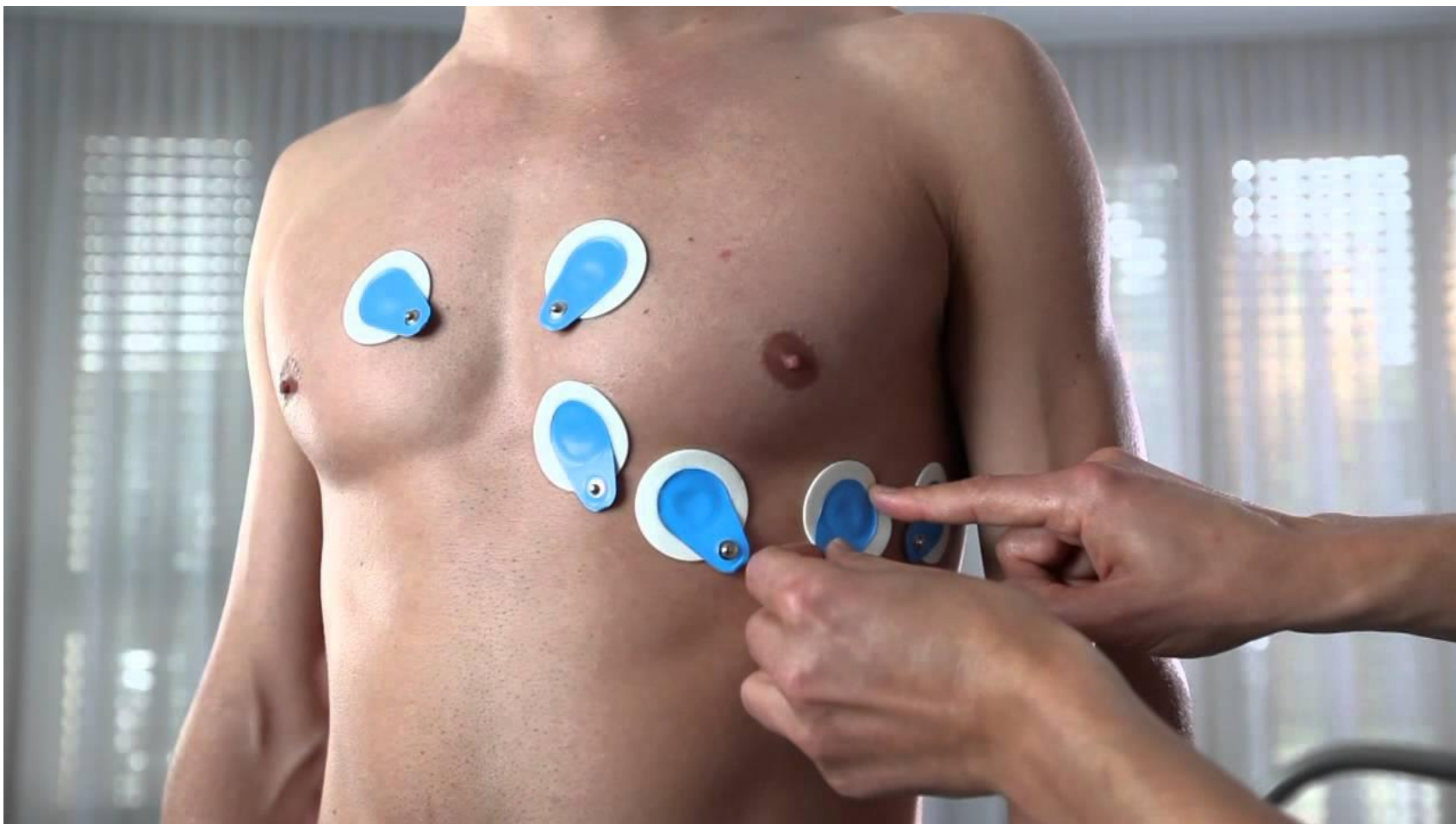
The standard ECG is composed of six limb leads and six chest leads



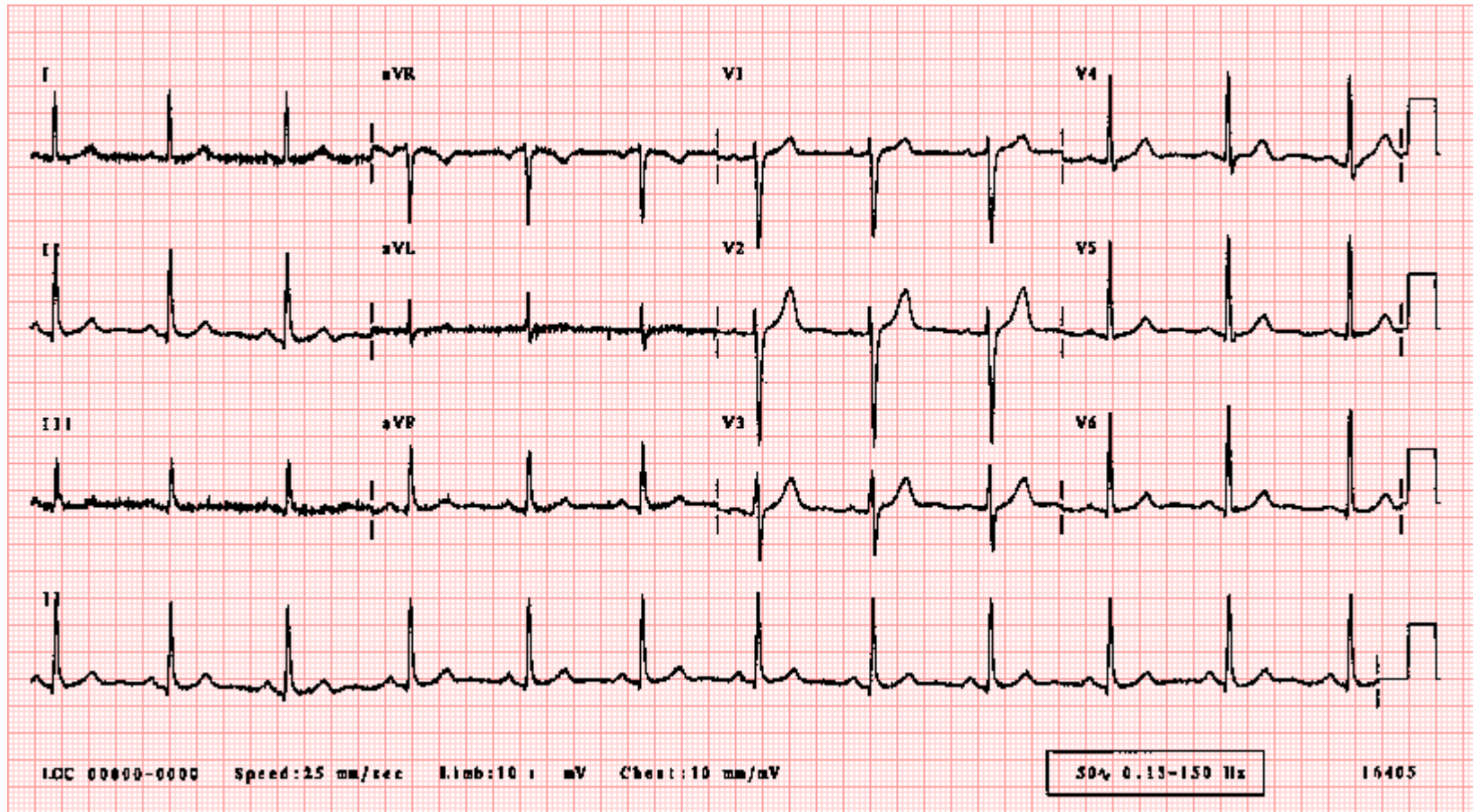
To determine sites of chest leads:

- From the **angle of Louis**, move your fingers to the right and you will feel a gap between the ribs. This gap is the **2nd Intercostal space**. From this position, run your fingers downward till you reach **4th intercostal space** which is the position for V1.





Normal electrocardiogram of 12 leads:-



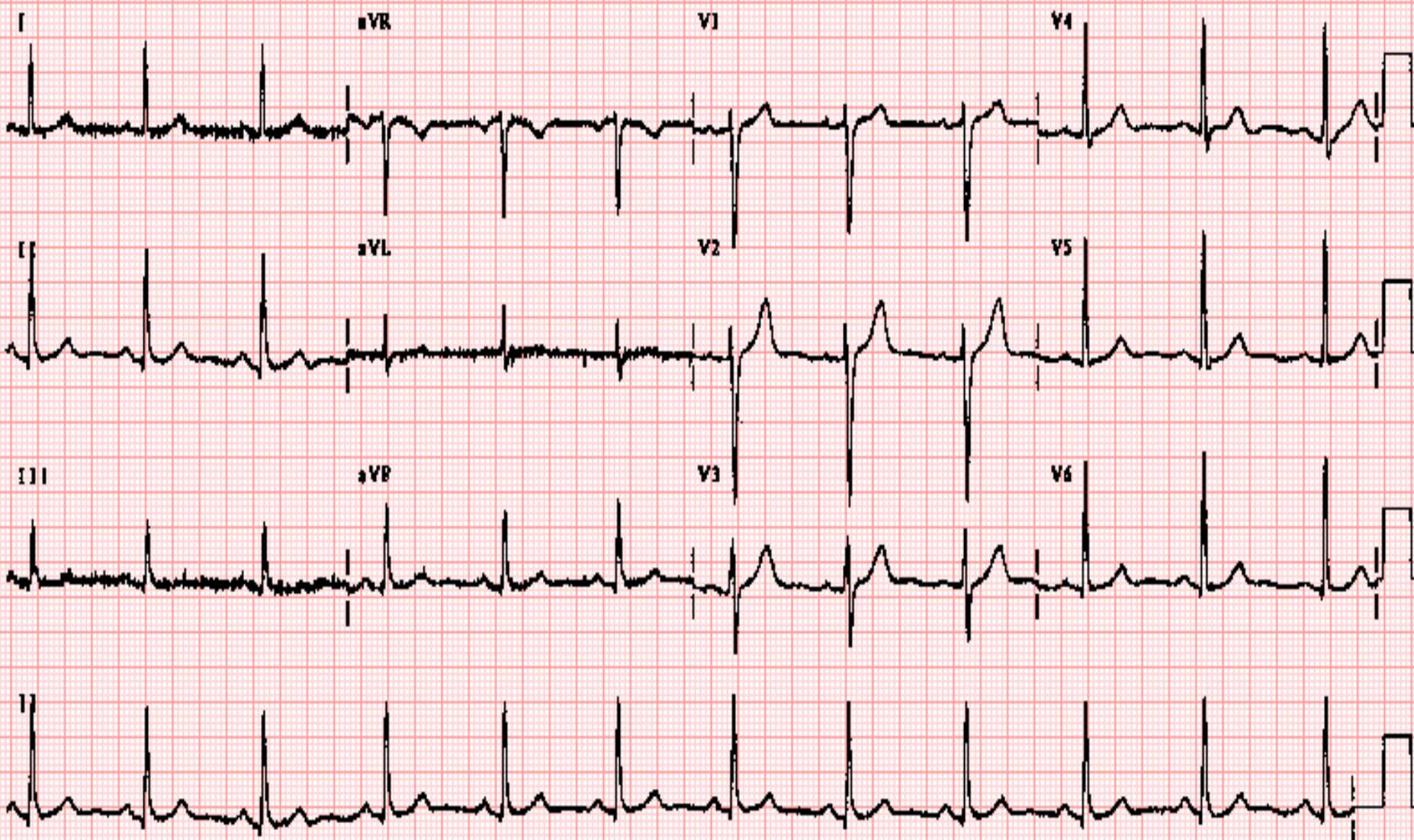
ECG process

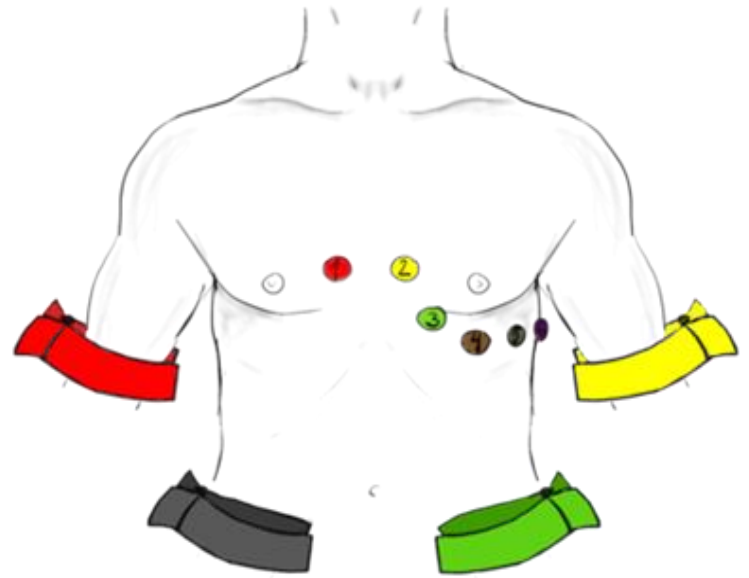
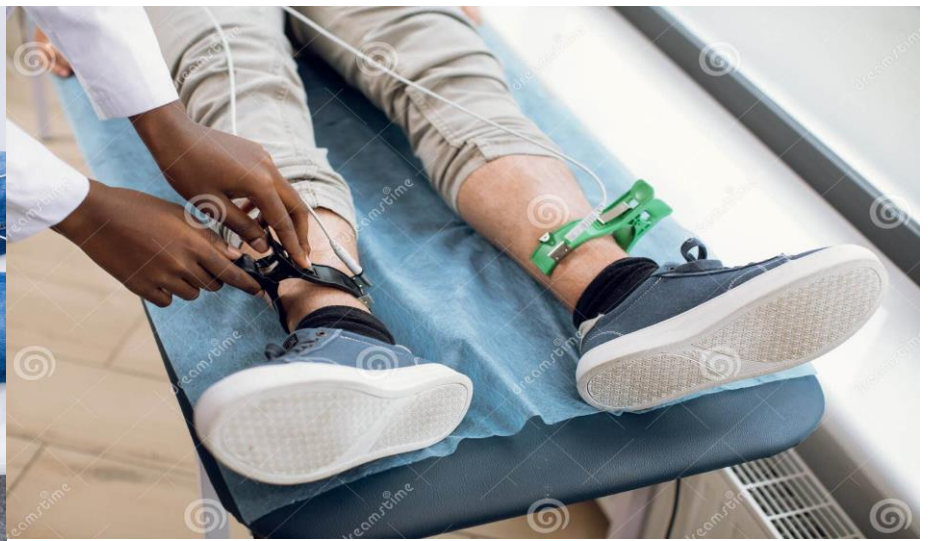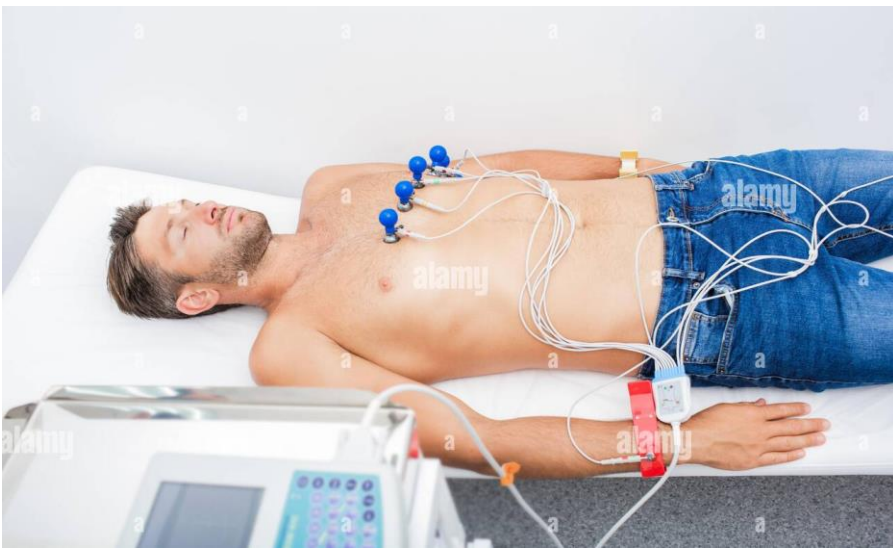- **Material and instruments:-**

- 1- Subject.
- 2- Electrocardiograph machine.

- **Method:**

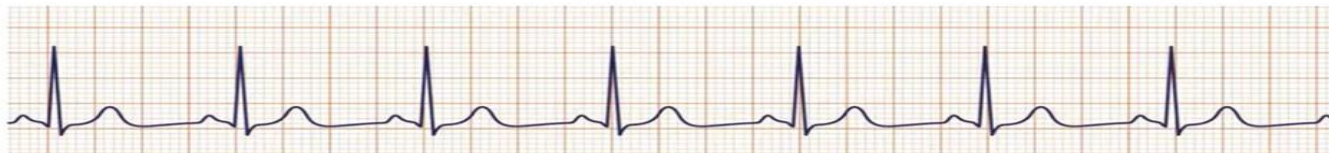- 1-The subject must be lie down and relax (prevent muscle contraction).
- 2- Connect the four limb leads, and six unipolar chest leads to correct sites.
- 3- Calibrate the voltage with the 1mv, vertically 1cm (2 large squares).
- 4- Calibrate the rate 25 mm/second.
- 5- Record the all 12 leads.
- 6- Record for each lead three or four complex waves.



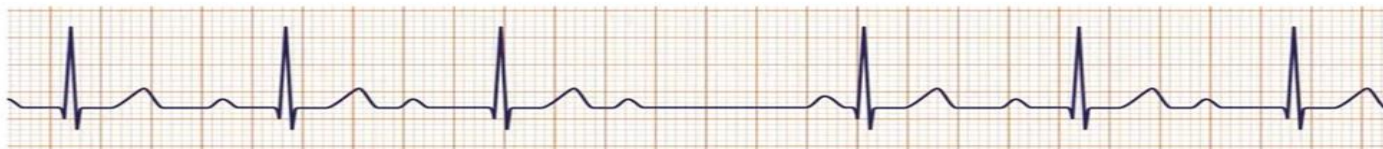


Analysis of the ECG

- **1- Rhythm** : Heart rhythm can be either **regular or irregular** .This can be determined by looking at the R-R wave interval (عدد المربعات الكبيرة بين الموجات).
- **2- Heart rate**: The heart rate is a number of heart cycles per minutes.
- **Regular**: by counting the number of large squares between two consecutive **R waves** and dividing this into **300**.
- **Irregular**: numbers of **QRS complex** are counted in **5 second** in the strip **multiplied by 12** to get the HR/minute.



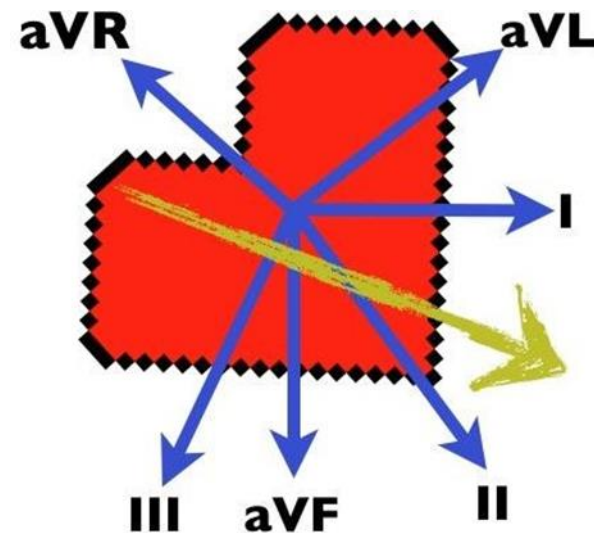
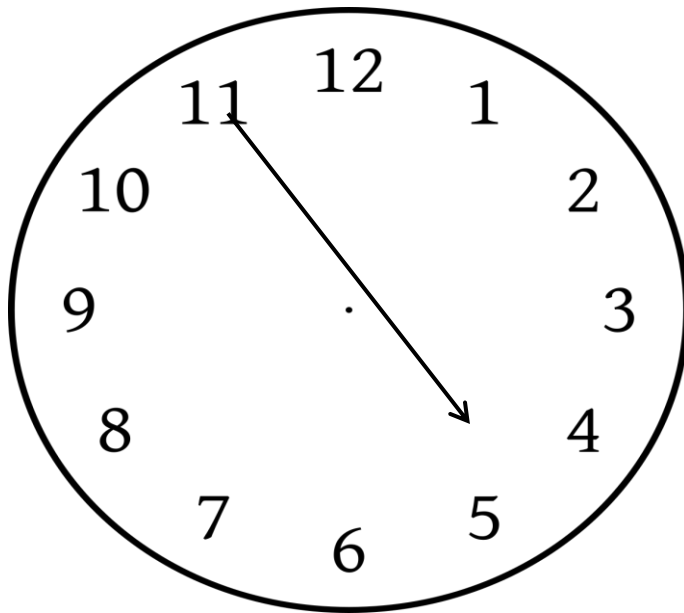
$$HR = \frac{300}{4} = 75 \text{ bpm}$$



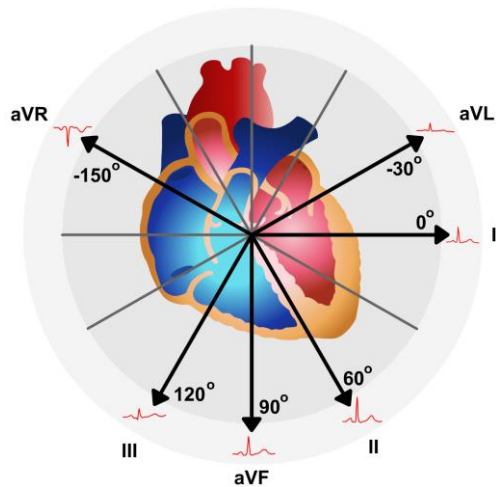
$$HR = 6 \times 12 = 72 \text{ bpm}$$

Analysis of the ECG

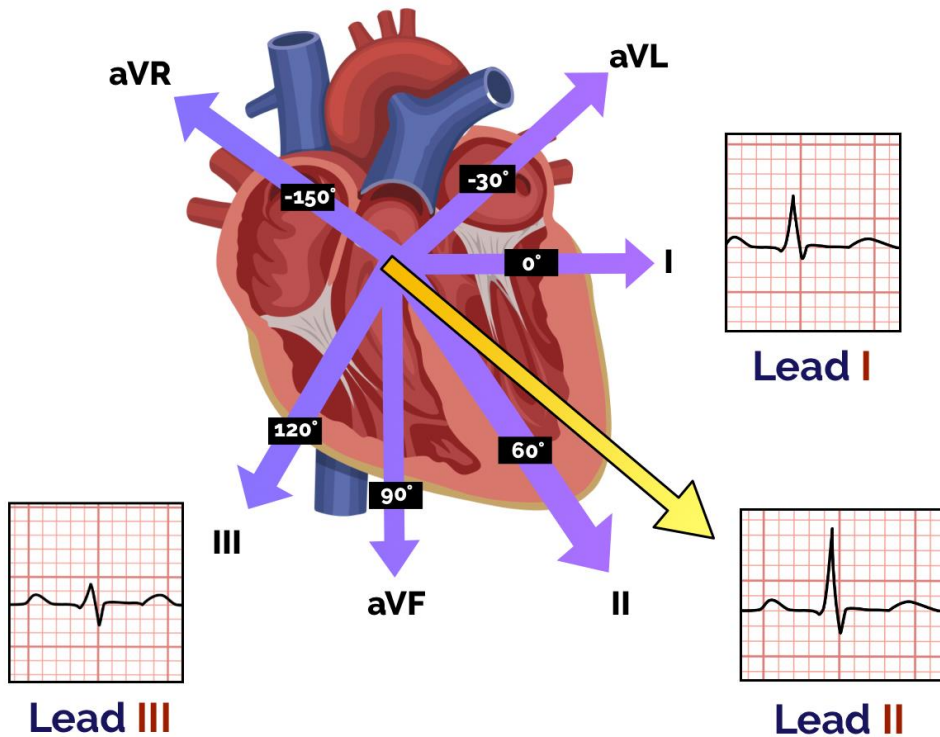
- **3- Electrical axis:** Cardiac axis describes the overall direction of electrical spread within the heart . In a healthy individual the axis should spread from **11 o'clock to 5 o'clock**. The direction of the axis can be derived more easily from **QRS complex** in lead I, lead II, and lead III.



Normal Cardiac Axis



GEEKY MEDICS 



Abnormal cases

Ischemia occurs when part of the heart muscle, the myocardium, is deprived of oxygen and nutrients.

Common causes of ischemia are:

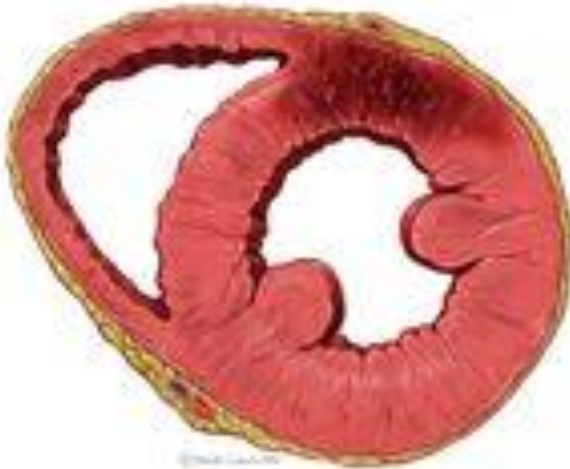
1. Narrowing or obstruction of a coronary artery.
2. A rapid arrhythmia, like atrial or ventricular fibrillation causing an imbalance in supply and demand.

A short period of ischemia causes *reversible* effects: The heart cells will be able to recover.

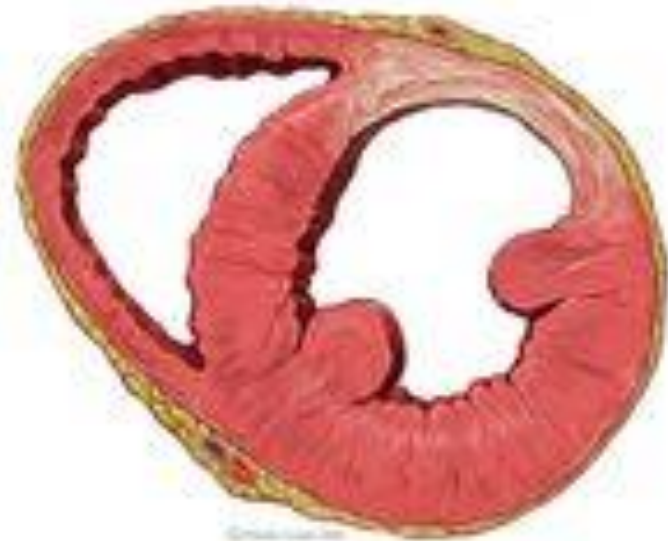When the episode of ischemia lasts for a longer period of time, heart muscle cells die. This is called **a heart attack or myocardial infarction**. That is why it is critical to recognize ischemia on the ECG in an early stage.

Ischemic changes

Necrosis



Fibrosis



Case study:

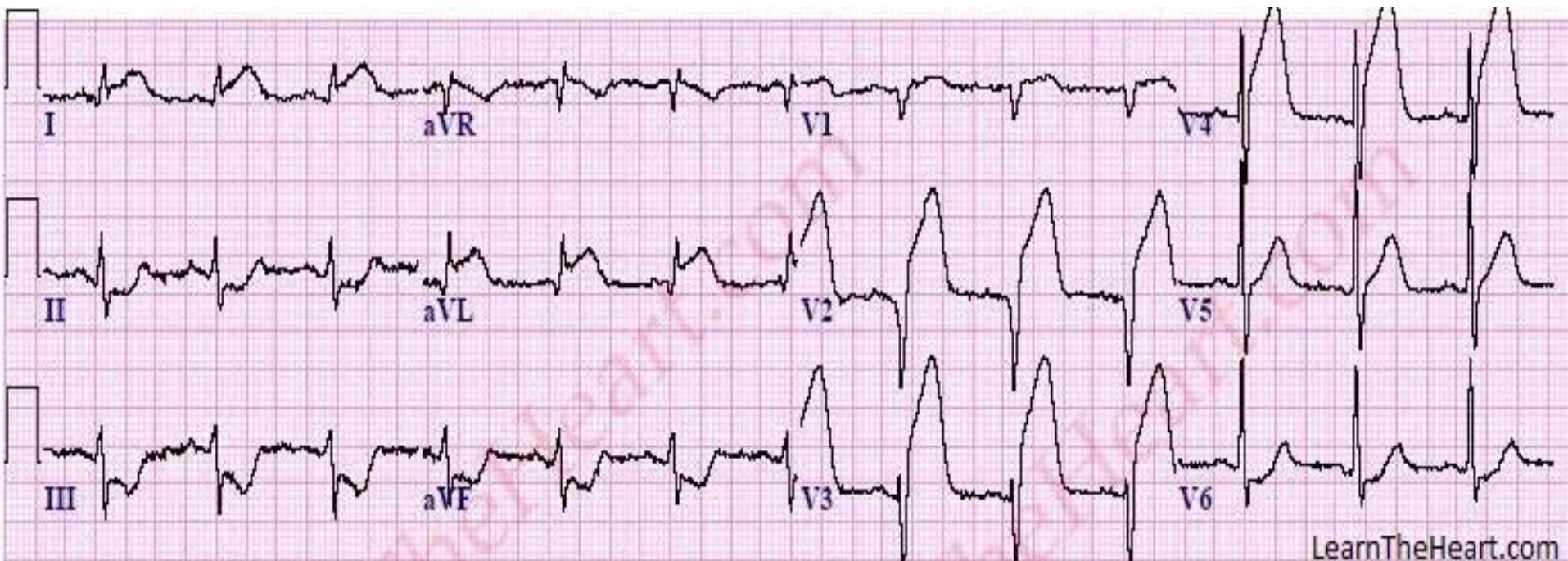
A 70-year-old male presents to the Emergency complaining of chest pain. He was watching a football game when his pain started. He describes the pain as pressure over the left chest that started 45 minutes prior to arrival. The pain radiates to the left shoulder and is associated with some nausea but no vomiting.

الجلطة القلبية

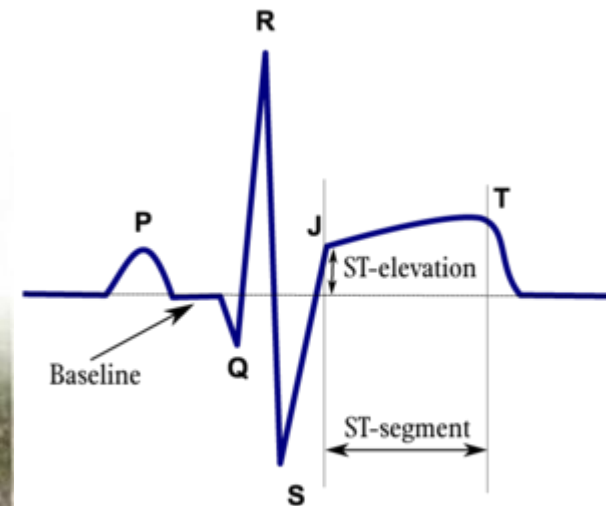
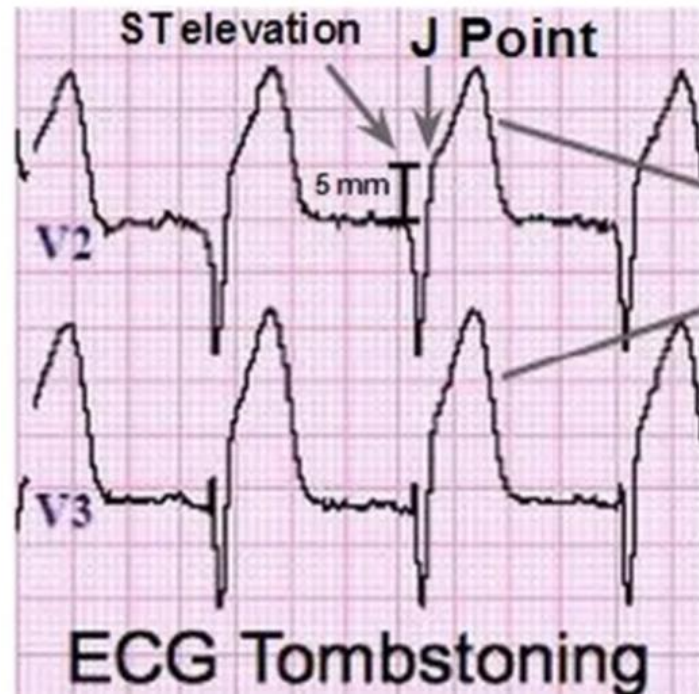
Myocardial infarction (MI)

The ECG findings of an acute anterior **myocardial infarction (MI)** will include:

- * ST segment elevation in the anterior leads (V3 and V4)
- * Reciprocal ST segment depression in the inferior leads (II, III and aVF).



MI

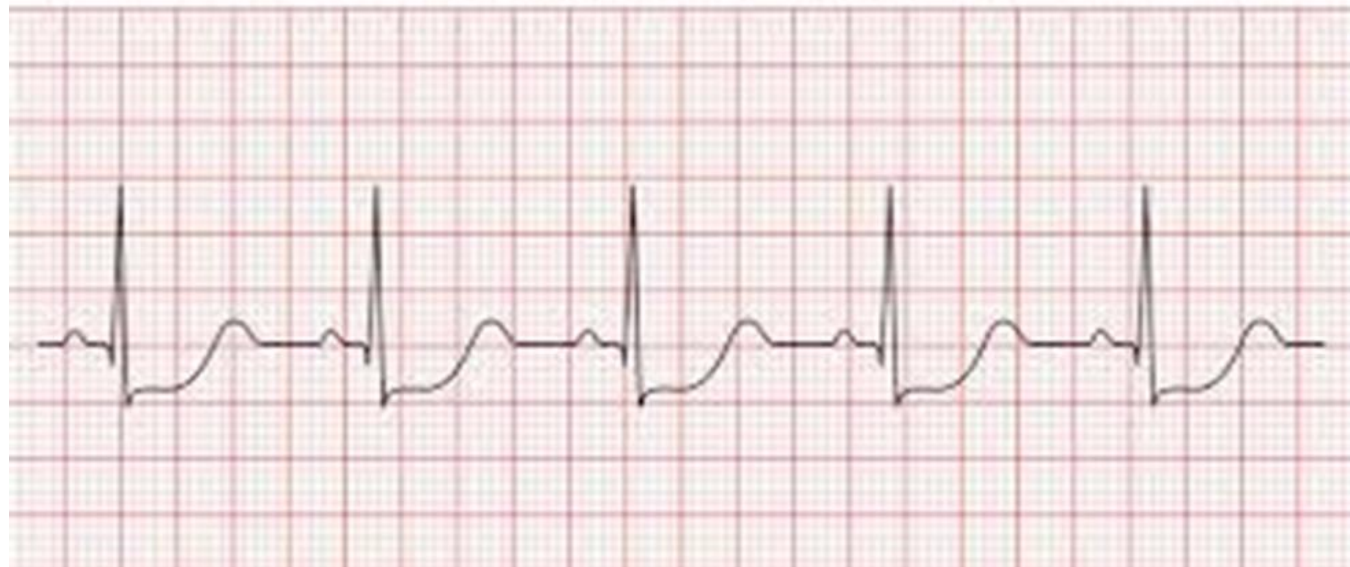


How to measure ST elevation?

الذبحة القلبية Unstable angina

- * **Angina** results from acute obstruction of a coronary artery without myocardial infarction.
- * Symptoms include chest discomfort with or without dyspnea, nausea.
- * On ECG **ST-segment depression**. transient

ST depression



ECG



normal ECG



subendocardial
ischemia



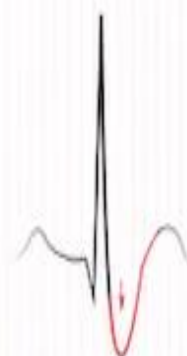acute
subendocardial
ischemia



transmural
ischemia



transmural
heart
attack



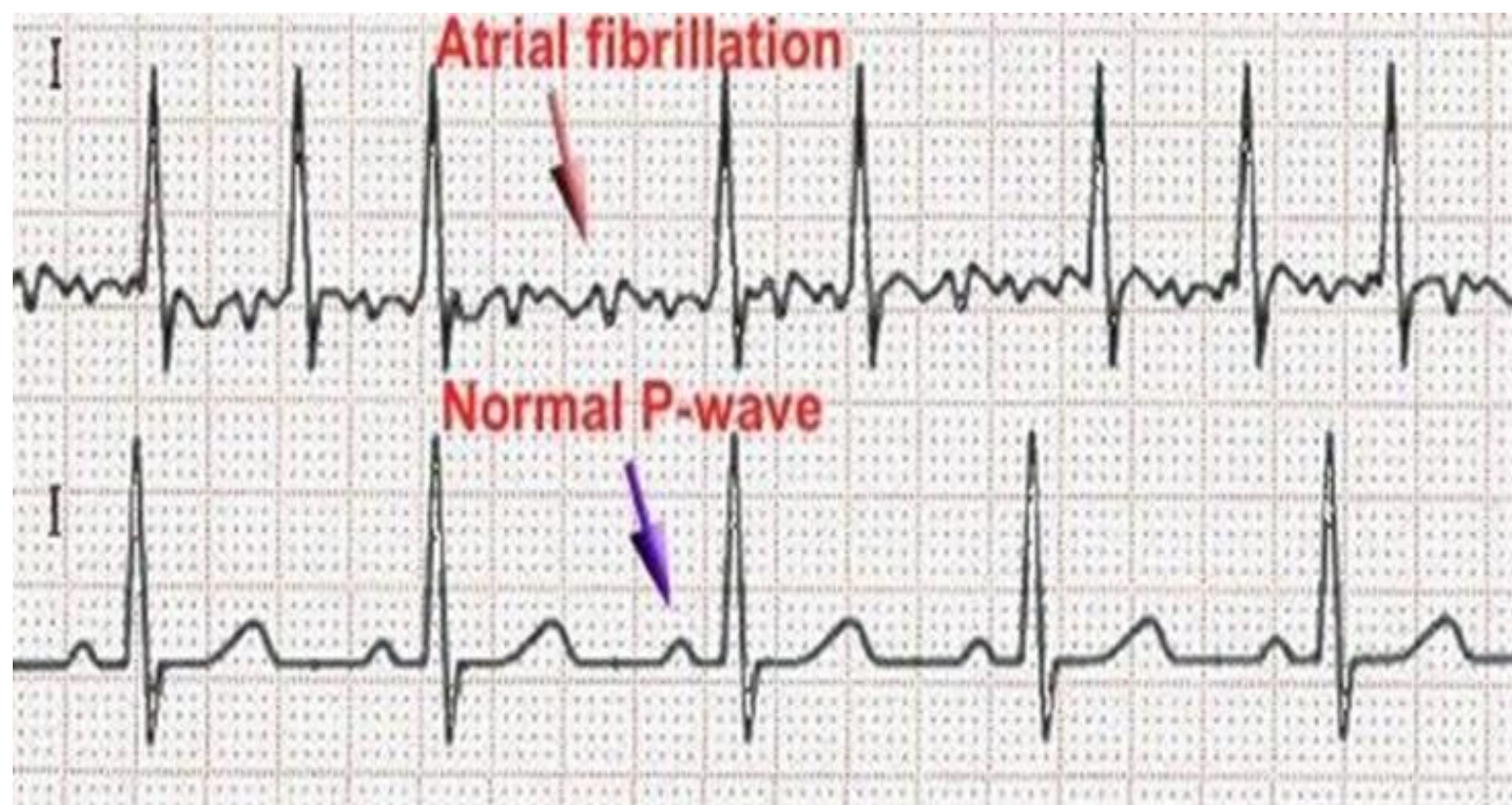
digitalis
intoxication



pericarditis



hyperkalemia



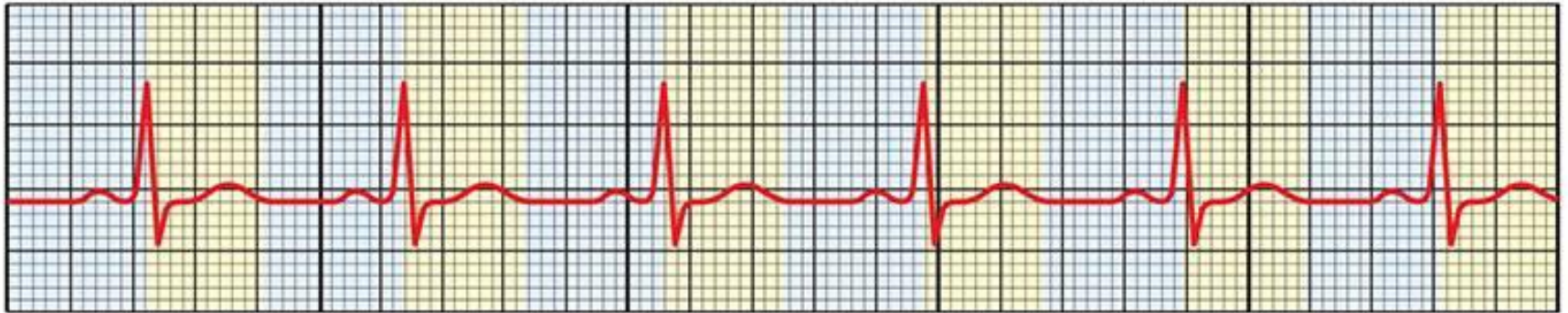توقف القلب Asystole

- * Is when the heart's electrical system fails, causing the heart to stop pumping.
- * This is also known as “flat-line” or “flat-lining” on ECG
- * Without immediate CPR or medical care, this condition is deadly within minutes.

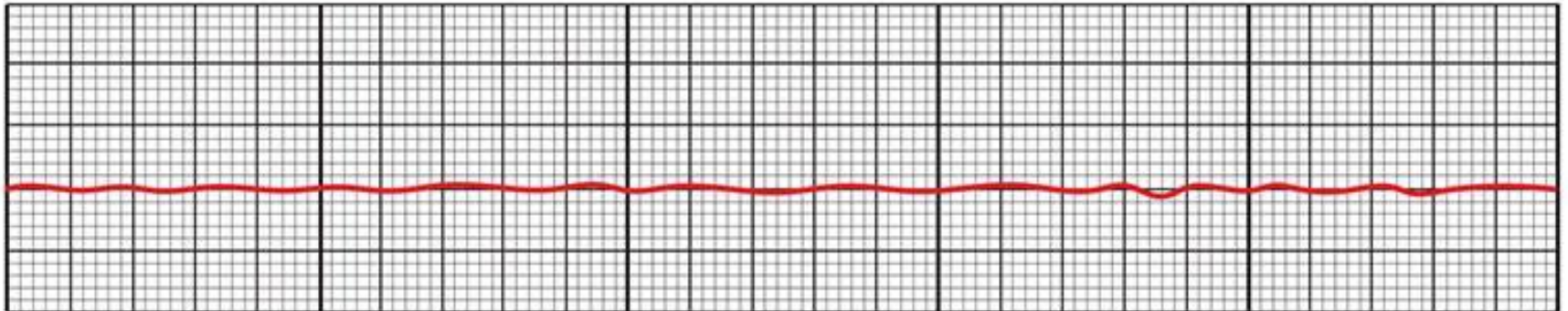
Asystole

Normal EKG

□ Systole □ Diastole



Asystole



ECG MONITORING IN THEATRE

مراقبة تخطيط القلب في صالة العمليات

Cardiac arrhythmias during anaesthesia and surgery occur
In many cases.

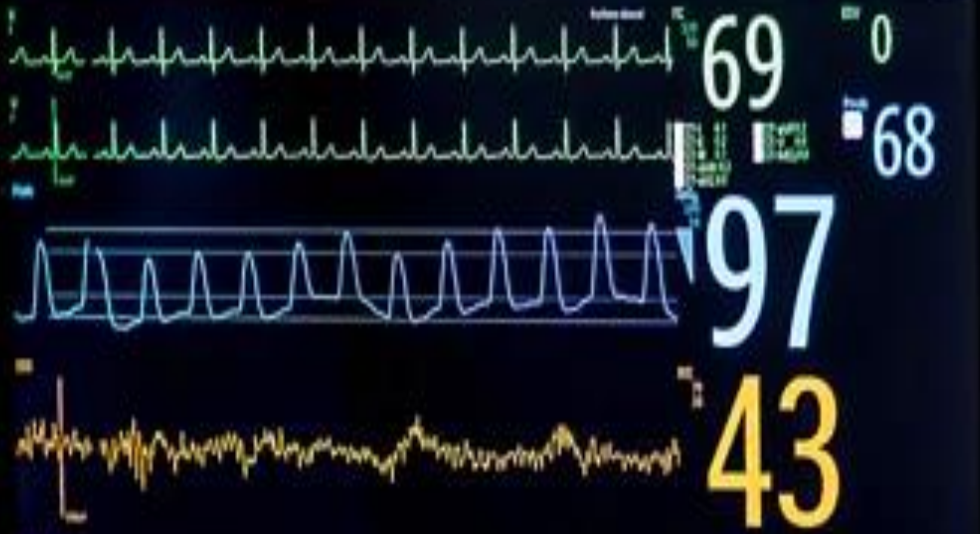Many are of clinical significance
and therefore their detection is of considerable
importance.

Examining an ECG strip:

1. What is the ventricular rate? Brady or tachy cardia
2. Is the QRS complex of normal duration or widened?
3. Is the QRS regular or irregular?
4. Are P waves present and are they normally shaped?
5. How is atrial activity related to ventricular activity?

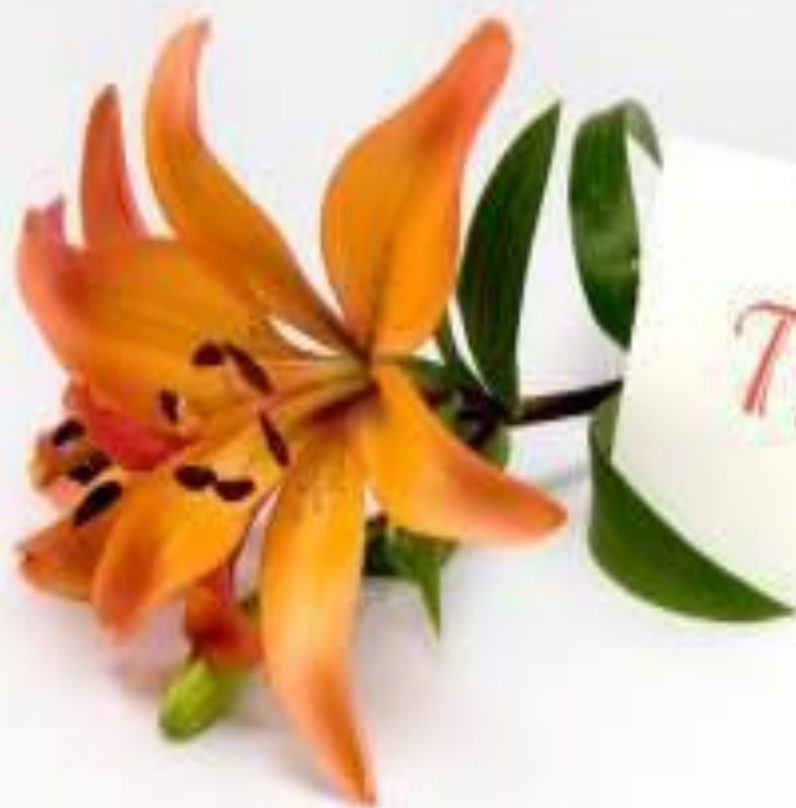IntelliVue MX800

Patient ID: 123456789 Date: 12 Jan 2014 10:01



BP 121/82 (91) HR 83 RR 0 SpO2 36.0 10:01 +01:34 22

PHILIPS



Thank You