

Periodontal Consideration In Adult Orthodontic Treatment

In general, orthodontists consider adults as those whose growth is essentially completed. The mean cutoff age for females is 18 (which means for some slow matures it would be later), but for males it is 20 or 21, simply because males often are still growing up to that age. Patients who seek orthodontic treatment beyond those ages fall into two quite different groups:

1- Younger adults (typically younger than 35, often in their 20s) who desired but did not receive comprehensive orthodontic treatment at youths and now seek it as they become financially independent and, the goal of treatment is to improve their quality of life. They usually seek the maximum improvement that is possible. They may or may not need extensive treatment by other dental specialists but frequently need interdisciplinary consultation.

2- An older group, typically in their 40s or 50s, who have other dental problems and need orthodontics as part of a larger treatment plan. The goal is quite different, they usually seek to maintain what they have, not necessarily to achieve as ideal an orthodontic result as possible. For them, orthodontic treatment is needed to meet specific goals that would make control of dental disease and restoration of missing teeth easier and more effective, so the orthodontics is an adjunctive procedure to the larger periodontal and restorative goals.

Adjunctive orthodontic treatment, particularly the simpler procedures, often can be carried out within the context of general dental practice. In adults, growth has been essentially completed and is no longer a variable requiring major consideration in managing treatment, and the types and magnitude of tooth movement required for most adjunctive procedures are straightforward. Adjunctive treatment does not require familiarity with the principles of comprehensive orthodontic treatment, but it does presume an understanding of orthodontic diagnosis and treatment planning. Comprehensive orthodontics for adults tends to be difficult and technically demanding. The absence of growth means that growth modification to treat jaw discrepancies is not possible. The only possibilities are tooth movement for camouflage or orthognathic surgery, but applications of skeletal anchorage now are broadening the scope of orthodontics to include some patients who would have required surgery even a few years ago.

Adjunctive orthodontic treatment for adults is, by definition, tooth movement carried out to facilitate other dental procedures necessary to control disease, restore function, and/or enhance appearance,

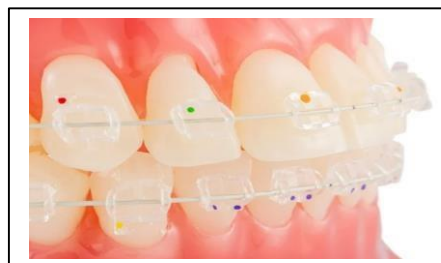Usually:

- 1- it involves only a part of the dentition,
- 2- The primary goal usually is to make it easier or more effective to replace missing or damaged teeth.
- 3- Making it easier for the patient to control periodontal problems is a frequent secondary goal and sometimes the primary goal.
- 4- The treatment duration tends to be a few months, rarely more than a year,
- 5- Long-term retention often is supplied by the restorations.
- 6- Whether one or several practitioners are involved, adjunctive orthodontics must be coordinated carefully with the periodontal and restorative treatment.

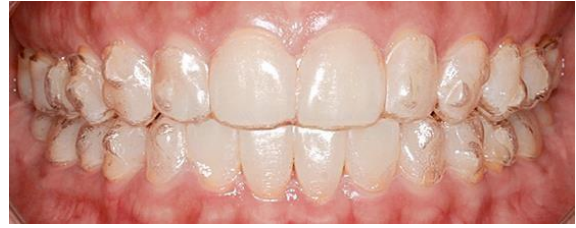In contrast, the ***comprehensive orthodontics*** for adults is the same as for adolescents:

- 1- It aims to acquiring the best combination of dental and facial appearance, dental occlusion, and stability of the result to maximize benefit to the patient.
- 2- Comprehensive orthodontics requires either a complete fixed orthodontic appliance or a high level of skill in managing clear aligner therapy.
- 3- Intrusion of some teeth is likely to be needed,
- 4- Orthognathic surgery may be considered to improve jaw relationships.
- 5- The duration of treatment from braces on to braces off exceeds 1 year.
- 6- Adults receiving comprehensive treatment are the main candidates for esthetically enhanced appliances; although aesthetic orthodontic appliances are not restricted to adult patients, the drive for less visible appliances has come from adults. This demand has led to the development of a number of orthodontic appliances with improved aesthetics such as:

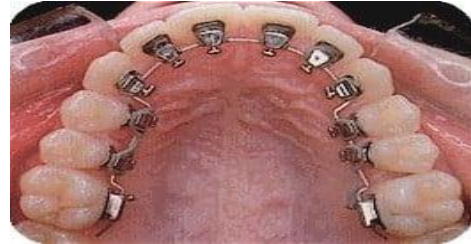- 1- Aesthetic fixed appliance and aesthetic wires



2- Invisalign or clear aligner



3- Lingual orthodontic appliance



Principles of Adjunctive Treatment

Treatment Goals:

A-Facilitate restorative work by appropriate positioning of teeth

B-Improve the periodontal health by reducing areas that harbor plaque, and making it simpler for the patient to maintain good oral hygiene

C- Position the teeth so that occlusal forces are transmitted along the long axis of the tooth, and tooth wear is more evenly distributed throughout the arch.

The following are examples of problems that benefit from a joint approach between the orthodontist and the restorative dentist:

- A. Uprighting of abutment teeth: following tooth loss adjacent teeth may drift into the space. Uprighting these abutment teeth can facilitate the placement of replacement prosthetic teeth
- B. Redistribution or closure of spaces: following tooth loss it may be possible to close the remaining space, or move a proposed abutment tooth into the middle of an edentulous span, in order to aid construction of a more robust prosthesis. If implants are required then the roots may need to be repositioned to permit surgical placement.
- C. Intrusion of over-erupted teeth: one of the side effects of tooth loss is over-eruption of the opposing tooth. This can interfere with restoration of the space, so the over-erupted tooth can be intruded using orthodontics.

D. Extrusion of fractured teeth: sometimes it is necessary to extrude a fractured tooth, to bring the fracture line supragingivally to allow placement of a crown or restoration. There is a limit to this, as excess extrusion will reduce the amount of tooth supported by bone, reducing the crown-to-root ratio.

some important things must be kept in mind:

1- Orthodontic treatment for temporomandibular dysfunction (TMD) should not be considered adjunctive treatment.

2- Although intrusion of teeth can be an important part of comprehensive treatment for adults, it probably should be managed by an orthodontist even as an adjunctive procedure because of the technical difficulties involved and the possibility of periodontal complications. As a general guideline in treatment of adults with periodontal involvement and bone loss, lower incisor teeth that are excessively extruded are best treated by reduction of crown height, which has the added advantage of improving the ultimate crown-to-root ratio of the teeth. For other teeth, tooth–lip relationships must be kept in mind when crown height reduction is considered.

3- Crowding of more than 3 to 4 mm should not be attempted by stripping enamel from the contact surfaces of the anterior teeth. It may be advantageous to strip posterior teeth to provide space for alignment of the incisors, but this requires a complete orthodontic appliance and cannot be considered adjunctive treatment.

Once all the problems have been identified and categorized, the key treatment planning question is: can the occlusion be restored within the existing tooth positions or must some teeth be moved to achieve a satisfactory, stable, healthy, and esthetic result? The goal of providing a physiologic occlusion and facilitating other dental treatment has little to do with Angle's concept of an ideal occlusion. At this point, it is important to consider the difference between realistic and idealistic treatment planning. In older patients, searching for an "ideal" result could involve more treatment than would really benefit the patient. Obviously, the time needed for any orthodontic treatment depends on the severity of the problem and the amount of tooth movement desired, but with efficient use of orthodontic appliances, it should be possible to reach the objectives of adjunctive treatment within 6 months as a practical matter, this means that like comprehensive orthodontics, most adjunctive orthodontics cannot be managed well with traditional removable appliances. It requires either fixed appliances or a sequence of clear aligners to get the job done in a reasonable time frame. In addition, it is becoming increasingly apparent that skeletal anchorage makes adjunctive tooth movement more effective and efficient. For adjunctive treatment, this is almost always in the form of alveolar bone screws.

In many ways the approach to treatment in adult patients follows the same process as that for children.

There are however some problems that are specific to adult patients:

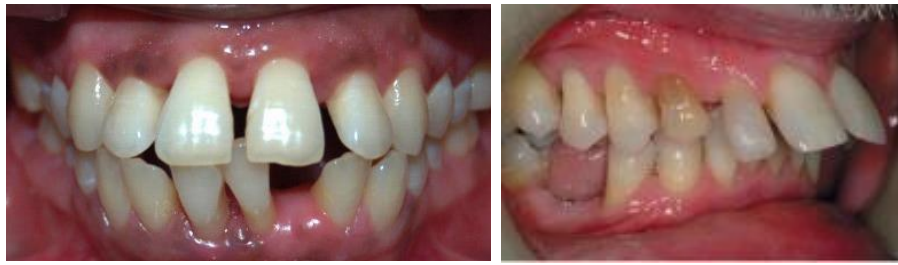1-Lack of growth: Although growth continues at a very slow rate throughout adulthood, the majority of growth changes have occurred by the end of puberty. This means that there is no scope for growth modification, so skeletal discrepancies can only be treated with either orthodontic camouflage, or combined orthodontics and orthognathic surgery. It can also be more difficult to reduce overbites without the benefit of growth. Where possible, overbite reduction should be achieved by intrusion of the incisors, rather than the more common method of extruding the molars (provided this does not compromise the smile aesthetics). This is because extrusion of posterior teeth is more prone to relapse in adults.

2-Periodontal disease: Adult patients are more likely to be suffering, or have suffered, from periodontal disease. A reduced periodontium is not a contraindication to orthodontic treatment, but it is vital that any active periodontal disease is treated and stabilized before orthodontic treatment can begin.

Periodontal disease is more common in adults, and is therefore an important factor that must be considered in all adult orthodontic patients. It is wise to undertake a full periodontal examination in all adult patients to exclude the presence of active periodontal disease. Periodontal attachment loss is not a contraindication to orthodontic treatment, but active periodontal disease must be treated and stabilized before treatment begins. The presence of plaque is the most important factor in the initiation, progression and recurrence of periodontal disease. Teeth with reduced periodontal support can be safely moved provided there is adequate plaque control.

Malalignment problems caused by periodontal disease:

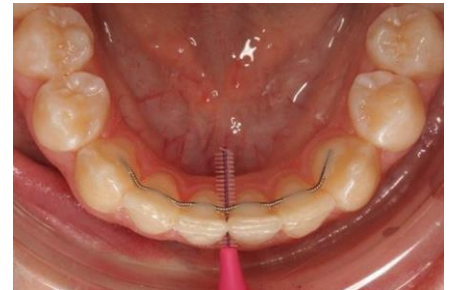
Loss of periodontal support can lead to pathological tooth migration of a single tooth or a group of teeth. The commonest presentation of periodontal attachment loss is labial migration and spacing of the incisors. The teeth lie in an area of balance between the tongue lingually and the lips and cheeks buccally. The forces from the tongue are higher than those exerted by the lips and cheeks, but a normal healthy periodontium resists these proclining forces from the tongue. If, however periodontal attachment is lost as a result of disease, then the teeth will be proclined forwards. In addition, if posterior teeth are lost then this lack of posterior support produces more pressures on the labial segment, leading to further proclination of the incisors.



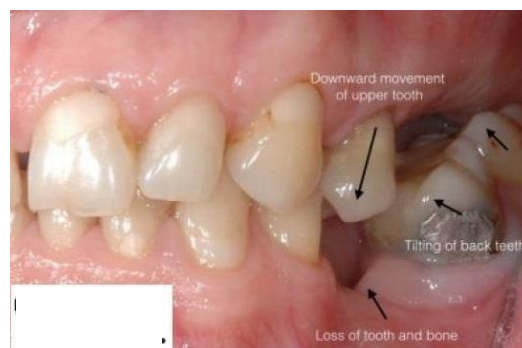Orthodontic management of patients with periodontal disease:

Once the periodontal disease has been fully stabilized, and the patient is able to maintain a good standard of oral hygiene, treatment can begin (Fig.4) and as following:-

- A- Lighter forces are required, due to the reduced periodontal support,
- B- ideally bonds rather than bands should be used on the molars to aid oral hygiene.
- C- Removal of excess adhesive will also help to reduce plaque retention.
- D- Due to the reduced alveolar bone support the centre of resistance of the tooth moves apically. This means there is a greater tendency for teeth to tip excessively, so this must be carefully controlled with appropriate treatment mechanics.
- E- Retention at the end of treatment needs to be carefully considered. Even when the teeth are aligned and the periodontium is healthy, the problem of reduced periodontal support remains. With reduced periodontal attachment there will always be a tendency for the forces of the tongue to procline the incisors. These cases require permanent retention, often in the form of bonded retainers, and the patient must be taught how to maintain excellent oral hygiene around these retainers.



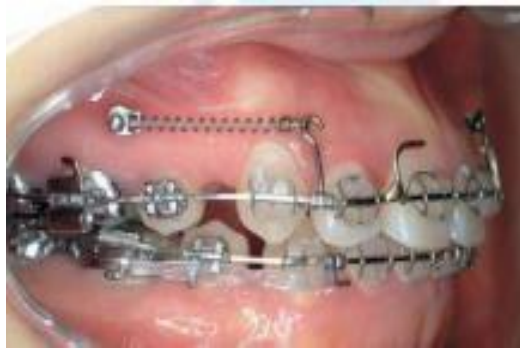3- Missing or heavily restored teeth: Tooth loss may lead to drifting and/or tilting of adjacent teeth and overeruption of opposing teeth into the space. In addition, atrophy of the alveolar bone can occur, leading to a narrowing or ‘necking’ in the site of the missing tooth or teeth This can make tooth movement into these areas more difficult.



Heavily restored teeth are more common in adults and may complicate the orthodontic treatment. The choice of extractions may be determined by the prognosis of the restored teeth, and bonding to certain restorative materials is more difficult than bonding directly to enamel. Specialist techniques and materials are needed when bonding fixed appliances to gold, amalgam and porcelain, and the patient needs to be warned that the restoration may be damaged when removing the fixed appliance. For this reason, if possible, it is best to leave any definitive restorations until after the orthodontic treatment.

4- Physiological factors affecting tooth movement: There is a reduced tissue blood supply and decreased cell turnover in adults, which can mean that initial tooth movement is slower in adults, and may be more painful. Lighter initial forces are therefore advisable.

5- Adult motivation and attitude towards treatment: Adults have the potential to be excellent, well-motivated patients. ; however, this is not always the case. It has been suggested that the increased co-operation may compensate for slower initial tooth movement. Adults tend to be more conscious of the appearance of the appliance, so there has been a drive towards more aesthetic orthodontic appliances (like transparent bracket, lingual appliance or clear aligner). Although distal movement of the upper molars with headgear is technically feasible, adults are more reluctant to wear extra-oral appliances. Alternative sources of anchorage are therefore more commonly used in adult patients, such *as implant-based anchorage*



With an increasing number of patients keeping their teeth for longer, there is a greater need for interdisciplinary treatment of patients with complex dental problems. Where collaboration is needed between the orthodontist and the restorative dentist, it is helpful to see the patients jointly to formulate a coordinated and appropriate treatment plan. Orthodontic treatment in these cases does not necessarily require comprehensive correction aiming for an ideal occlusion.