

## **ALLERGIC AND HYPERSENSITIVITY REACTIONS**

The modern dentist uses a wide variety of drugs to treat patients, including antibiotics, hypnotics, and anesthetics.

All practitioners who use these medications must know how to manage adverse reactions triggered by these agents.

A dental practitioner also uses a wide range of materials such as impression materials, adhesives, latex, and restorative and endodontic materials that contain potential allergens. These include preservatives, coloring agents, fixatives, binding agents, flavorings, and latex.

### **Hypersensitivity Reactions**

Immunologic reactions may be of several different types: type 1 IgE-mediated (anaphylactic), type 2 antibody-mediated, type 3 (immune complex-mediated), and type 4 (cell-mediated or delayed hypersensitivity). Type 1 reactions are acute (e.g., penicillin, latex, or peanut allergy) and require immediate recognition and action.

Type 2 reactions are not usually found in response to dental materials or drugs, but are found in autoimmune conditions affecting the oral cavity, such as pemphigus.

Type 3 reactions can be seen in response to dental materials, but more commonly in response to viral infections such as recurrent herpes labialis, giving rise to erythema multiforme or Stevens Johnson syndrome .

**Delayed hypersensitivity (cell-mediated or contact sensitivity) reactions to dental materials are very common and are usually seen in the oral cavity where an amalgam or gold restoration is in direct contact with the buccal or lingual mucosa. Stomatitis associated with allergy.**

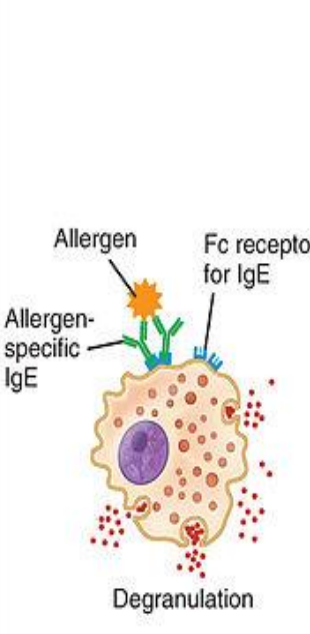
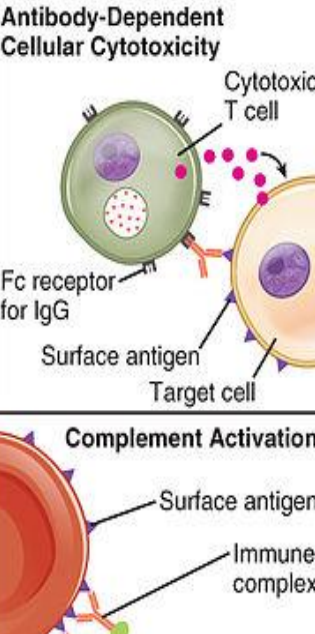
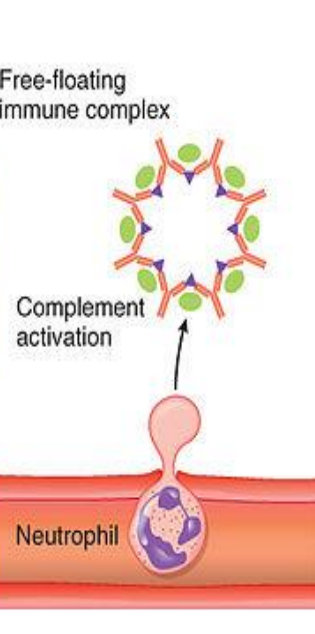
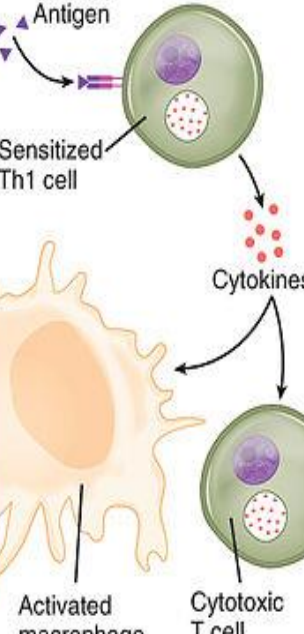
Acute allergic reactions are caused by an immediate-type hypersensitivity reaction mediated by IgE and are the most serious of allergies.<sup>40</sup> Reactions can occur rapidly, and full-scale anaphylactic reactions may occur and be associated with

local as well as systemic swelling. Type 1 reactions require the presence of mast cells with attached IgE.

A patient previously exposed to a drug or other antigen has antibody (primarily IgE) fixed to mast cells. When the antigen (in the form of a drug, food, or airborne substance) is reintroduced into the body, it will react with and cross-link the cell-bound antibody.

This causes an increase in intracellular calcium and the release of preformed mediators including histamine, proteases, and newly synthesized lipid-derived mediators such as leukotrienes and prostaglandins.

Cytokines are also released, which attract eosinophils and augment the inflammatory response. These substances cause vasodilation and increased capillary permeability, ultimately leading to fluid and leukocyte accumulation in the tissues and edema formation. Constriction of bronchial smooth muscle results when IgE is bound in the pulmonary region. The anaphylactic reaction may be localized, producing urticaria and angioedema, or may result in a generalized reaction, causing anaphylactic shock.

 <p><b>Type I</b></p>	 <p><b>Type II</b></p>	 <p><b>Type III</b></p>	 <p><b>Type IV</b></p>
<b>IgE-Mediated Hypersensitivity</b>	<b>IgG-Mediated Cytotoxic Hypersensitivity</b>	<b>Immune Complex-Mediated Hypersensitivity</b>	<b>Cell-Mediated Hypersensitivity</b>
IgE is bound to mast cells via its Fc portion. When an allergen binds to these antibodies, crosslinking of IgE induces degranulation.	Cells are destroyed by bound antibody, either by activation of complement or by a cytotoxic T cell with an Fc receptor for the antibody (ADCC)	Antigen-antibody complexes are deposited in tissues, causing activation of complement, which attracts neutrophils to the site	Th1 cells secrete cytokines, which activate macrophages and cytotoxic T cells and can cause macrophage accumulation at the site
Causes localized and systemic anaphylaxis, seasonal allergies including hay fever, food allergies such as those to shellfish and peanuts, hives, and eczema	Red blood cells destroyed by complement and antibody during a transfusion of mismatched blood type or during erythroblastosis fetalis	Most common forms of immune complex disease are seen in glomerulonephritis, rheumatoid arthritis, and systemic lupus erythematosus	Most common forms are contact dermatitis, tuberculin reaction, autoimmune diseases such as diabetes mellitus type I, multiple sclerosis, and rheumatoid arthritis

## Localized Anaphylaxis

A localized anaphylactic reaction involving superficial blood vessels results in urticaria (hives). Urticaria begins with pruritus (itching) in the area where histamine and other active substances are released. Wheals (welts) then appear on the skin as an area of localized edema on an erythematous base.

These lesions can occur anywhere on the skin or mucous membranes. There seems to be little doubt that the oral mucosa is well endowed with mast cells and that type 1 reactions can occur in the oral cavity. Urticaria of the lips and the oral mucosa

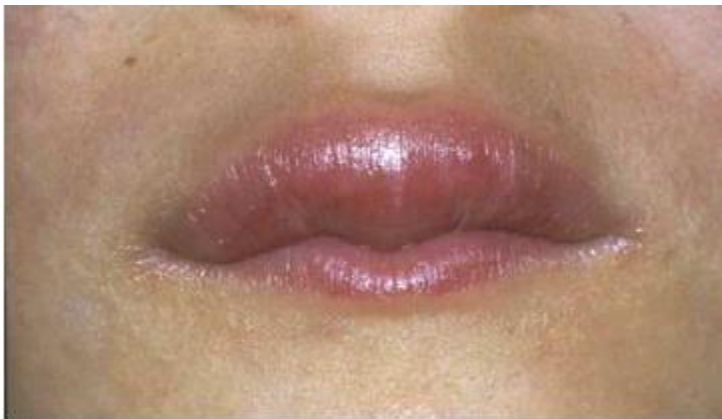occurs most frequently after food ingestion by an allergic individual. Common food allergens include chocolate, nuts, shellfish, and tomatoes.

In the oral allergy syndrome it is thought that patients become sensitized by inhalation of allergens such as birch, and then react orally to cross-reactive foods, including apples.

Drugs such as penicillin and aspirin may cause urticaria, and cold, heat, or even pressure may cause the reaction in susceptible individuals. Impression compounds, coloring agents, and preservatives, as well as ingredients of mouthwashes, may all cause local swelling or even anaphylaxis.

**Angioedema** is characterized by rapid development of edematous swelling, particularly of the head and neck, sometimes accompanied by urticarial rashes. It occurs when blood vessels deep in the subcutaneous tissues are affected, producing a large diffuse area of subcutaneous swelling under normal overlying skin. This reaction may be caused by contact with a known allergen, but a significant number of cases are idiopathic. Many patients have short-term disfiguring facial swelling, but if the edema involves the neck and extends to the larynx, it can lead to fatal respiratory failure.

Angioedema most commonly occurs on the lips and tongue and around the eyes. It is temporary and not serious, unless the posterior portion of the tongue or larynx compromises respiration.



Immediate type 1 swelling of the lips after ingestion of peanuts in a patient with peanut allergy.

The patient who is in respiratory distress should be treated immediately with

0.5 mL of epinephrine (1:1000) subcutaneously, or better intramuscularly. This can be repeated every 10 minutes until recovery starts.

The patient should be given oxygen, placed in a recumbent position with the lower extremities elevated unless there is a danger of shortness of breath or vomiting, given fluids intravenously, and transported to hospital immediately. Patients may need intubation to maintain the airway. When the immediate danger has passed, 50 mg diphenhydramine hydrochloride should be given four times a day until the swelling diminishes.

Hereditary angioedema (HAE) is another life-threatening condition that is not associated with allergens. It is a genetic disease with an autosomal dominant pattern of inheritance.

The underlying defect is a failure to produce adequate levels of C1 esterase inhibitor (C1 inh), This inhibitor controls the degree of complement activation. Activation of kinin-like substances causes a sudden increase in capillary permeability.

. Dental procedures can trigger attacks of HAE. These attacks do not respond well to epinephrine, and diagnosed patients are usually treated with the androgen danazol that increases C1 inhibitor plasma levels. Fresh-frozen plasma may be given to patients before dental procedures until recombinant C1 inh is available for clinical use.

### Generalized Anaphylaxis

Generalized anaphylaxis is an allergic emergency. The mechanism of generalized anaphylaxis is the reaction of IgE antibodies to an allergen, causing the release of histamine, bradykinin, and slow-reacting substance of anaphylaxis

(SRS-A) from mast cells and later eosinophils.

These chemical mediators cause the contraction of smooth muscles of the respiratory and intestinal tracts, as well as increased vascular permeability. Within dentistry, penicillin is a frequently encountered cause, but muscle relaxants, cephalosporins, sulfonamides, vancomycin, radiographic contrast media, and vaccines may also cause anaphylaxis.

The following factors increase the patient's risk for anaphylaxis:

- History of allergy to other drugs or food,
- History of asthma, family history of allergy (atopy), and parenteral administration of the drug.

**Anaphylactic reactions may occur within seconds of drug administration or 30–40 minutes later**, complicating the diagnosis. Symptoms of generalized anaphylaxis should be known so that diagnosis and prompt treatment may be initiated. It is important to be able to differentiate anaphylaxis from syncope or a hypoglycemic event.

The generalized anaphylactic reaction may involve the skin, the cardiovascular system, the gastrointestinal tract, and the respiratory system.

**The first signs often occur on the skin** and are similar to those seen in localized anaphylaxis (e.g., facial flushing, pruritis, paresthesia, or peripheral coldness).

**Pulmonary symptoms** include dyspnea, wheezing, and asthma.

**Gastrointestinal tract disease**, such as abdominal pain and vomiting, often follows skin symptoms.

**Symptoms of hypotension** (loss of consciousness, pallor, and a cold clammy skin) appear as the result of the loss of intravascular fluid. The pulse becomes rapid, weak, and faint. If untreated, this leads to shock. Patients with generalized anaphylactic reactions may die from respiratory failure, hypotensive shock, or laryngeal edema.

## **Management**

The most important therapy for generalized anaphylaxis **is the administration of epinephrine**. Clinicians should have a vial of aqueous epinephrine (at a 1:1000 dilution) and a sterile syringe easily accessible. **For adults, 0.5 mL of epinephrine should be administered intramuscularly or subcutaneously; smaller doses from 0.1 to 0.3 mL should be used for children, depending on their size.**



Epinephrine will usually reverse all severe signs of generalized anaphylaxis. If improvement is not observed in 10 minutes, readminister epinephrine. If the patient continues to deteriorate, several steps can be taken, depending on whether the patient is experiencing bronchospasm or edema.

**For bronchospasm, slowly inject 250 mg aminophylline intravenously, over a period of 10 minutes.** Too rapid an administration can lead to fatal cardiac arrhythmias. Do not give aminophylline if hypotensive shock is a part of the clinical picture. Inhalation sympathomimetics may also be used to treat bronchospasm, and oxygen should be given to prevent or manage hypoxia. For the patient with laryngeal edema, establish an airway.

### Latex Allergy

Latex allergy associated with undesirable cutaneous and mucosal reactions has been noticed with increasing frequency over the last few years, possibly related to the greater use of protective gloves. While less than 1% of the

general population is sensitized to latex, the US Occupational Safety and Health Administration estimates that over 8% of healthcare workers may be sensitized.

Dental staff and students appear to be at high risk for latex sensitization and the overall prevalence of skin sensitization in dentists in a number of studies was about 10%, higher in those reporting asthmatic symptoms.

Much of the sensitization appears to have been by inhalation of the glove powder and the rate of sensitization is now falling, since gloves are mainly powder free.

**The symptoms of latex allergy are usually those of type 1 hypersensitivity,** but contact dermatitis to rubber chemicals is also well described.

Sensitized individuals produce specific IgE antibody to **at least 10 potent latex allergens, Hev b1–Hev b 10**, The important concept that latex allergy can induce clinical symptoms to specific foods (food allergy) is reinforced by the demonstration of amino acid sequence homology between latex antigens and proteins in kiwi fruit, avocados, tomatoes, and potatoes.

### **Testing**

Recently a skin prick test reagent that contains most of the known clinically significant allergens for diagnosis of type 1 latex allergy has been standardized. The protein content of the gloves correlates with immunoreactivity and the ratio of the IgE to IgG response correlated positively with the severity of symptoms. In most studies, a history of atopy was a significant factor in latex allergy. There seems to be a reasonable correlation between in vitro; IgE testing and in vivo; skin prick tests.

## Management

Patients with latex allergy may also show high levels of positive responses to certain foods, so a good medical history is imperative.

[Urticaria, rhinitis, and eyelid edema can be immediate manifestations of latex allergy.](#) Severe systemic reactions (such as asthma and anaphylaxis) may

result in permanent disability or even death. In the health-care setting, the two major strategies for management are the safe care of the latex allergic patient and the prevention and treatment of occupational latex allergy in employees.

In managing a patient with latex sensitivity, the distinction between an immediate hypersensitivity reaction to latex and allergic contact dermatitis due to other irritants must be established. At initial evaluation, latex allergy status

should be established by the history and documented clearly on the chart. Any history of an immediate hyper-sensitivity reaction to latex necessitates a latex-free environment for that person, including “hypoallergenic” latex gloves. [Latex-containing products \(such as blood pressure cuffs and disposable tourniquets\)](#) should not be worn or used in the vicinity of persons who are allergic to latex.

Premedication with antihistamines, steroids, and histamine H<sub>2</sub> blocking agents is sometimes carried out in operating rooms, but anaphylactic reactions have occurred despite such pretreatment.

[Workers who are irritated by gloves should change the type of gloves worn or the type of soap used for scrubbing. In addition, the use of cotton liners and emollients may effectively prevent sensitivity reactions.](#)



In cases of true latex allergy, the avoidance of all latex products is the only measure that can avert a serious allergic reaction. All persons with latex hypersensitivity should carry an epinephrine autoinjection kit and wear MedicAlert identification. Acute systemic reactions to latex should be treated in the same manner as other anaphylactic reactions ( air-way and circulation assessment, administration of oxygen, and administration of epinephrine and steroids as needed).

In the course of resuscitation, all latex contact must be avoided.

## **Oral Allergy Syndrome**

Swelling of the lips, tongue and palate, and throat, along with oral pruritis and irritation, sometimes associated with other allergic clinical features including rhino-conjunctivitis, urticaria, and even anaphylaxis, has been termed the oral allergy syndrome. seems to be precipitated by fresh foods, including apples, in people who have been sensitized to cross-reacting allergens in pollens, particularly birch.

## **Immune Complex Diseases (Serum Sickness and Erythema Multiform)**

**Serum sickness** is named for its frequent occurrence after the administration of foreign serum, which was given for the treatment of infectious diseases before the advent of antibiotics. It is a type 3 immune complex-mediated disease. The reaction is now uncommon, but still occurs as a result of the susceptible patient being given tetanus antitoxin, rabies anti-serum, or drugs that combine with body proteins to form allergens.

The pathogenesis of serum sickness differs from that of anaphylaxis. Antibodies (usually IgG) form immunocomplexes in blood vessels with administered antigens.

The complexes fix complement, which damages vessels and attracts leukocytes to the area, amplifying direct tissue injury. Serum sickness and vasculitis usually begin 7–10 days after the administration of the allergen, but this period can vary from 3 days to as long as 1 month. **Unlike other allergic diseases, serum sickness may occur during the initial administration of the drug.**

**Major symptoms consist of** fever, swelling, lymphadenopathy, joint and muscle pains, and rash. Less common manifestations include peripheral neuritis, kidney disease, and myocardial ischemia.

Serum sickness is usually self-limiting, with spontaneous recovery in 1–3 weeks. Treatment is symptomatic; aspirin is given for arthralgia, and antihistamines are given for the skin rash. Severe cases should be treated with a short course of systemic corticosteroids, which significantly shortens the course of the disease. Although serum sickness is rare, the dentist who is prescribing penicillin should be aware of the possibility of its occurring days or weeks after use of the drug. It is thought that penicillin binds to host proteins to form a recognizable antigen and, as antibodies form, they meet across vessel walls and give a localized vasculitis.

**Oral erythema multiforme** is thought to be an immune complex disease where 7–10 days after a herpes simplex infection, IgG antibodies are formed and bind to remaining residual tissue-located herpes antigen, giving rise to localized inflammation and ulceration. Similar oral appearances can sometimes occur after systemic therapy with antihypertensive drugs.

## **Delayed Hypersensitivity: Oral Lichenoid**

### **Reactions:**

Cell-mediated damaging immune reactions **can occur in the oral cavity.** **Lichen planus** is thought to be a cell-mediated autoimmune reaction against basal epithelial cells.

Similarly, oral lichenoid reactions (OLRs) reflect cellular immunity to antigens found **in Graft-versus-host disease, dental restorations.** These are usually associated with contact sensitivity to amalgam fillings, **but similar OLRs can be found with drugs, gold, composite, or glass ionomer materials.** They are important to recognize, since there is increasing evidence of the malignant potential of such lesions. The lesions usually present as chronic, unilateral, mixed red and white lesions in direct proximity to a restoration, and histologically appear very similar to lichen planus with a predominantly lymphocytic infiltrate.

**The combination of history, clinical appearance, and histology usually leads to the diagnosis.** Damaging immune-mediated reactions, including cell-mediated, can also occur to many other dental materials, including dentifrices, toothpastes, and mouthwashes.

### **Systemic Autoimmune Diseases:**

#### **Systemic Lupus Erythematosus**

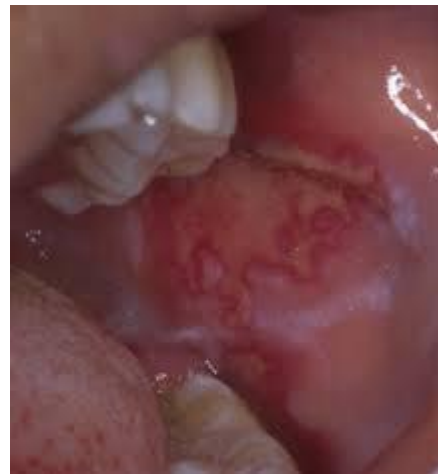LE represents the classic prototype of an autoimmune disease involving immune

complexes. Both the natural and the adaptive parts of the immune system. Environmental factors are of importance as sun exposure, drugs, chemical substances,

and hormones which all have been reported to aggravate the disease.

Impaired immune complex clearance by phagocytes is an important pathogenetic mechanism in systemic lupus erythematosus” The synthesis and secretion of pathogenic autoantibodies in SLE is driven by the interaction of CD4+ and CD8+ helper T cells, and double negative T cells (CD4– CD8–) with B cells

About 75% of the patients complain of oral symptoms e.g., dryness, soreness and a burning sensation especially when eating hot and spicy food. SLE is closely associated with excretory gland involvement. Thus, oral and ocular symptoms are frequent findings



**SLE characterized by oral ulcers and systemic signs like joint pain, nephritis**

**In lab investigation diagnosis confirm by taking blood sample**

**Anti-dsDNA marker is highly specific for lupus erythematosus**

In addition to CBC, ESR and C-Reactive Protein (CRP) and Urinalysis

**Differential Diagnosis are:**

**Oral Lichen Planus (OLP)**

**Leukoplakia lesions**