



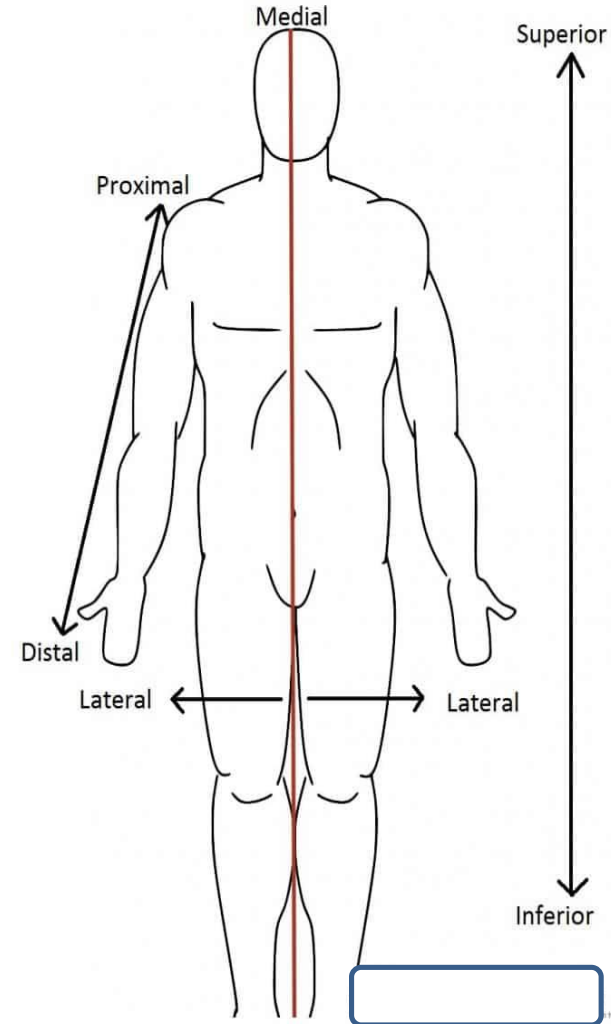
**AL MUSTAQBAL UNIVERSITY**

**College of Medicine / First Year**



**ANATOMY**

**(L4) Popliteal Region**



**Assist Prof. Dr. Abdulhusein Mizhir Almaamuri**

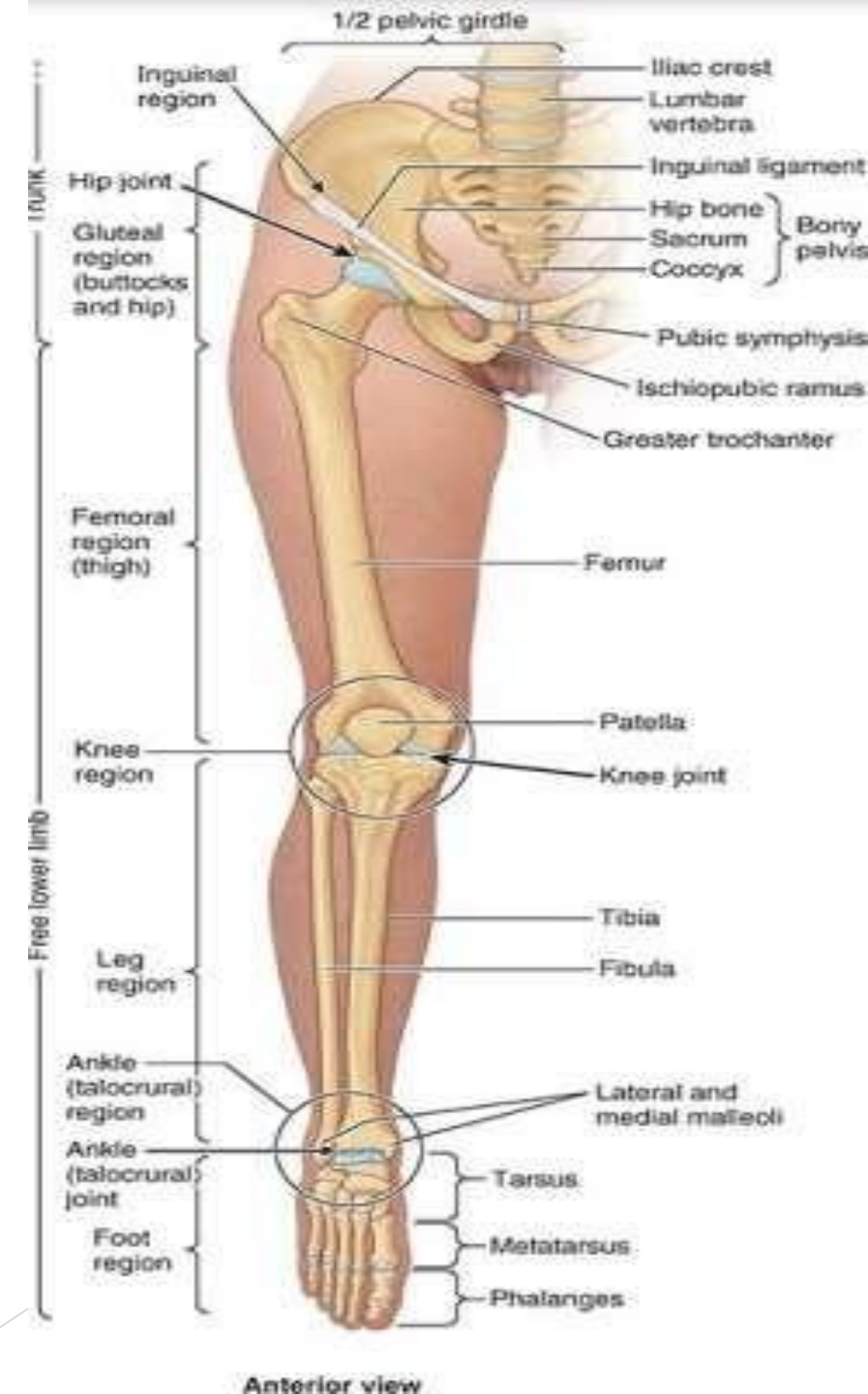# Learning Objectives

- **Define the boundaries** of the diamond-shaped popliteal fossa, including its superolateral, superomedial, inferolateral, and inferomedial borders.
- **Identify the floor (anterior wall) and roof** of the fossa, noting the specific muscles and fascial layers involved.
- **Describe the anatomical relationships** and depth of the primary neurovascular contents: the popliteal artery, popliteal vein, and tibial nerve.
- **Explain the functional importance of the popliteus muscle**, specifically its role in "unlocking" the knee joint during the commencement of flexion.
- **Trace the terminal branches of the sciatic nerve** (tibial and common fibular nerves) and their courses through and out of the fossa.
- **Discuss the clinical significance** of popliteal aneurysms, Baker's cysts, and the vulnerability of the common fibular nerve at the neck of the fibula

# Regions of lower limb

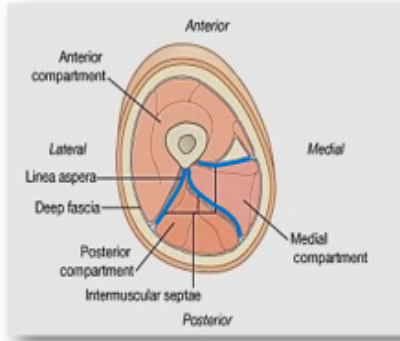
## The lower limbs have six major regions

- ❑ **The gluteal region:** transitional region between the trunk and free lower limbs.
- ✓ **the buttocks**
- ✓ **hip region** overlies the hip joint and greater trochanter
- ❑ **The femoral region (thigh).** The transition from trunk to free lower limb occurs abruptly in the inguinal region or groin.
- ❑ **The popliteal fossa (The knee region)**
- ✓ condyles of the distal femur and proximal tibia,
- ✓ the head of the fibula
- ✓ the patella
- ✓ the joints between these bony structures.
- ❑ **The leg region** includes most of the tibia and fibula
- ❑ **The ankle** includes the medial and lateral malleoli that flank the ankle joint.
- ❑ **The foot region** containing the tarsus, metatarsus, and phalanges



# Thigh compartments

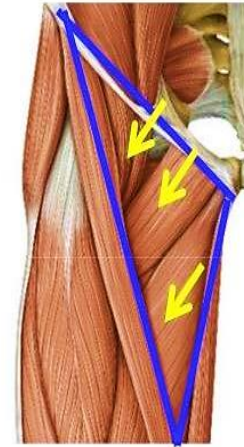
The thigh is divided into three compartments by intermuscular septa between the posterior aspect of the femur and the fascia lata:



- a) Anterior compartment (extensor)
- b) Posterior compartment (flexor)
- c) Medial compartment (adductor)

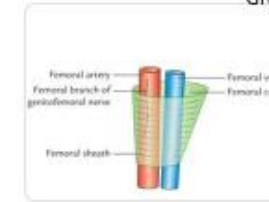
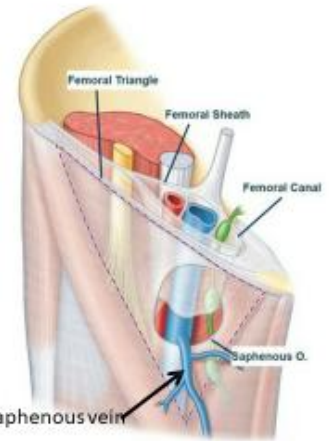
# Femoral Triangle

- **Site:**
  - **Triangular depressed area**
  - **At the upper part of the medial aspect of the thigh**
- **Boundaries:**
  - **Superiorly: The inguinal ligament**
  - **Laterally: The sartorius muscle**
  - **Medially: The adductor longus muscle**
- **Floor:**
  - **Iliopsoas**
  - **Pectineus**
  - **Adductor longus**



# Femoral sheath

- Is a downward protrusion of the fascia lining the anterior and posterior abdominal walls into the thigh
- Extends 2.5 cm below the inguinal ligament
- Superiorly it is open into the abdominal cavity
- Inferiorly it is closed by blending with the walls of the vessels that pass through it



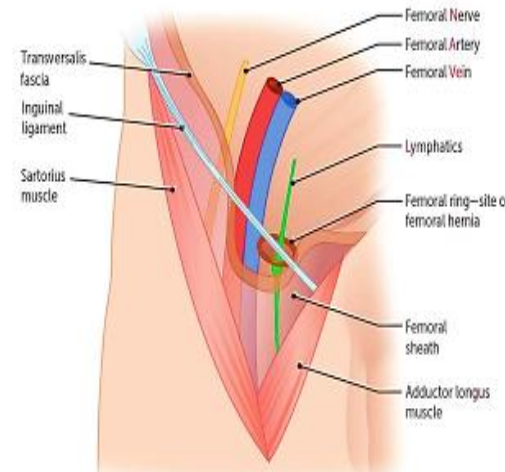
Note 'femoral sheath' does NOT cover the femoral nerve, otherwise from medial to lateral (\*) NAV...  
Femoral canal contains "Lymph node of Cloquet"

# Femoral canal

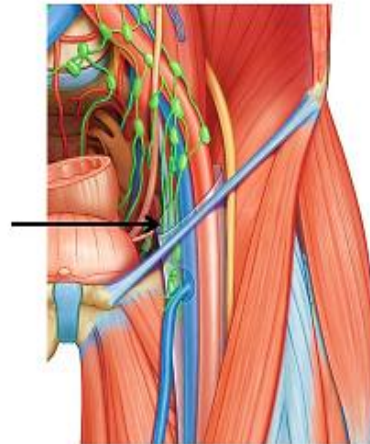
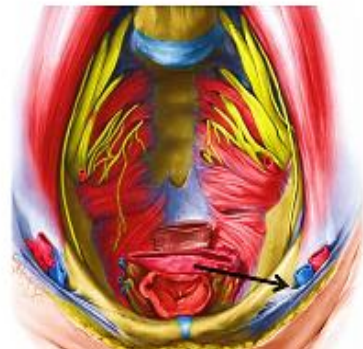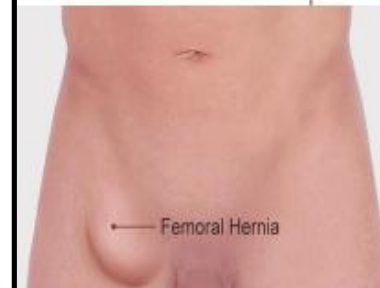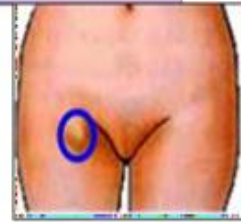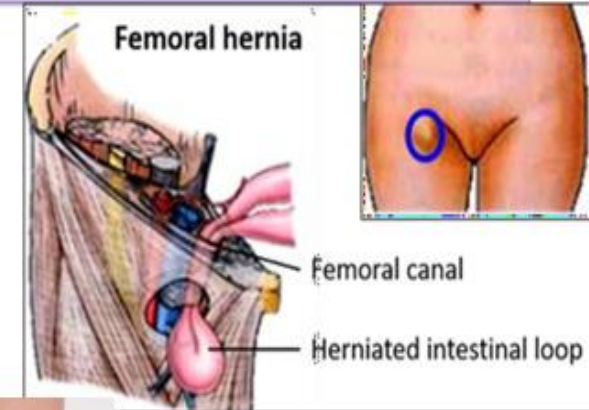
- It contains fat, lymph vessels and one of the deep inguinal lymph nodes
- Its upper end (the femoral ring) communicate with the abdominal cavity
- Its lower end is closed

# Femoral ring is bounded by:

1. Inguinal Ligament (Anteriorly)
2. Lacunar Ligament (Medially)
3. Superior Ramus of Pubis (Posteriorly)
4. Femoral Vein (Laterally)



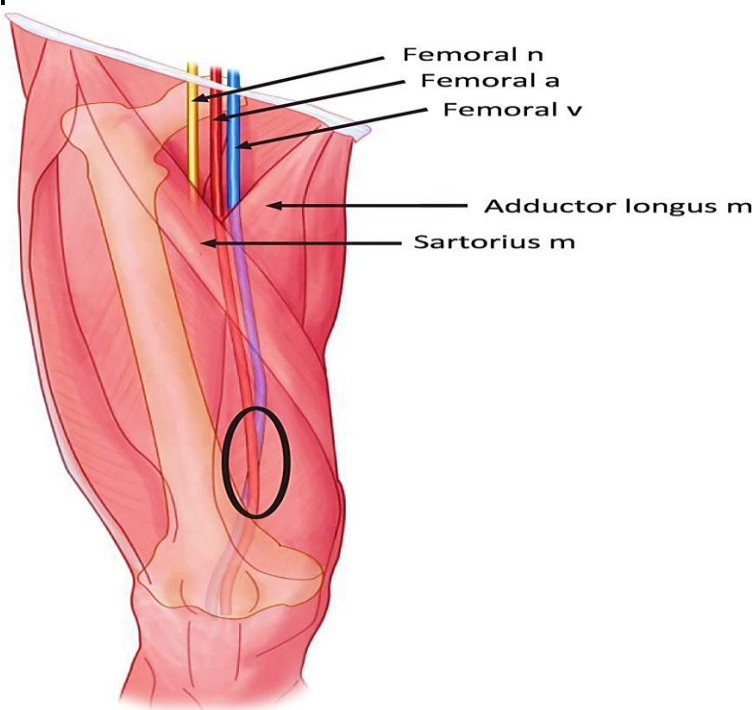
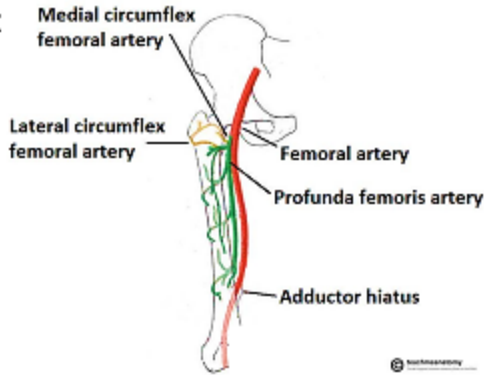
# Femoral hernia



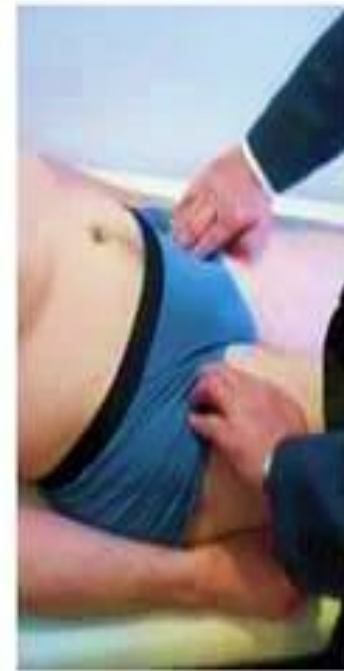# Femoral artery

A continuation of the external iliac artery

- Acquire its name as it passes under the inguinal ligament
- Within lateral compartment of femoral sheath
- Run with the femoral vein



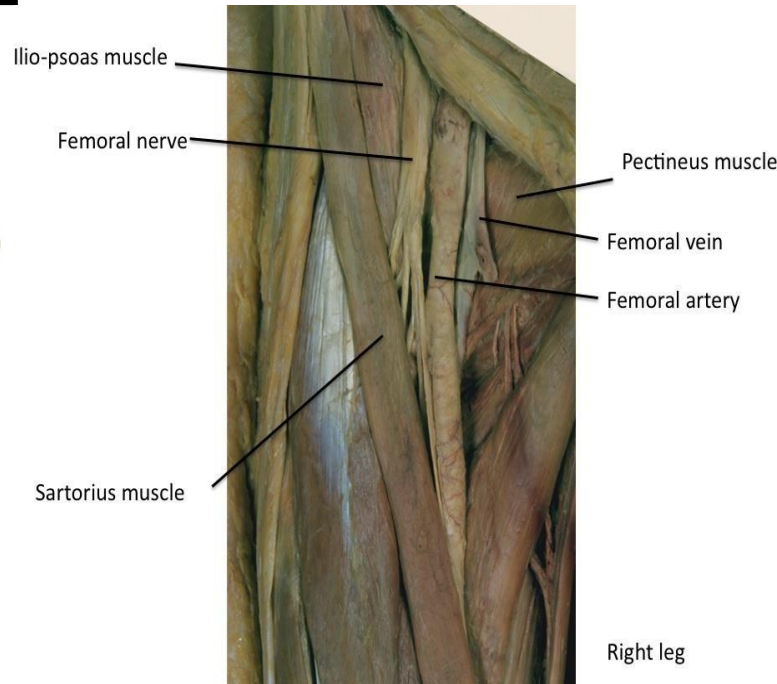
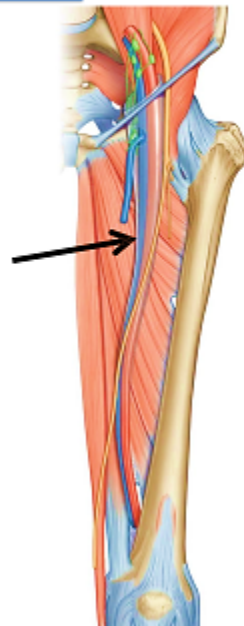
- The femoral pulse can be palpated in the femoral triangle, 2 to 3 cm inferior to the midpoint of the inguinal ligament.
- The head of the femur lies posterior to the femoral artery at this site, making compression of the vessel easy.



# Femoral vein

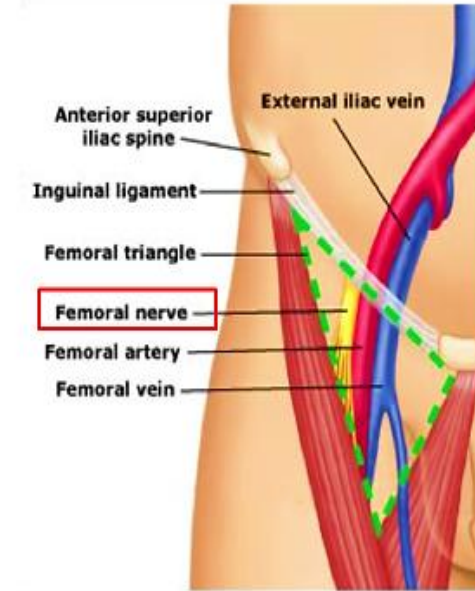
Starts as a continuation of the popliteal veins

- Ascends up covered by Sartorius muscle then enters the femoral triangle
- Pass through the femoral sheath medial to the femoral artery
- Pass under the inguinal ligament to continue as the external iliac vein



# Femoral nerve

- Enters the thigh midway between ASIS and pubic tubercle, lateral to femoral artery
- Take a short course then divides into terminal branches
- Entering the thigh deep to inguinal ligament between the iliacus and psoas muscles



## Adductor compartment

## Medial Fascial Compartment

- Lies on the medial aspect of the thigh

- Contains 6 muscles

- They **attach proximally** to

the **anteroinferior external surface of the bony pelvis**

- ✓ pubic bone,

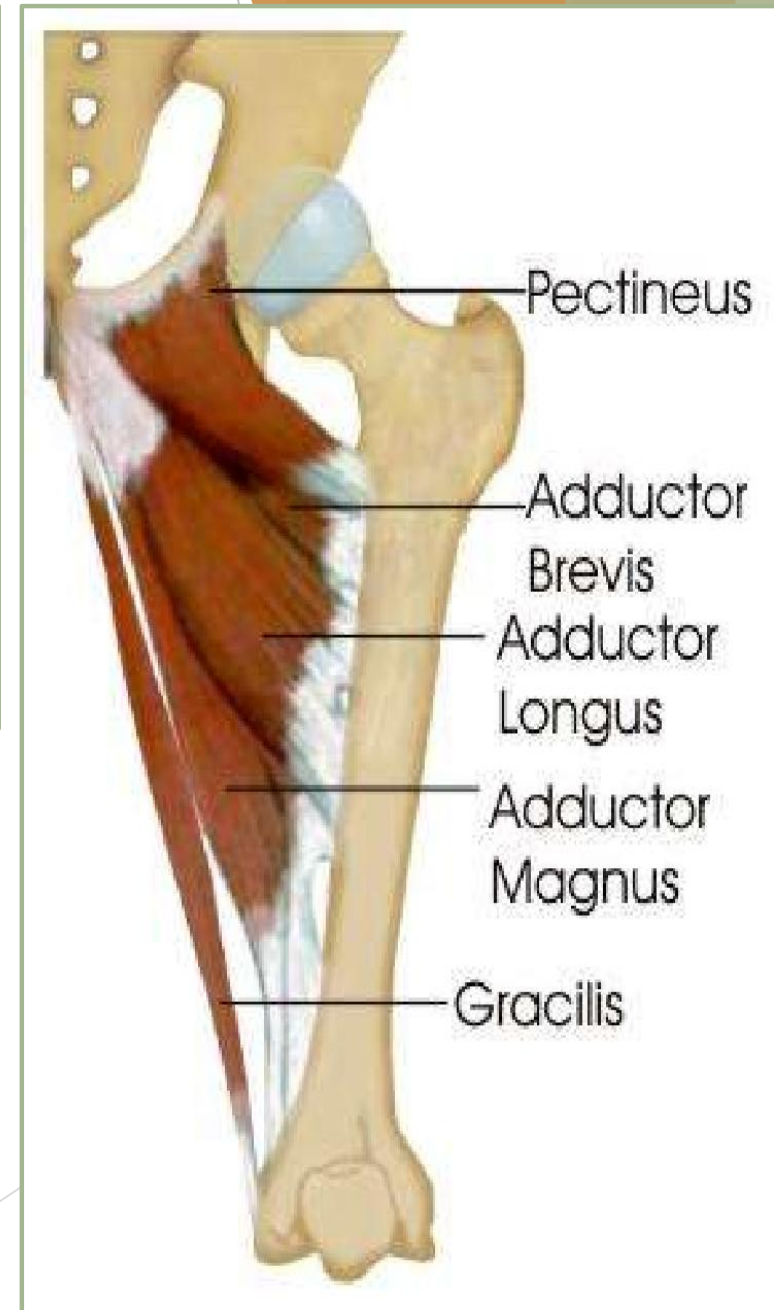
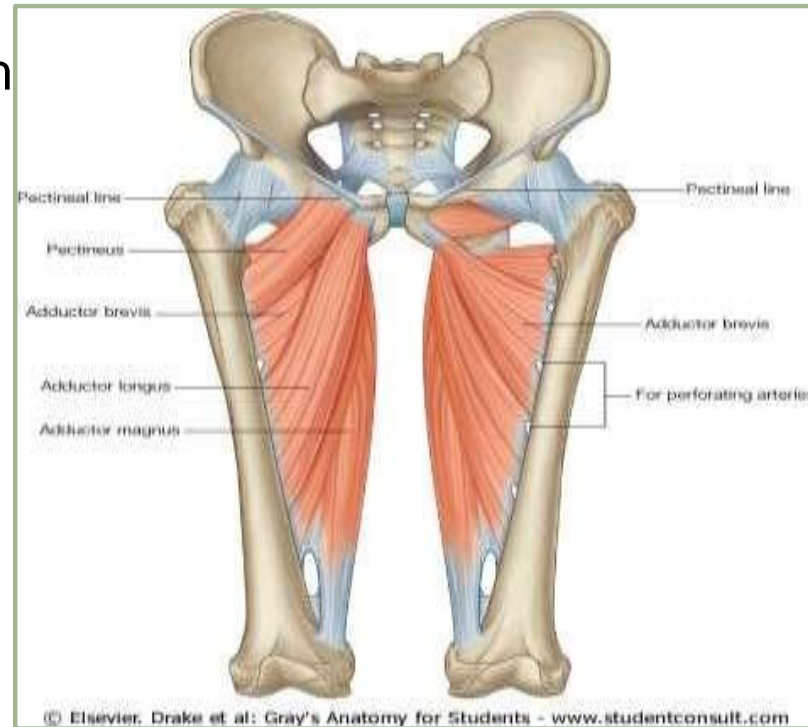- ✓ ischiopubic ramus,

- ✓ ischial tuberosity

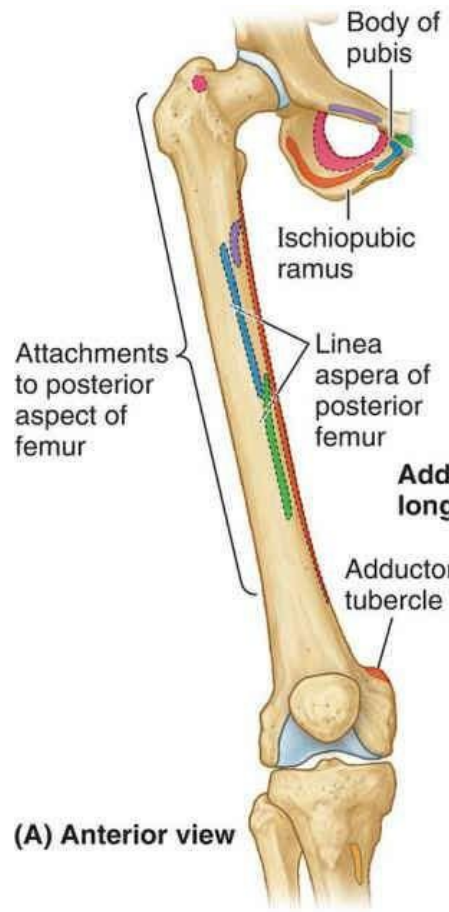
- ✓ adjacent obturator membrane,

- They **attach distally** to the linea aspera of the femur

- The obturator vessels & nerve supply this compartment

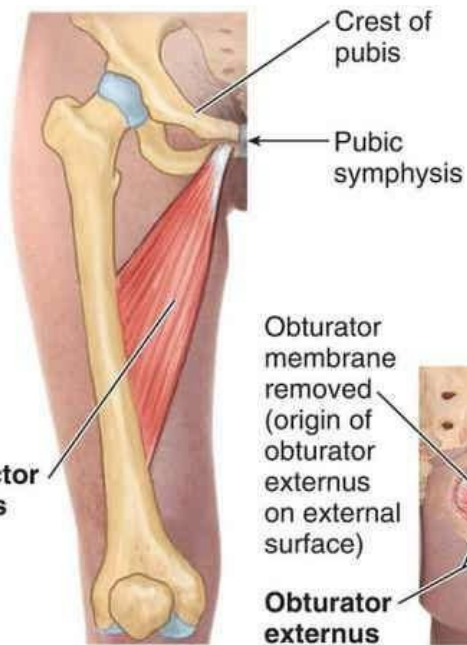


# Adductor compartment

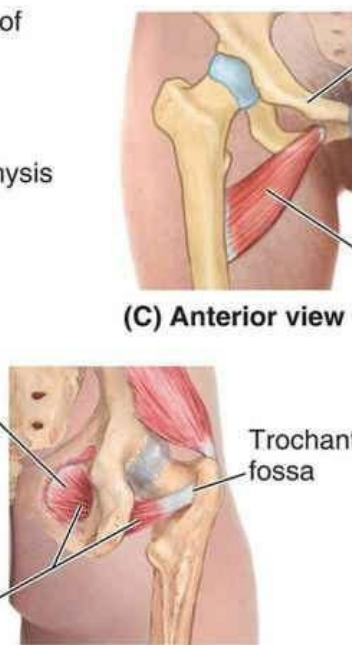

(A) Anterior view

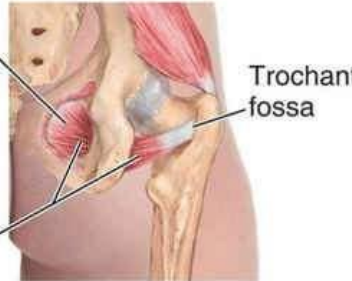Attachments	
<span style="color: green;">■</span>	Adductor longus
<span style="color: blue;">■</span>	Adductor brevis
<span style="color: orange;">■</span>	Adductor magnus
<span style="color: yellow;">■</span>	Gracilis
<span style="color: pink;">■</span>	Obturator externus
<span style="color: purple;">■</span>	Pectineus



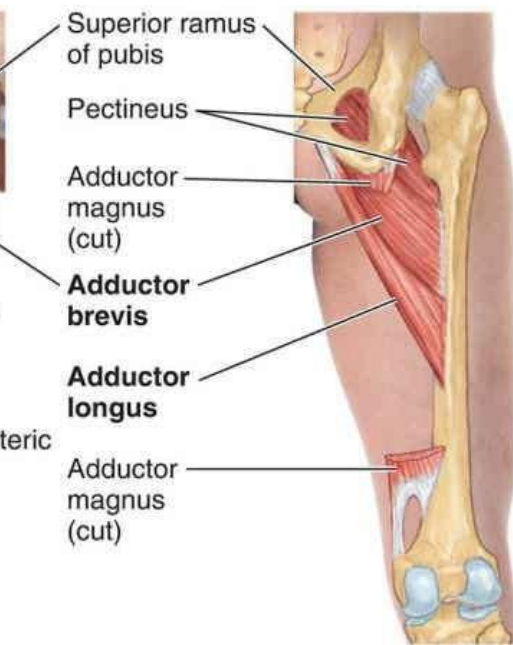(B) Anterior view



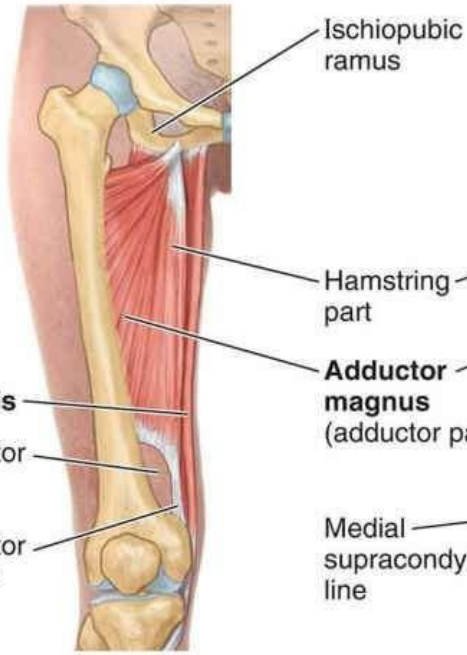
(C) Anterior view



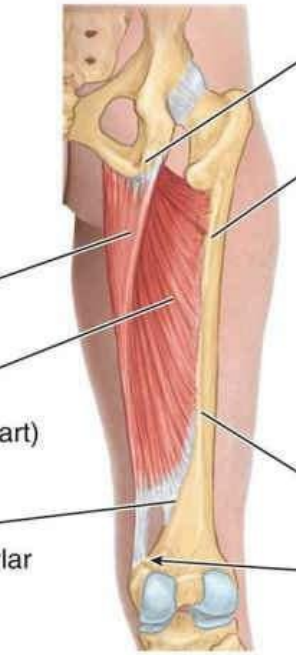
(H) Anterior view



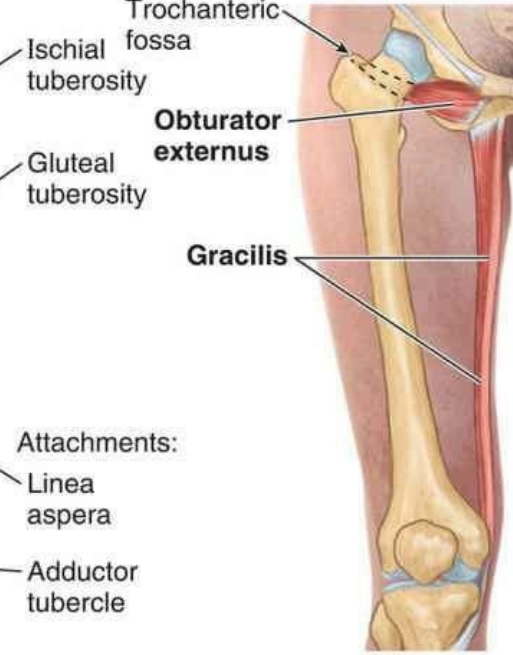(D) Posterior view



(E) Anterior view



(F) Posterior view



(G) Anterior view

**Muscles:** Gracilis, adductor longus, adductor brevis, adductor magnus, and obturator externus

**Blood supply:** Profunda femoris artery and obturator artery

**Nerve supply:** Obturator nerve

Adductor Muscles	Origin	Insertion	N Supply	Action		
Adductor longus	Body of pubis	Middle third of linea aspera of femur	Obturator nerve (anterior division) <b>L2,3,4</b>	Adductor & medial rotator of hip		
Adductor brevis	Body & inferior ramus of pubis	Pectineal line and proximal part of linea aspera of femur		Hip adductor		
Gracilis	Body & inferior ramus of pubis	medial surface of upper tibia		<ul style="list-style-type: none"> <li>✓ Hip adductor</li> <li>✓ Knee flexor</li> </ul>		
Obturator Externus	External surface of obturator membrane and adjacent bone	Trochanteric fossa		<ul style="list-style-type: none"> <li>✓ Laterally rotates thigh;</li> <li>✓ steadies head of femur in acetabulum</li> </ul>		
Adductor magnus Adductor part	<ul style="list-style-type: none"> <li>✓ inferior ramus of pubis,</li> <li>✓ Ramus of ischium</li> </ul>	gluteal tuberosity, linea aspera, medial supracondylar line		Adducts thigh	flexes thigh,	
Adductor magnus Hamstring part:	Ischial tuberosity	adductor tubercle of femur			tibial part of sciatic nerve (L4)	Extends thigh

Note that the **adductor magnus** is a large, triangular muscle consisting of **upper adductor** and **lower hamstring** portions. **The obturator nerve** innervates the adductor portion, whereas **the tibial nerve** supplies the hamstring portion. This dual neural organization reflects the separate developmental origins of the two parts. **The adductor hiatus** is a gap in the attachment of this muscle to the femur, which permits the femoral vessels to pass from the adductor canal downward into the popliteal space.

### **Medial Fascial Compartment Blood Supply**

**The profunda femoris** and **obturator vessels** are the vascular channels for the medial compartment of the thigh. The profunda vessels are related to the **femoral artery and vein** and the obturator vessels to **the internal iliac artery and vein**.

### **Profunda Femoris Artery**

The profunda femoris is a large artery that arises from the lateral side of the femoral artery in the femoral triangle, about 1.5 in. (4 cm) below the inguinal ligament. It descends in the interval between the adductor longus and adductor brevis and then lies on the adductor magnus, where it ends as the **fourth perforating artery**.

## **Branches**

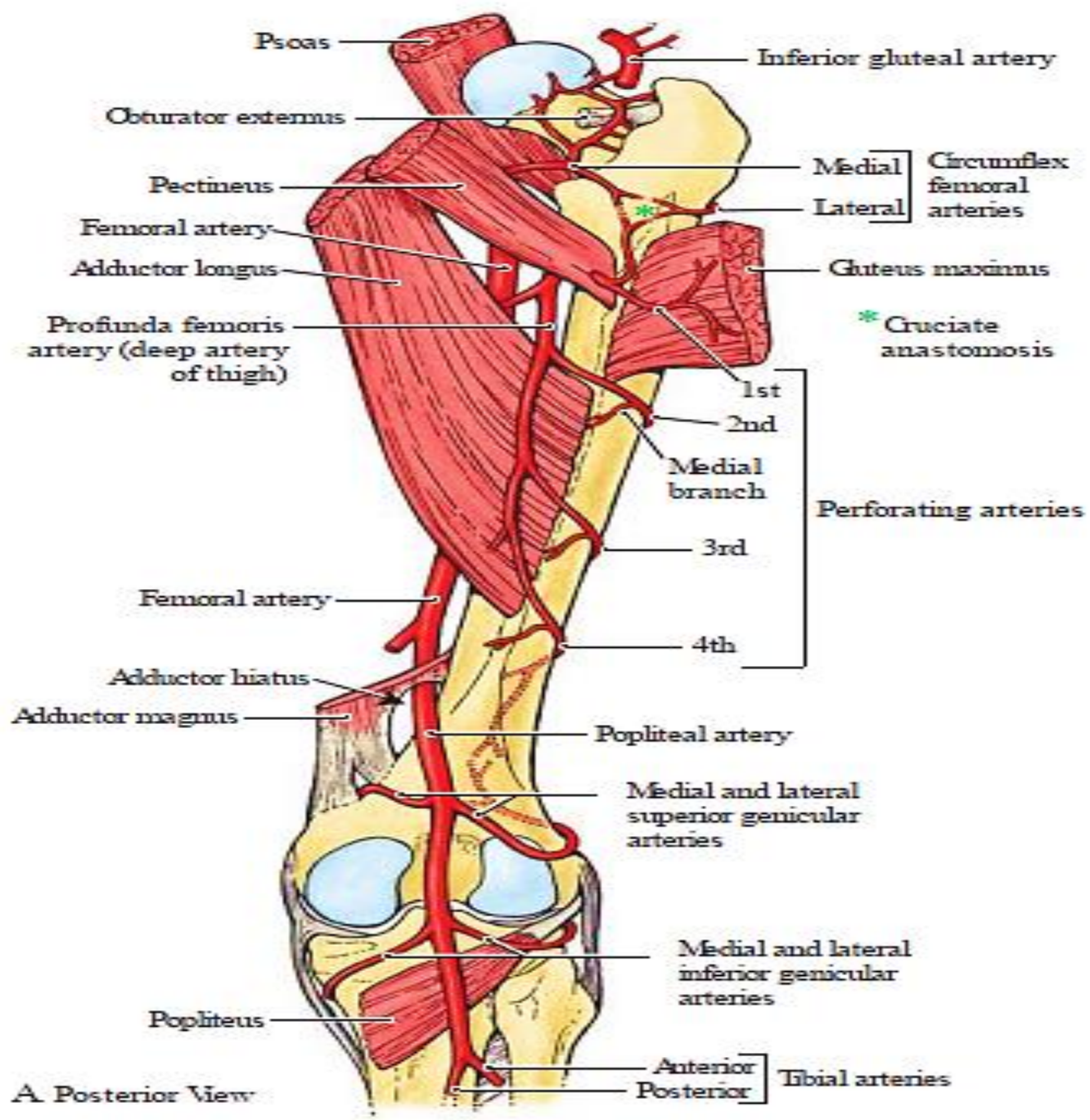
**Medial femoral circumflex artery:** This passes backward between the muscles that form the floor of the femoral triangle and gives off muscular branches in the medial fascial compartment of the thigh. It takes part in the formation of the cruciate anastomosis.

**Lateral femoral circumflex artery:** This passes laterally between the terminal branches of the femoral nerve. It breaks up into branches that supply the muscles of the region and takes part in the formation of the cruciate anastomosis.

**Four perforating arteries:** Three of these arise as branches of the profunda femoris artery. The fourth perforating artery is the terminal part of the profunda femoris artery. The perforating arteries run backward, piercing the various muscle layers as they go. They supply the muscles and terminate by anastomosing with one another and with the inferior gluteal artery and the circumflex femoral arteries above and the muscular branches of the popliteal artery below.

## **Profunda Femoris Vein**

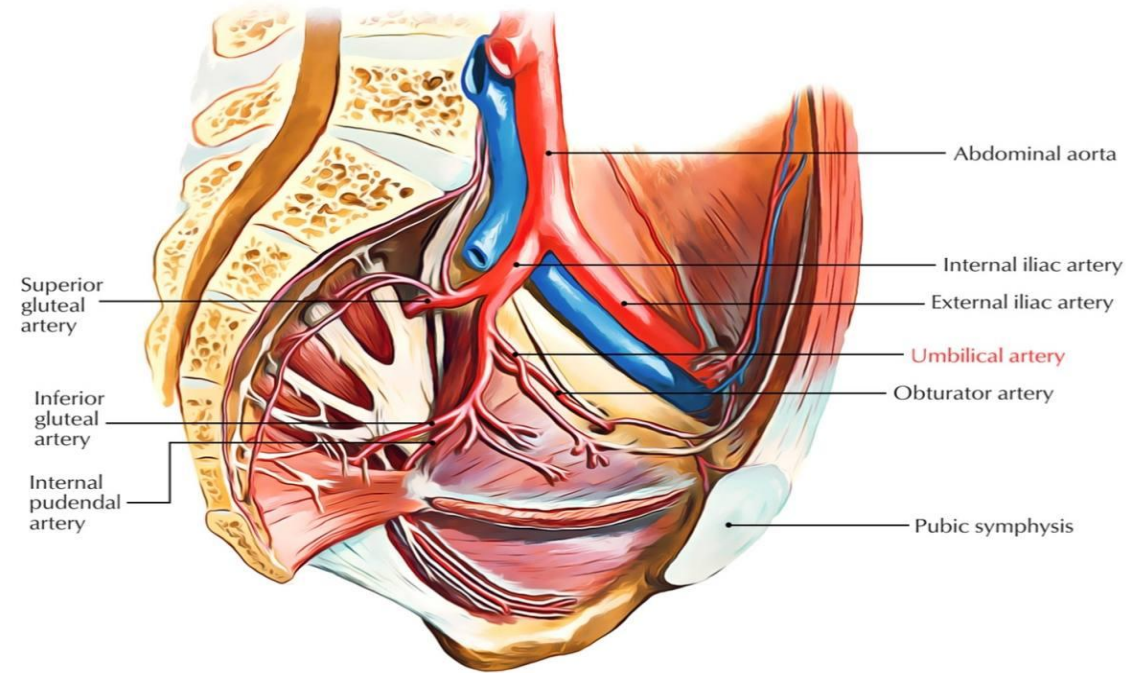
The profunda femoris vein receives tributaries that correspond to the branches of the artery. It drains into the femoral vein in the femoral triangle.



A. Posterior View

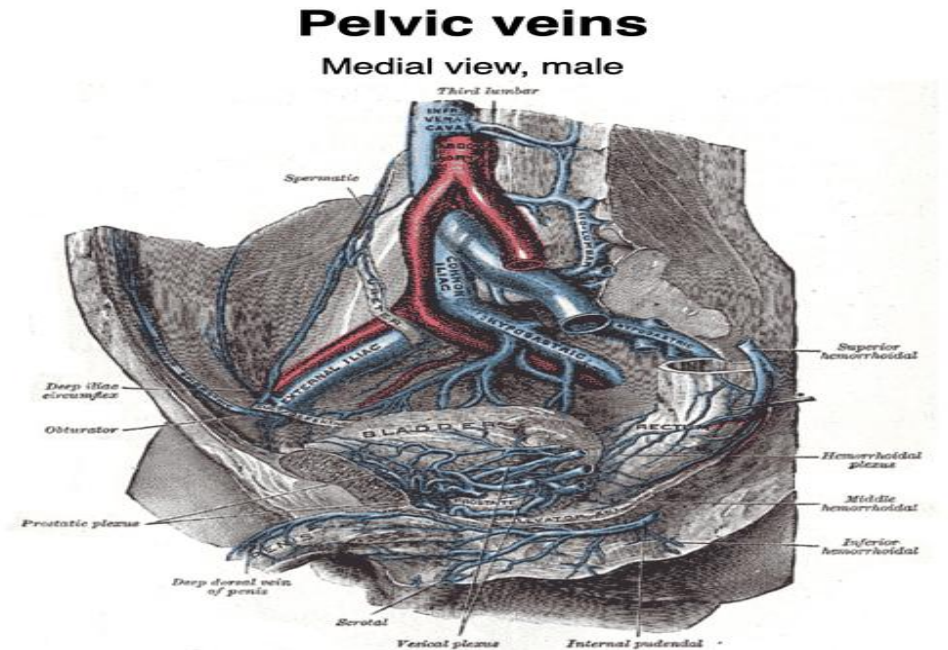
## Obturator Artery

The obturator artery is a branch of the **internal iliac artery**. It passes forward on the lateral wall of the pelvis and accompanies the obturator nerve through the obturator canal (i.e., the upper part of the obturator foramen). On entering the medial fascial compartment of the thigh, it divides into medial and lateral branches, which pass around the margin of the outer surface of the obturator membrane. It gives off muscular branches and an articular branch to the hip joint.



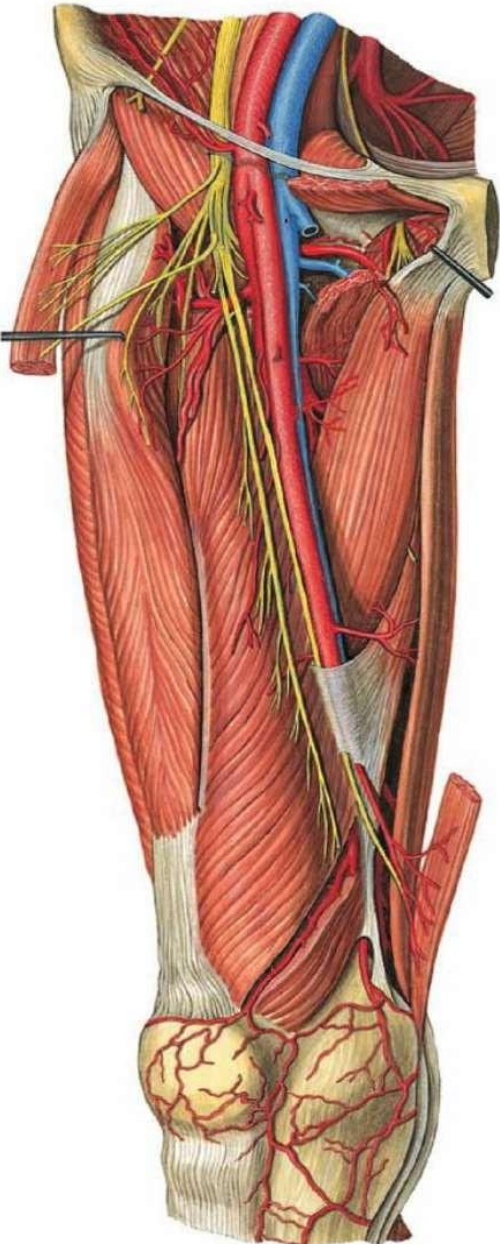
## Obturator Vein

The obturator vein receives tributaries that correspond to the branches of the artery. It drains into the internal iliac vein.



# Neurovascular Structures in anteromedial thigh

## Femoral artery

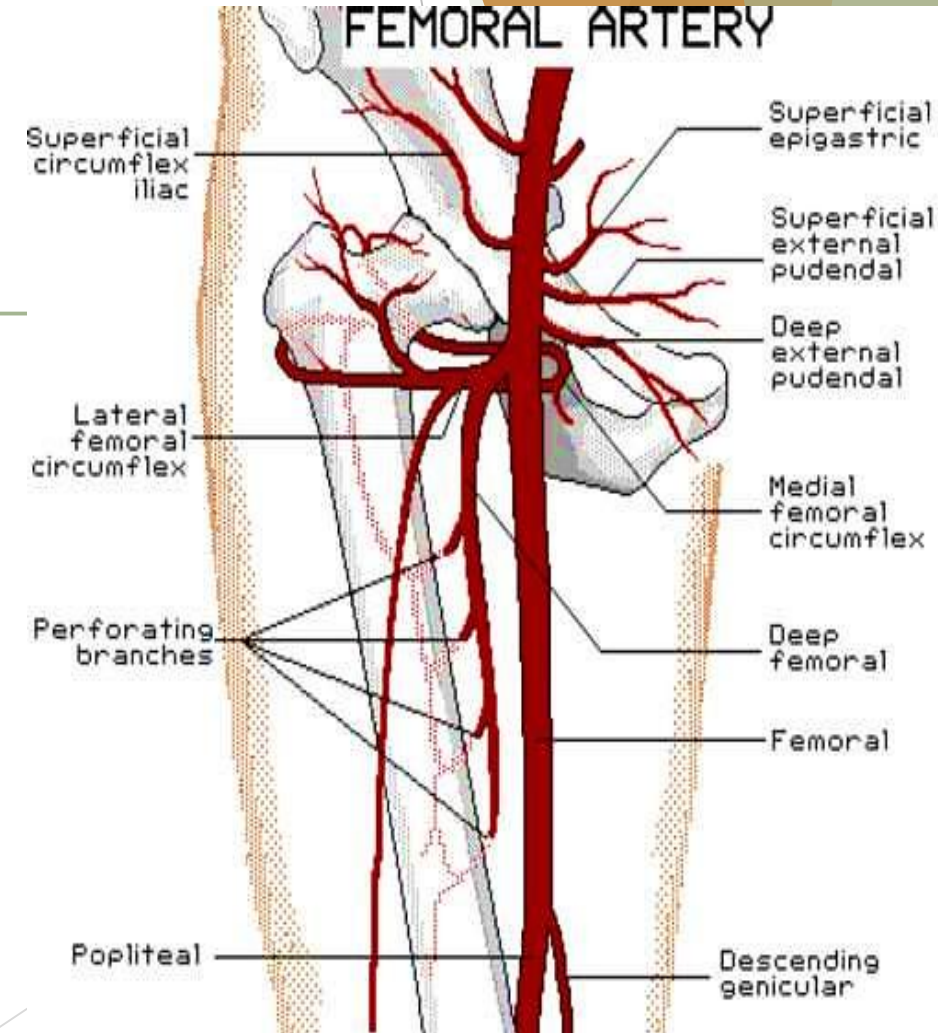
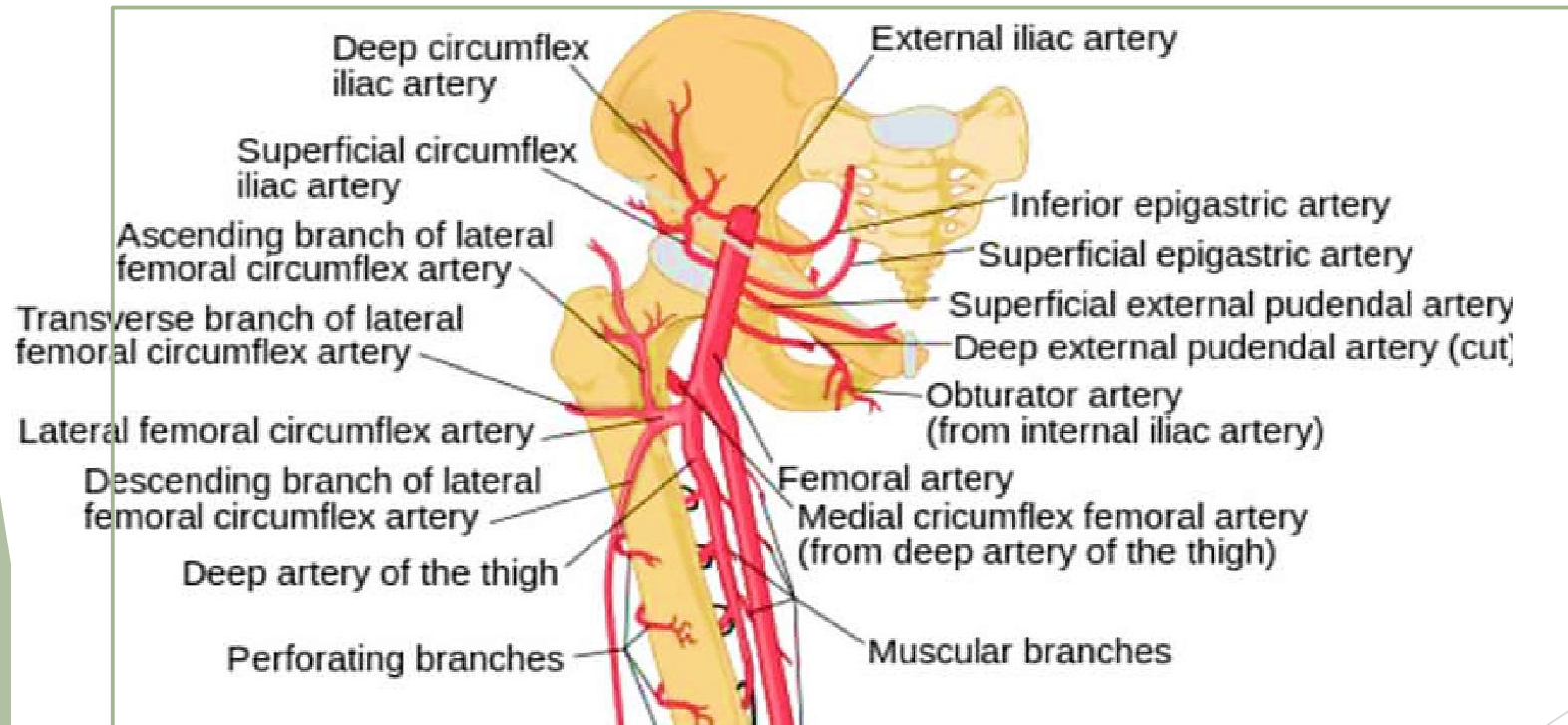


- It is the **continuation of the external iliac artery** distal to the inguinal ligament.
- It enters the **femoral triangle** deep to the inguinal ligament midway between the ASIS and the pubic symphysis (**mid-inguinal point**).
- Here it lies on the **psoas major tendon**, which separates the artery from the capsule of the hip joint. This is the position where
  - ✓ its pulsation can be felt
  - ✓ it can be entered for arterial catheterization.
- passes in the lateral component of the **femoral sheath** between femoral vein & nerve
- courses downwards and enters the **adductor canal**
- Leaves the canal by passing through the **adductor hiatus**, where it appears in the **popliteal fossa** as the **popliteal artery**

# Branches in the thigh

1 Superficial branches, given from the proximal part:

- A. **Superficial** (and sometimes the deep) **circumflex iliac**; to the ASIS.
- B. **Superficial epigastric**; to the anterior abdominal wall
- C. **Superficial external pudendal**; to external genitalia
- D. **Deep external pudendal**; to external genitalia

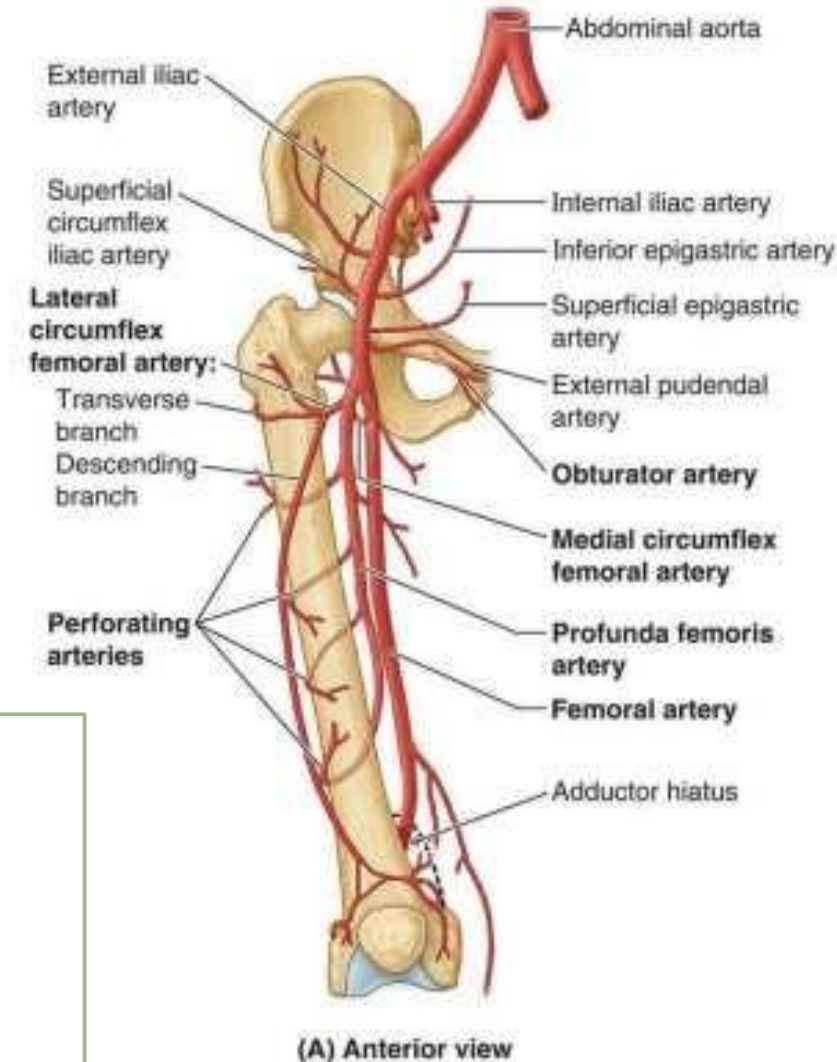


## 2- Profunda femoris artery (deep artery of the thigh):

- ❑ The largest branch of femoral artery, arises from its lateral side of femoral artery **3-4 cm** distal to inguinal ligament then spirals down deep to it, **passing between pectineus and adductor longus**
- ❑ It continues down on adductor brevis and magnus and ends as the 4<sup>th</sup> perforating artery.
- ❑ In the middle third of the thigh, it is separated from the femoral artery and vein by the adductor longus

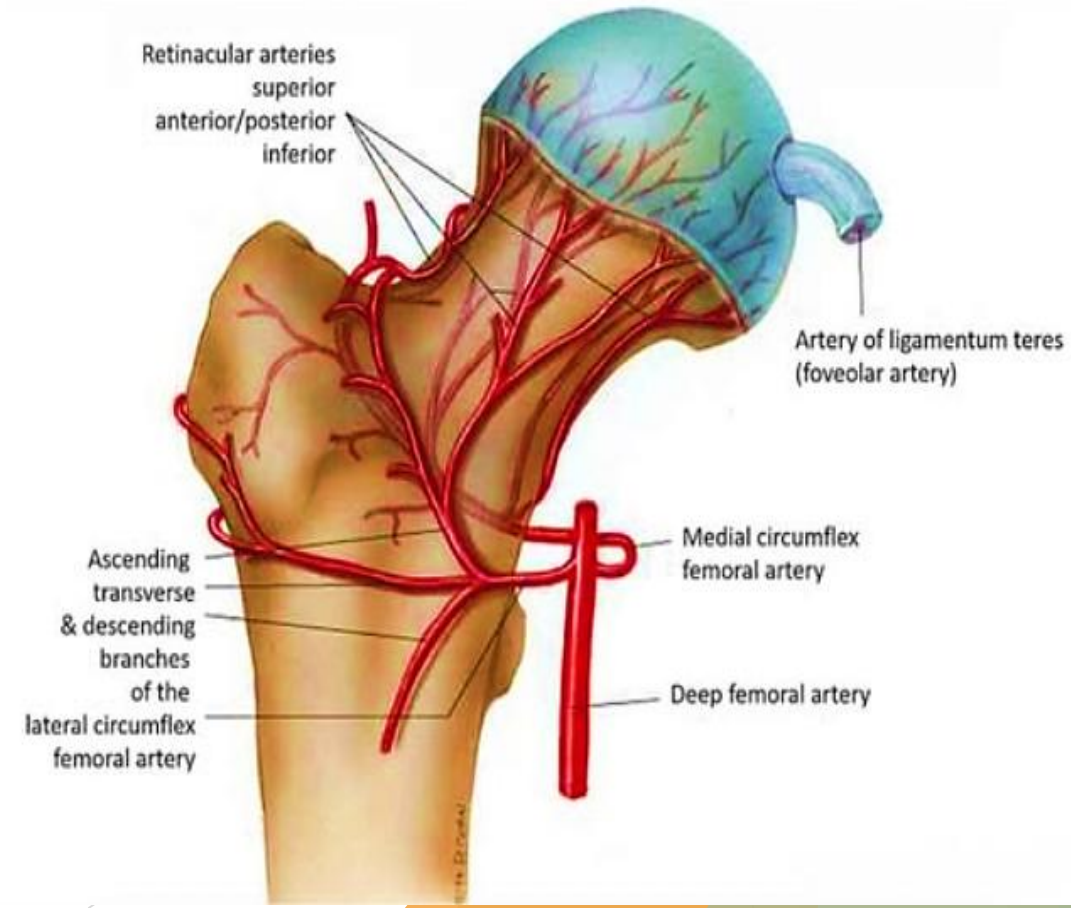
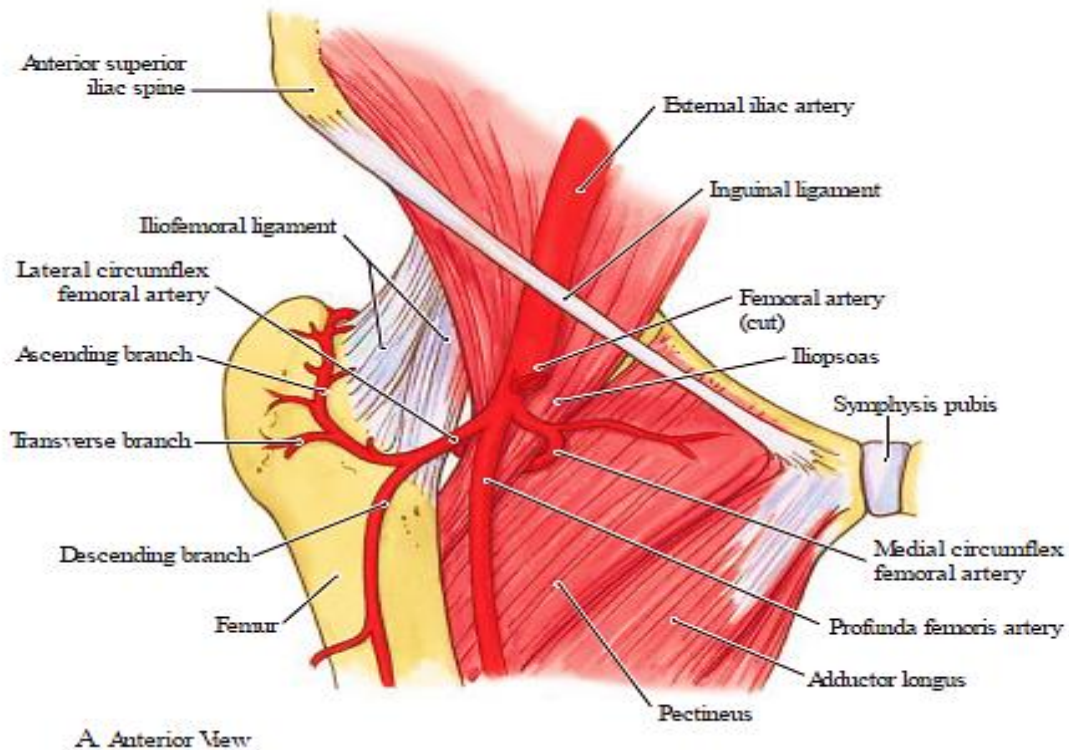
### **Branches;**

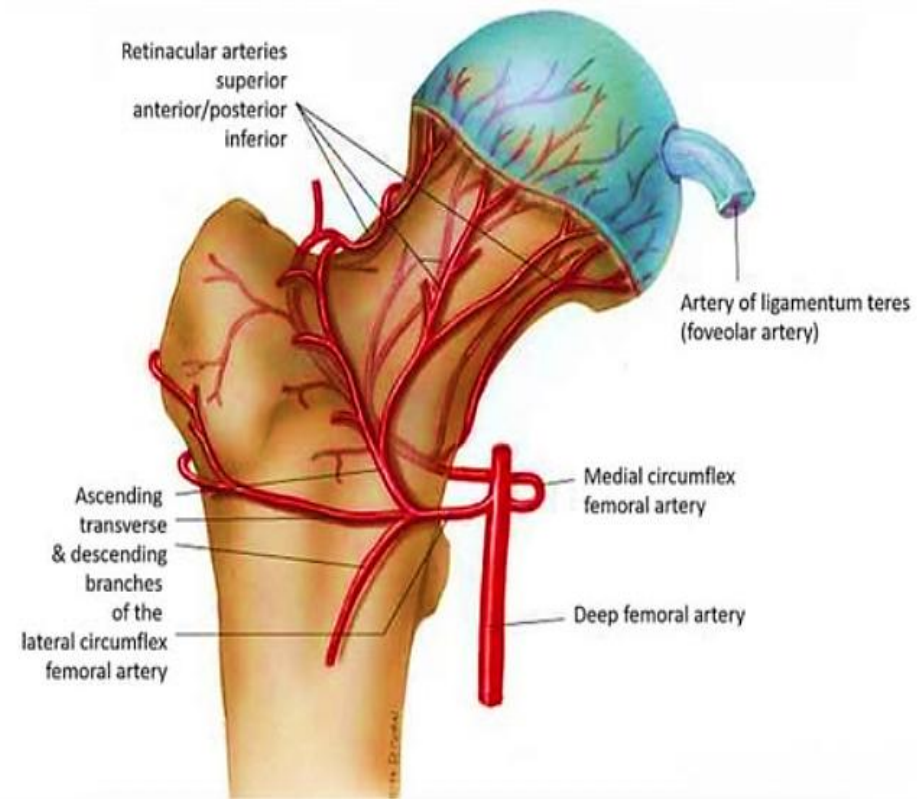
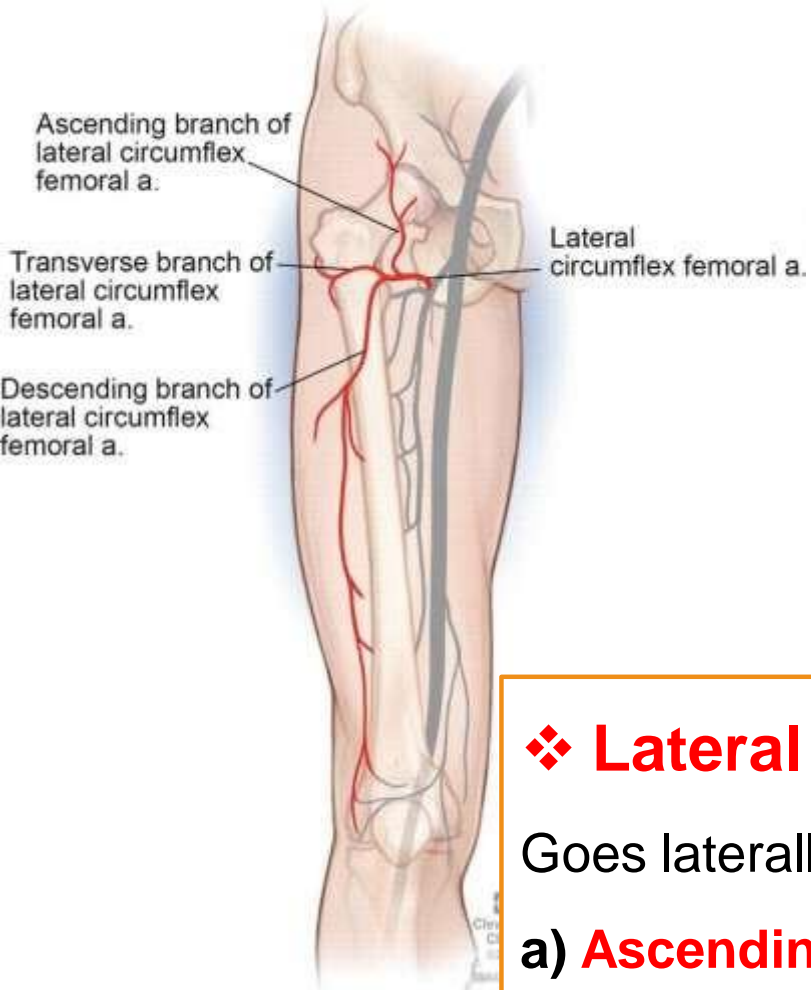
- 1 Medial circumflex femoral a.
- 2 Lateral circumflex femoral a.
- 3 Muscular arteries
- 4 Four perforating arteries, the 4th is the continuation of the profunda



## ❖ Medial circumflex femoral artery:

- ❑ Arises from the medial side of profunda
- ❑ Enters between pectineus & psoas to reach the gluteal region & Gives rise to **posterior retinacular arteries** which supplies most of the blood to the head and neck of the femur.
- ❑ Ends by dividing into **ascending & transverse branches**, the former goes to the trochanteric while the latter to the cruciate anastomoses





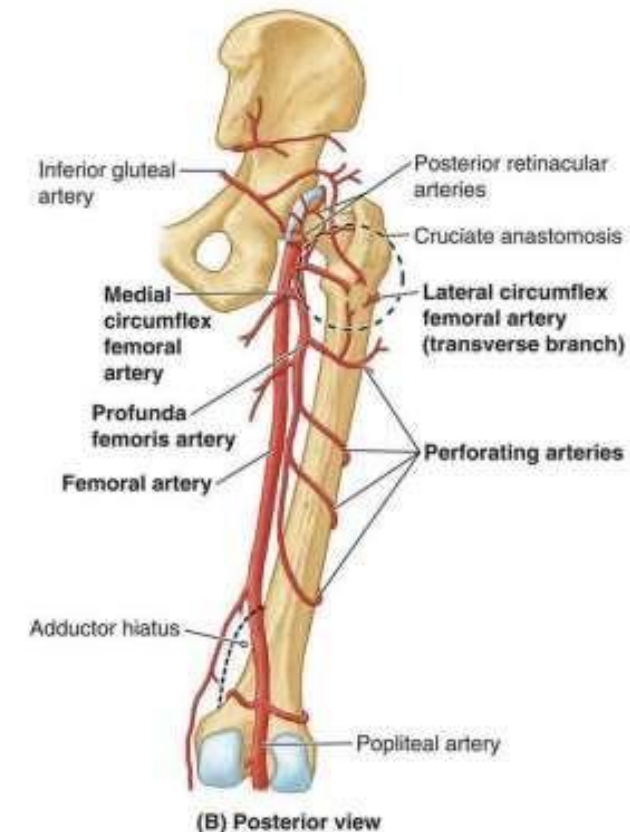
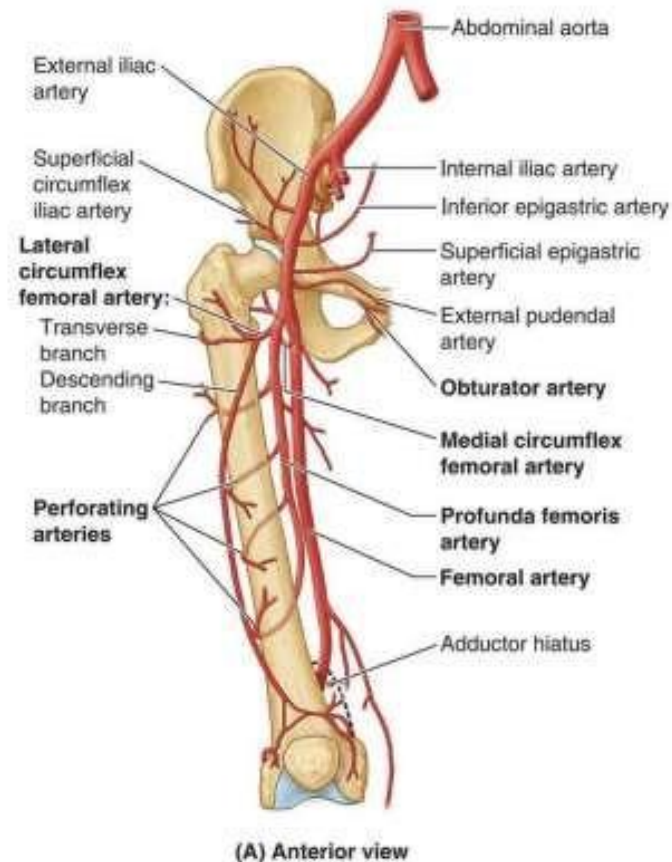
## ❖ Lateral circumflex femoral artery:

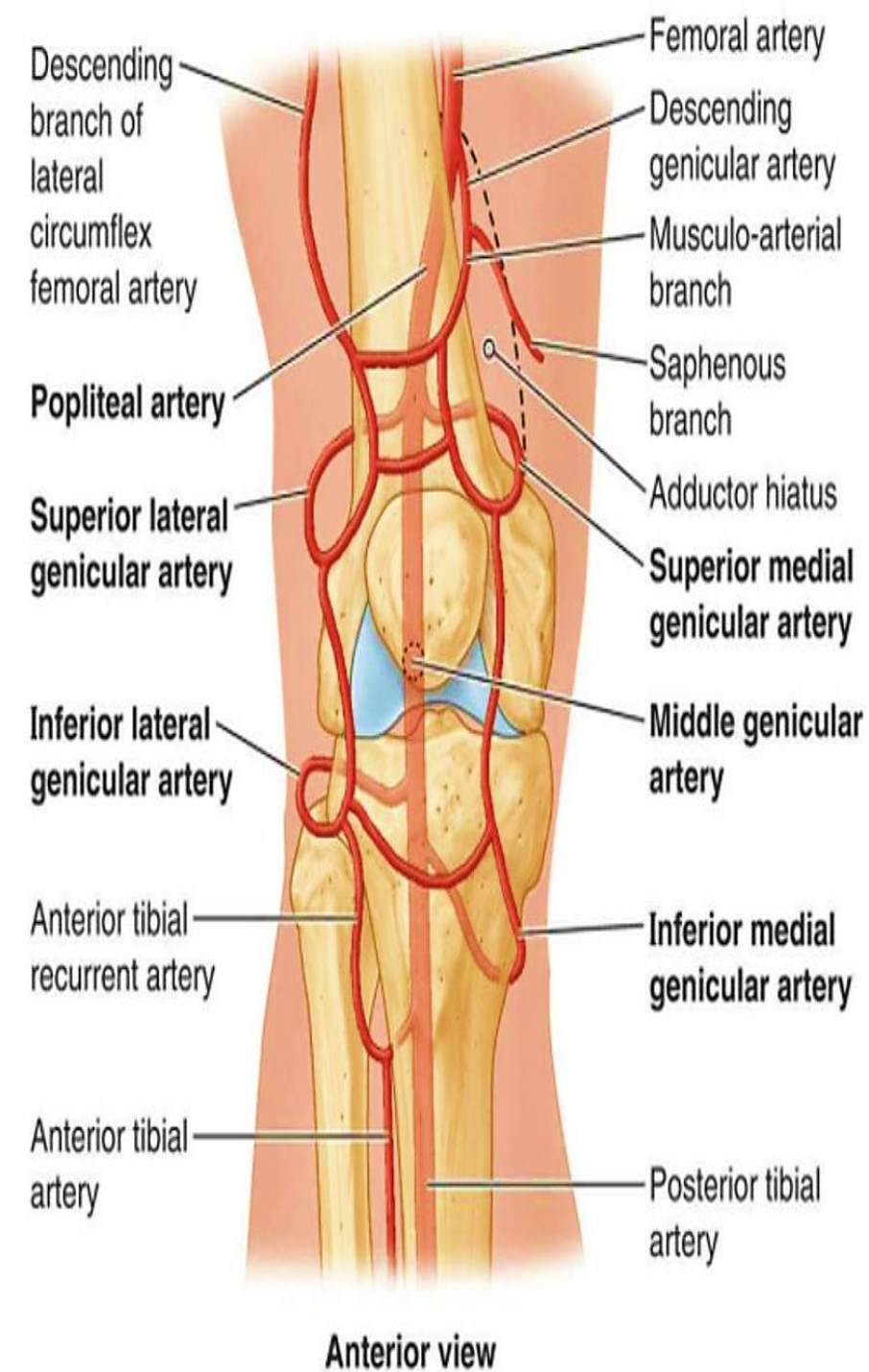
Goes laterally deep to sartorius & rectus muscles to divide into:

- a) **Ascending branch** to the anastomosis around ASIS & share in the trochanteric anastomosis
- b) **Transverse branch** to the cruciate anastomosis
- c) **Descending branch**; accompanies nerve to V. lateralis & descends down to anastomose with arteries around the knee

## ❖ Perforating arteries:

- 4 in number, the upper 2 pass through adductor brevis
- wrap around the posterior aspect of the femur and supply the adductor magnus, hamstring, and vastus lateralis muscles.
- So named because they perforate adductor magnus to reach the hamstring compartment
- They have circular course around the shaft of femur
- The arteries anastomose with each other
- P1 shares in the cruciate anastomosis
- P4 shares in the knee anastomosis





### 3- Descending genicular artery

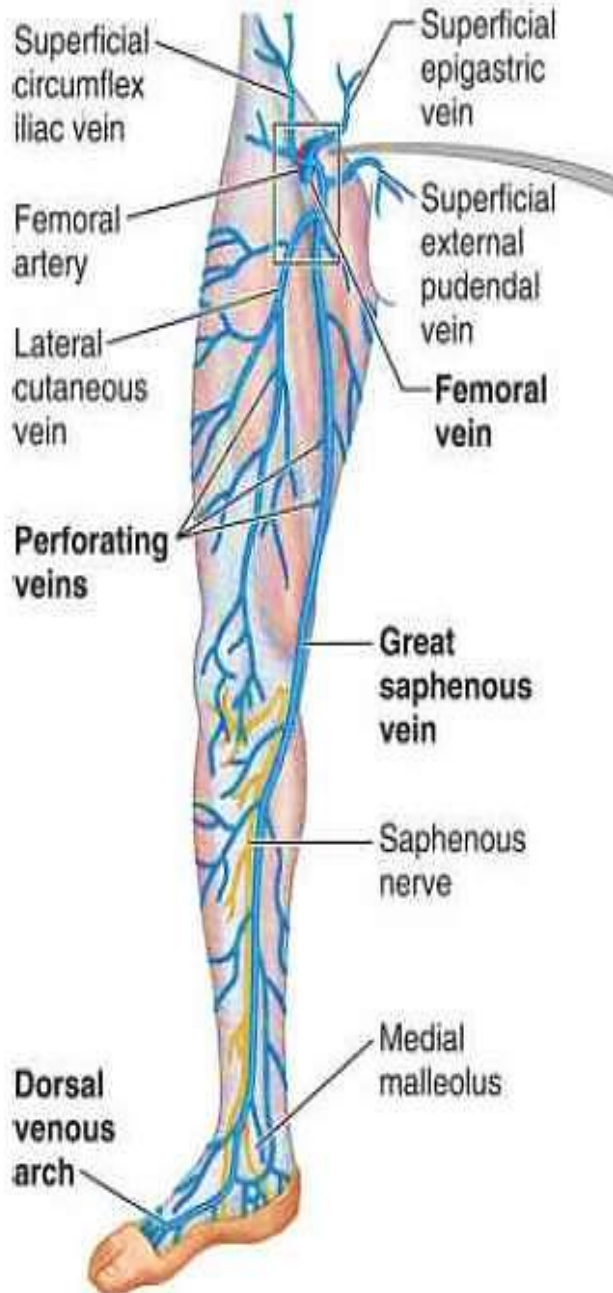
- ❑ Given before the femoral a. enters the adductor hiatus
- ❑ Divides into saphenous & genicular branches
- ✓ **Saphenous a.** accompanies the saphenous nerve
- ✓ **Genicular a.** share in the anastomosis around the knee joint

# Femoral vein

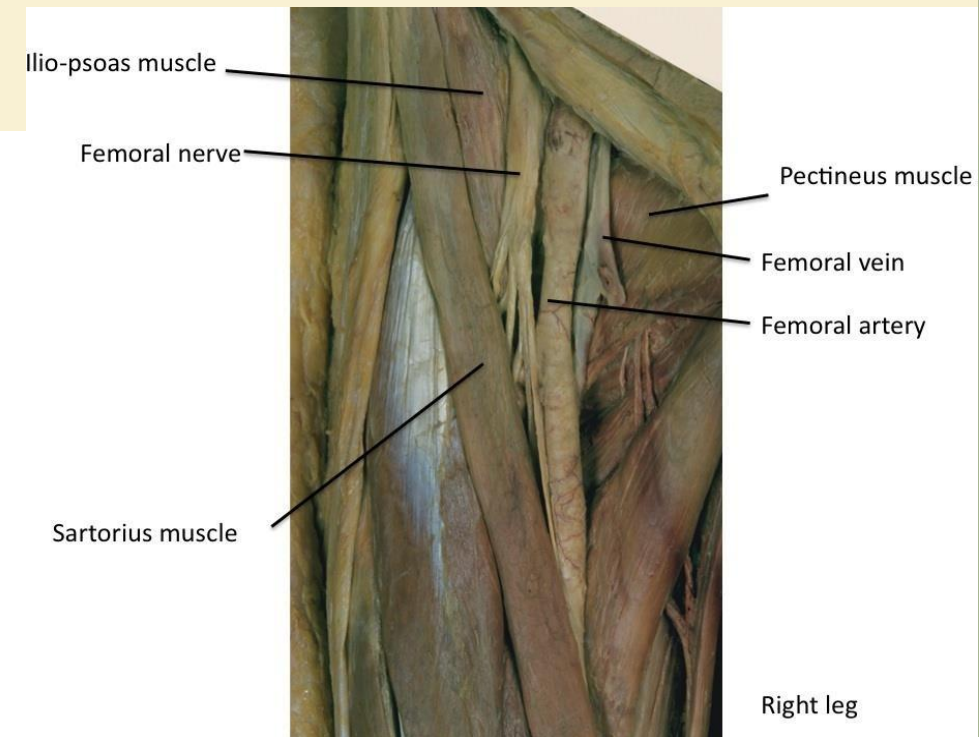
- The continuation of the **popliteal vein** at adductor hiatus
- As it ascends through the adductor canal, the femoral vein lies posterolateral and then posterior to the femoral artery
- Occupies the middle compartment of femoral sheath
- Ends posterior to inguinal ligament where it becomes the **external iliac vein**
- It contains 2-3 valves

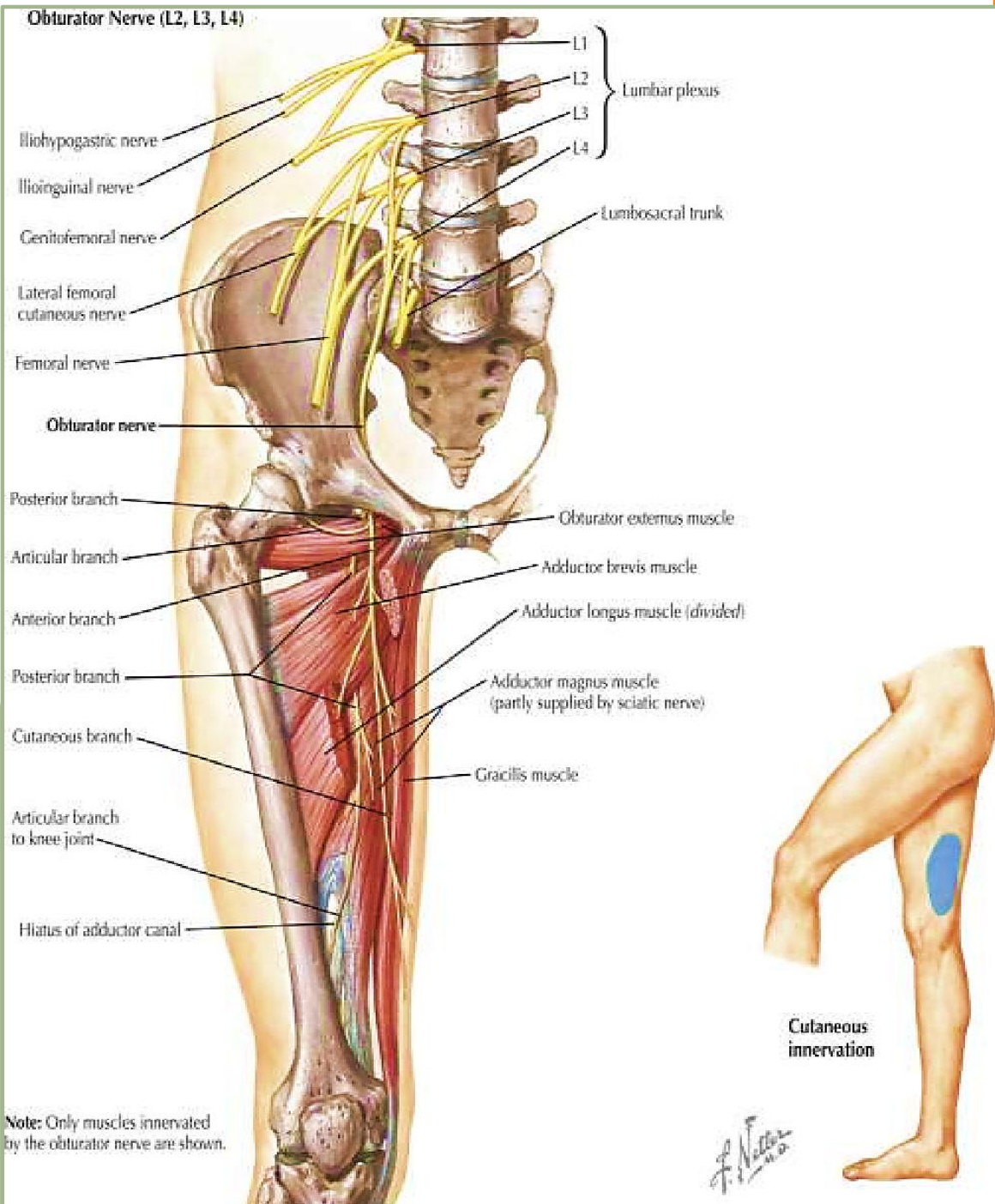
## Tributaries:

- 1 The great saphenous vein
- 2 The circumflex veins
- 3 profunda femoris vein
- 4 perforating veins
- 5 Venae comitantes of descending genicular vein



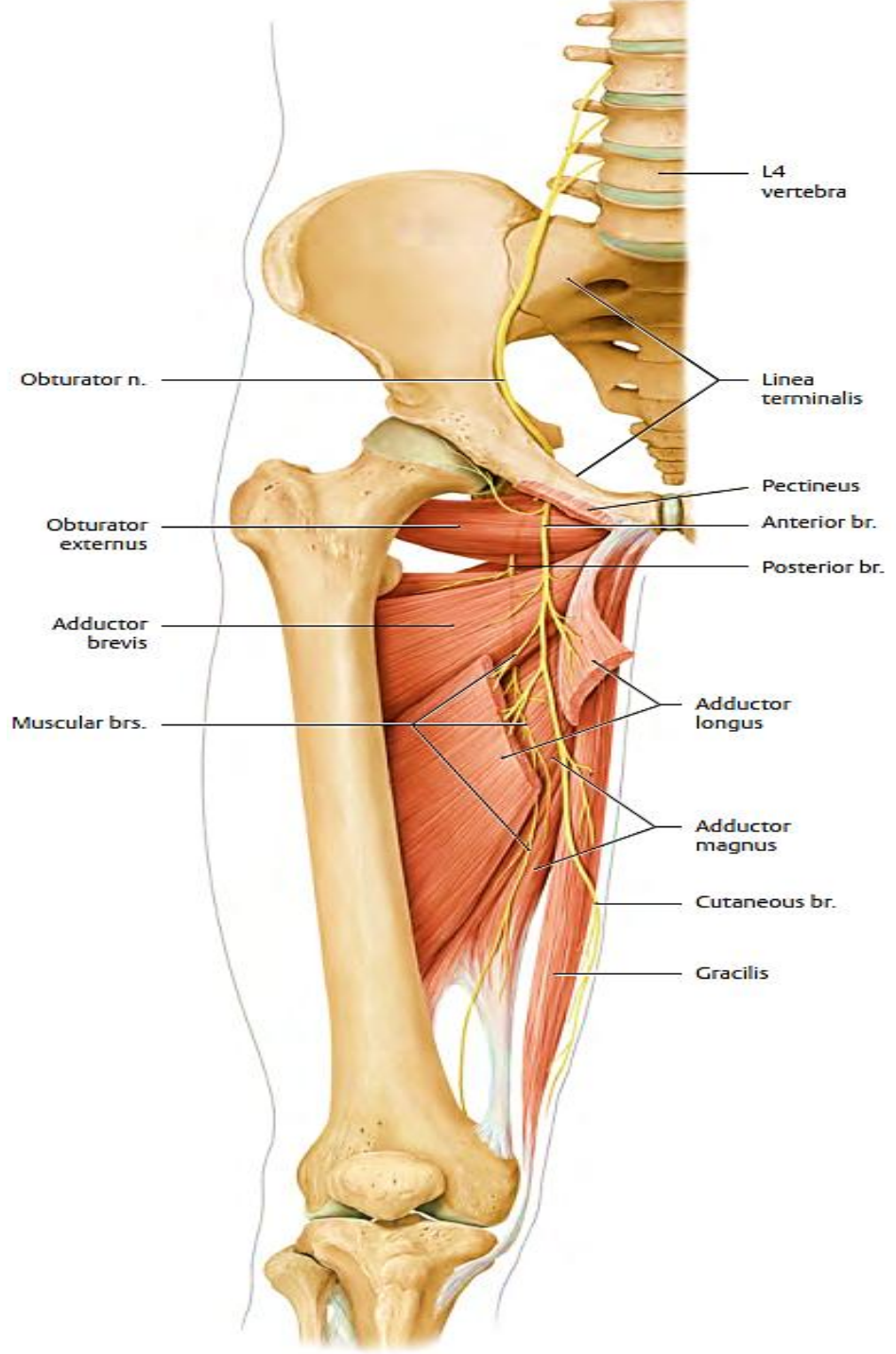
(A) Anteromedial view





## Obturator nerve

- Arises from **the anterior divisions** of lumbar plexus **(L2,3,4)**
- Leaves the pelvis by passing through the obturator canal
- Divides into anterior & posterior divisions which override adductor brevis
- **Branches:**
  - 1 **Muscular**; to adductor muscles
    - ✓ The anterior branch supplies the adductor longus, adductor brevis, gracilis, and pectineus;
    - ✓ the posterior branch supplies the obturator externus and adductor magnus.
  - 2 **Cutaneous**; to the medial aspect of the thigh
  - 3 **Articular**; to the hip & knee joints



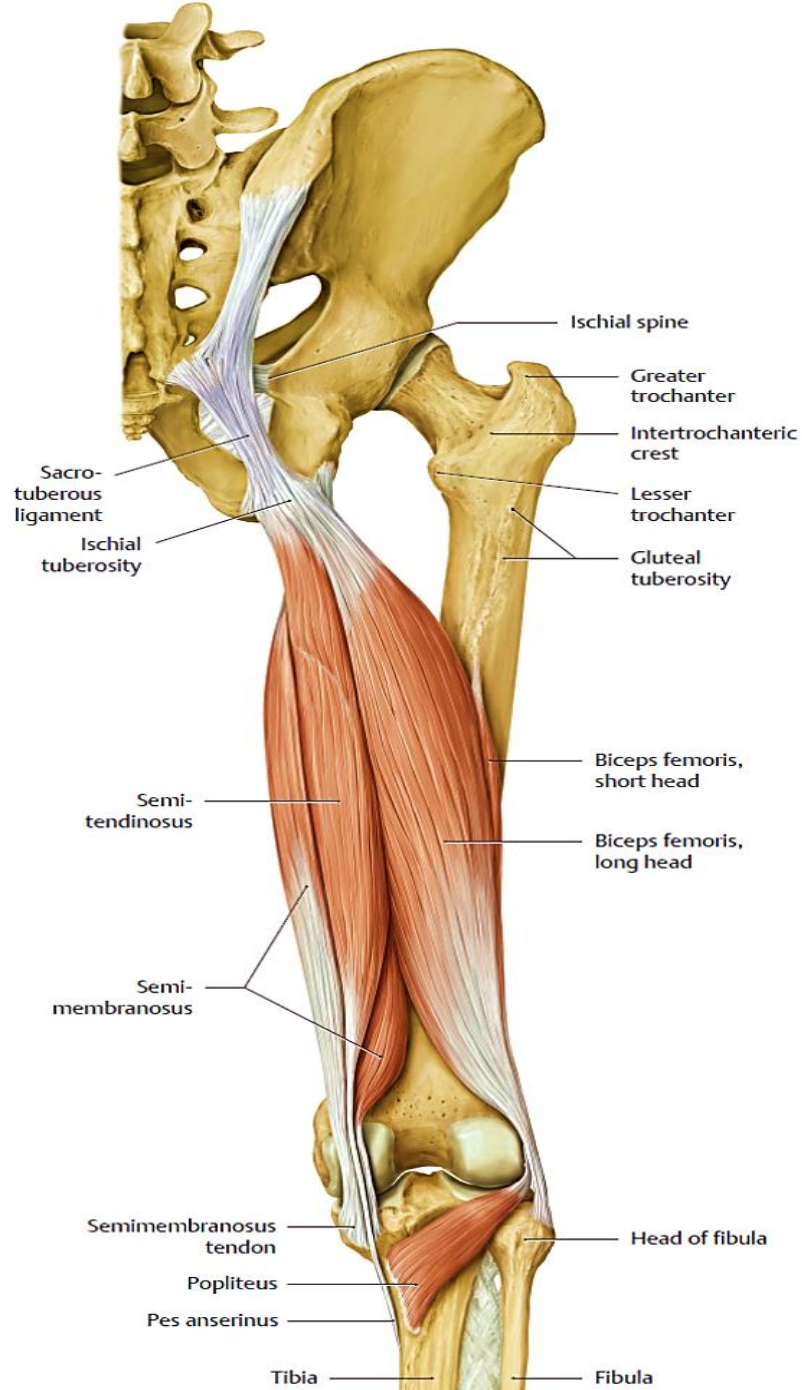
## Posterior Fascial Compartment Contents

**Muscles:** Biceps femoris, semitendinosus, semimembranosus, and a small part of the adductor magnus (hamstring portion)

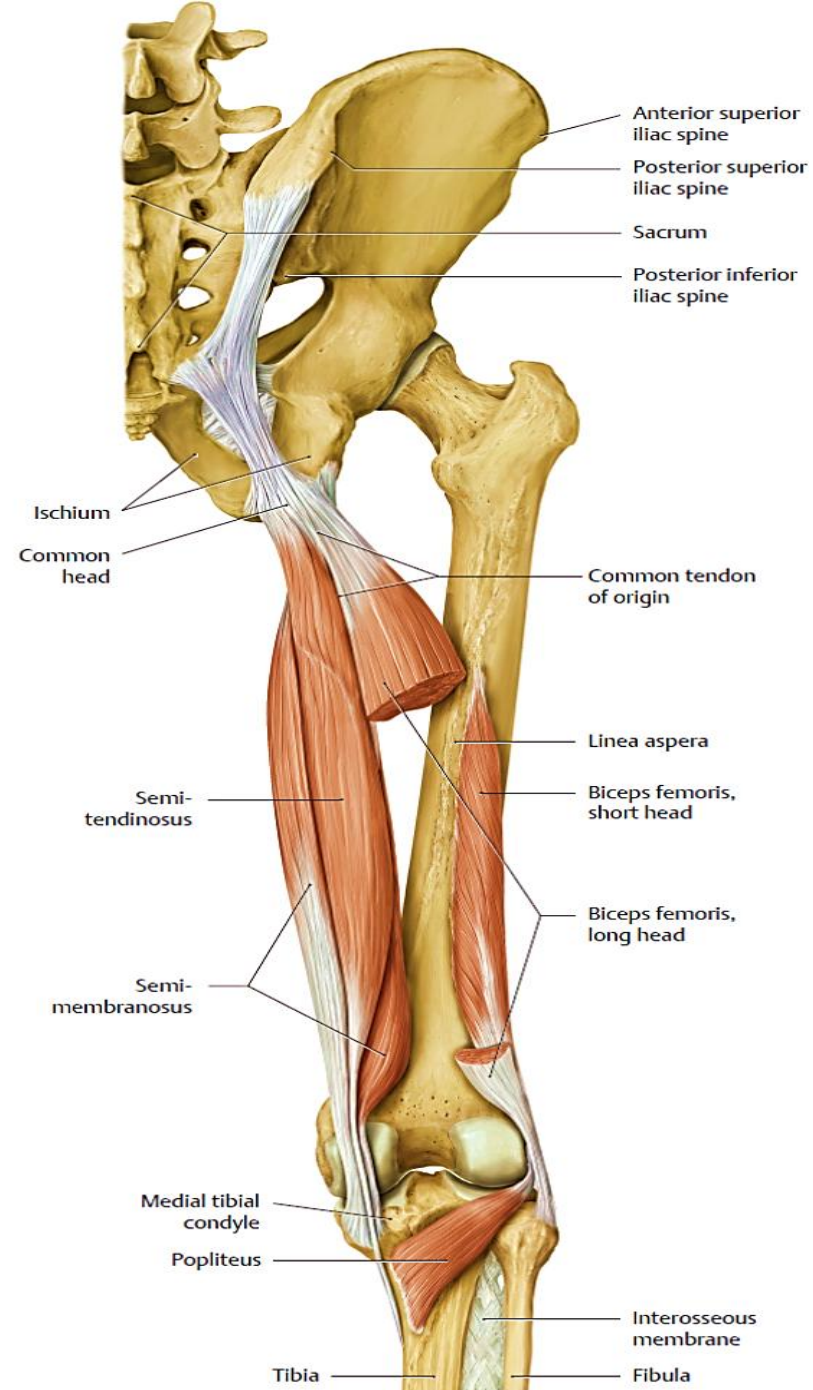
**Blood supply:** Branches of the profunda femoris artery

**Nerve supply:** Sciatic nerve

MUSCLE	ORIGIN	INSERTION	NERVE SUPPLY	NERVE ROOT <sup>a</sup>	ACTION
Biceps femoris	Long head: ischial tuberosity	Head of fibula	Long head: tibial portion of sciatic nerve	L5; <b>S1, 2</b>	Flexes and laterally rotates leg at knee joint; long head also extends thigh at hip joint
	Short head: linea aspera, lateral supracondylar ridge of shaft of femur		Short head: common fibular portion of sciatic nerve		
Semitendinosus	Ischial tuberosity	Upper part of medial surface of shaft of tibia	Tibial portion of sciatic nerve	<b>L5; S1, 2</b>	Flexes and medially rotates leg at knee joint; extends thigh at hip joint
Semimembranosus	Ischial tuberosity	Medial condyle of tibia	Tibial portion of sciatic nerve	<b>L5; S1, 2</b>	Flexes and medially rotates leg at knee joint; extends thigh at hip joint
Adductor magnus (hamstring portion)	Ischial tuberosity	Adductor tubercle of femur	Tibial portion of sciatic nerve	L2, <b>3, 4</b>	Extends thigh at hip joint



a



b

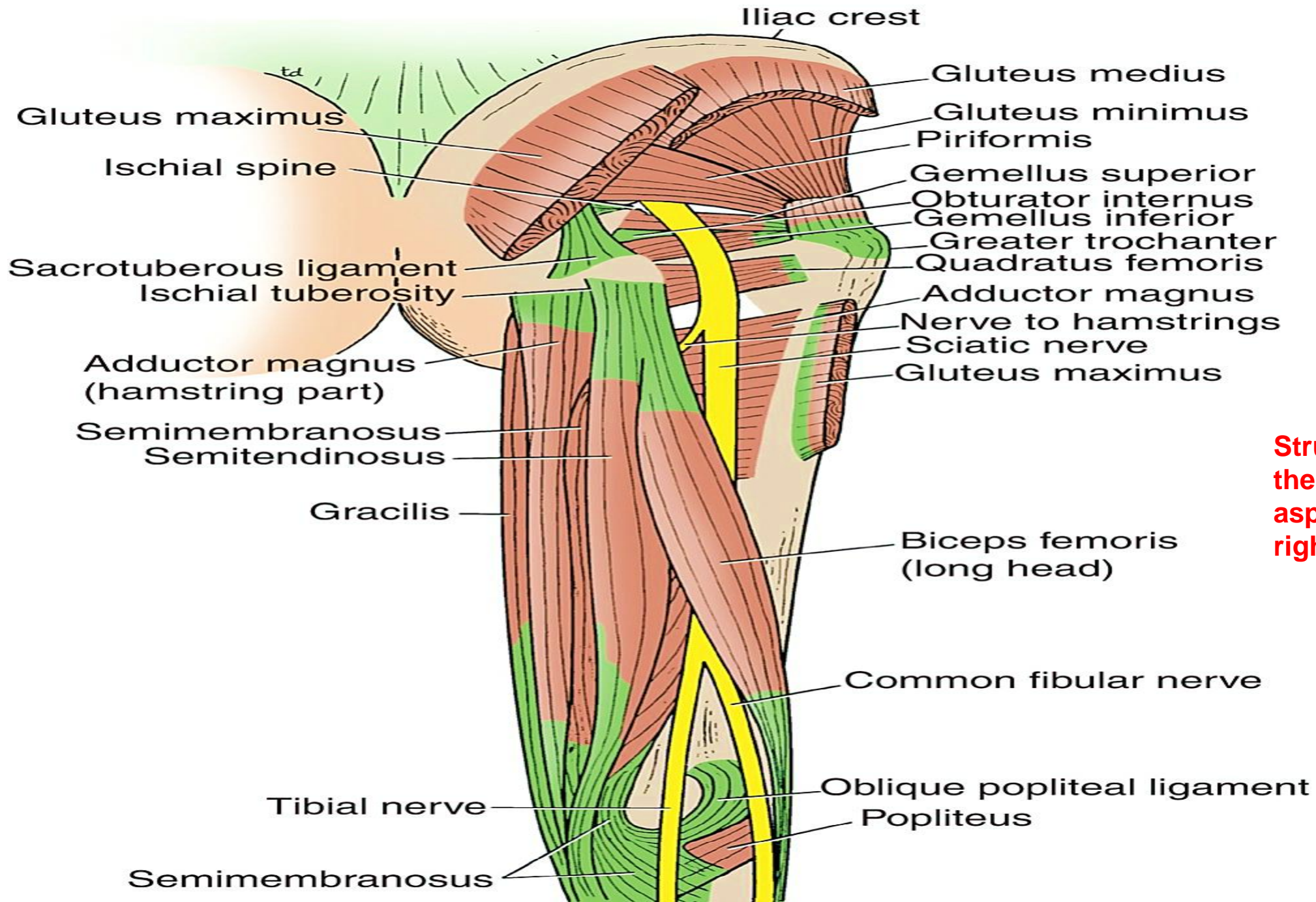
**Note the following:**

**The hamstrings** are the posterior thigh muscles that arise from the ischium and attach to the leg: **biceps femoris, semimembranosus, and semitendinosus**. They all cross two joints, except the **short head of the biceps femoris**.

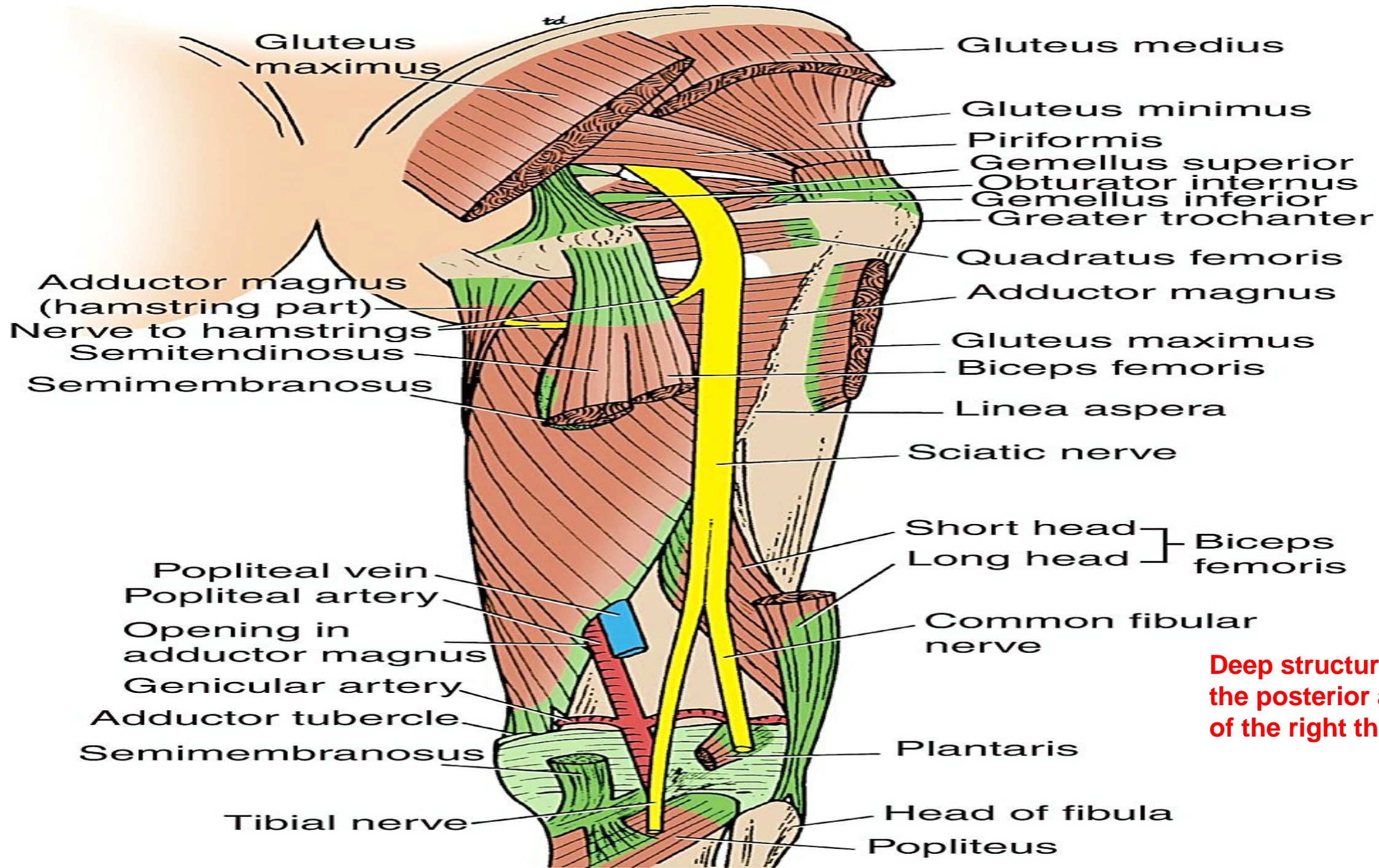
**The biceps femoris** muscle has two heads: a long head (hamstring portion) and a short head (gluteal portion). It also receives a dual nerve supply from the sciatic nerve. The tibial nerve component innervates the long head, and the common fibular (peroneal) component supplies the short head.

As noted earlier, the **adductor magnus muscle** also has two parts (an upper adductor part and a lower hamstring part) and a dual innervation. The tibial nerve component of the sciatic nerve supplies the hamstring portion, and the obturator nerve supplies the adductor part.

**The semimembranosus** insertion sends a fibrous expansion upward and laterally, which reinforces the capsule on the back of the knee joint. This expansion is called the oblique popliteal ligament



**Structures in the posterior aspect of the right thigh.**



**Deep structures in the posterior aspect of the right thigh.**

## **Posterior Compartment Blood Supply**

The four perforating branches of the profunda femoris artery provide a rich blood supply to this compartment. The profunda femoris vein drains the greater part of the blood from the compartment.

## **Posterior Compartment Nerve Supply**

The sciatic nerve leaves the gluteal region and descends in the midline of the posterior compartment of the thigh. It is overlapped posteriorly by the adjacent margins of the biceps femoris and semimembranosus muscles and lies on the posterior aspect of the adductor magnus muscle. It ends in the lower third of the thigh by dividing into the separate tibial and common fibular (peroneal) nerves. Occasionally, the sciatic nerve divides into its two terminal parts at a higher level—in the upper part of the thigh, the gluteal region, or even inside the pelvis.

**The tibial nerve** supplies most of the posterior compartment of the thigh

**The common fibular nerve** innervates only the short head of the biceps. Both the tibial and common fibular nerves enter the popliteal fossa and continue into the leg

## **POPLITEAL FOSSA**

The popliteal fossa is a diamond-shaped intermuscular space situated at the back of the knee. The fossa is most prominent when the knee joint is flexed. It contains the popliteal vessels, the small saphenous vein, the common fibular (peroneal) and tibial nerves, the posterior cutaneous nerve of the thigh, the genicular branch of the obturator nerve, connective tissue, and lymph nodes. The popliteal fossa is comparable to the cubital fossa in the upper limb, in that both connect the upper and lower segments of the limb.

### **Boundaries**

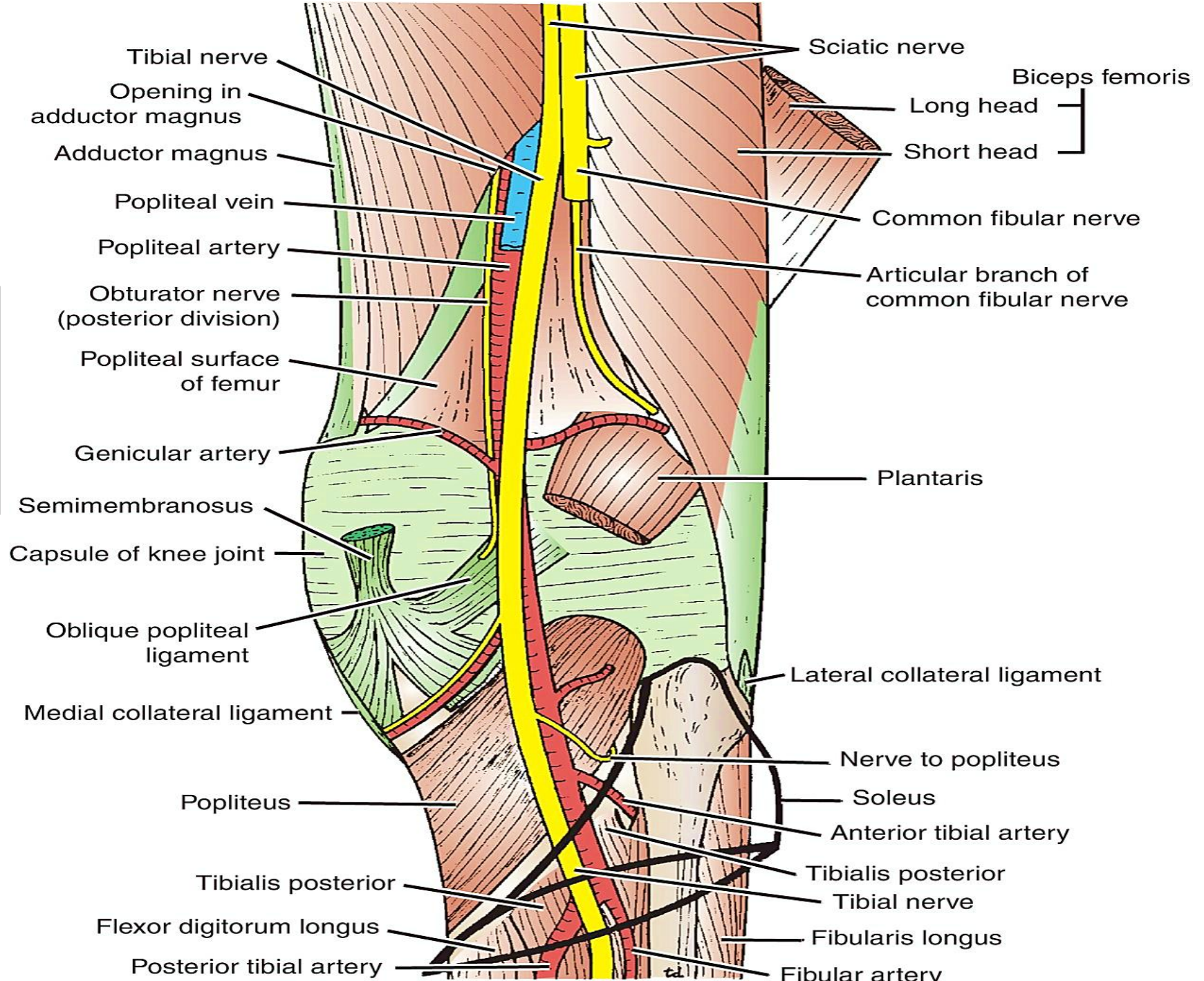
**Laterally:** The biceps femoris above and the lateral head of the gastrocnemius and plantaris below

**Medially:** The semimembranosus and semitendinosus above and the medial head of the gastrocnemius below

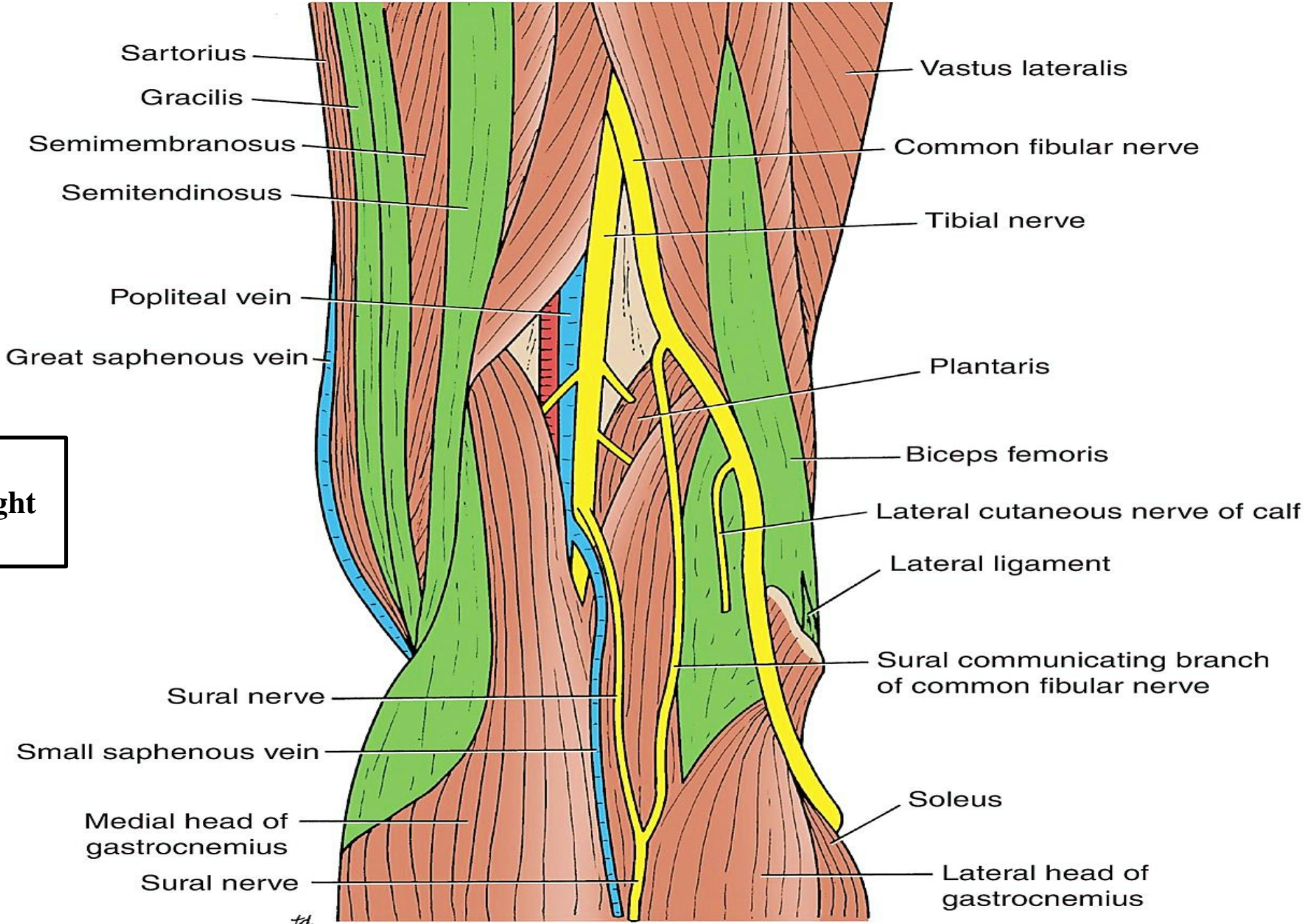
**Anterior wall (floor):** The popliteal surface of the femur, the capsule of the knee joint, and the popliteus muscle

**Roof:** The skin, the superficial fascia, and the deep fascia of the thigh

**Deep structures in the right popliteal fossa. The proximal end of the soleus muscle is shown in outline only.**



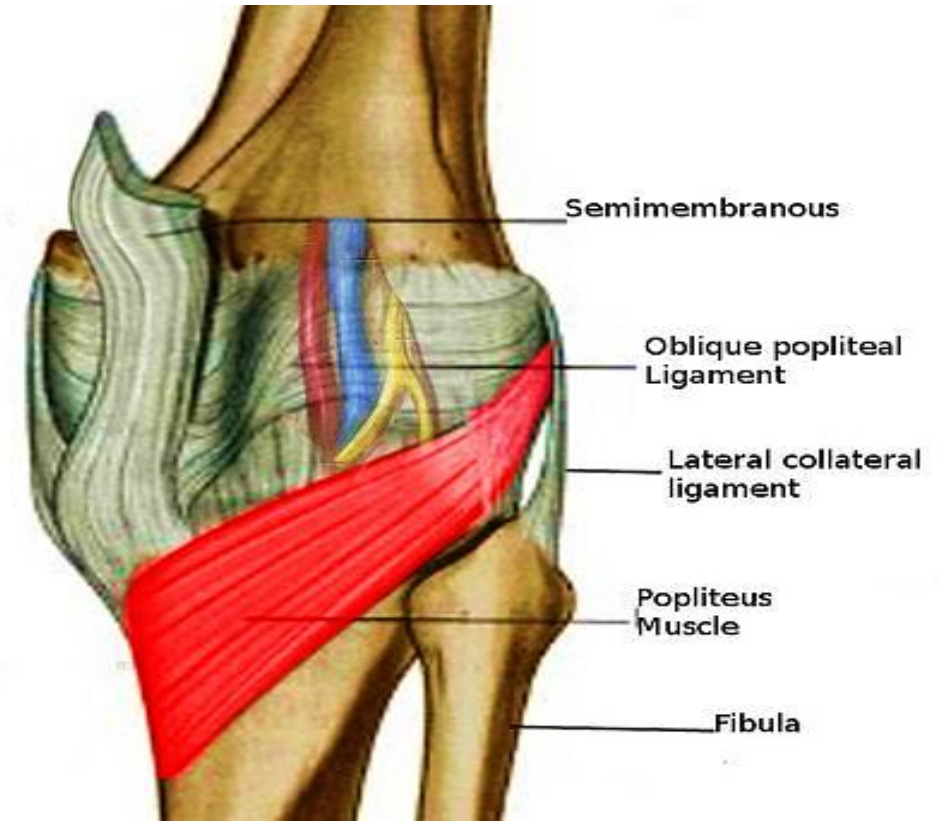
**Boundaries and contents of the right popliteal fossa**



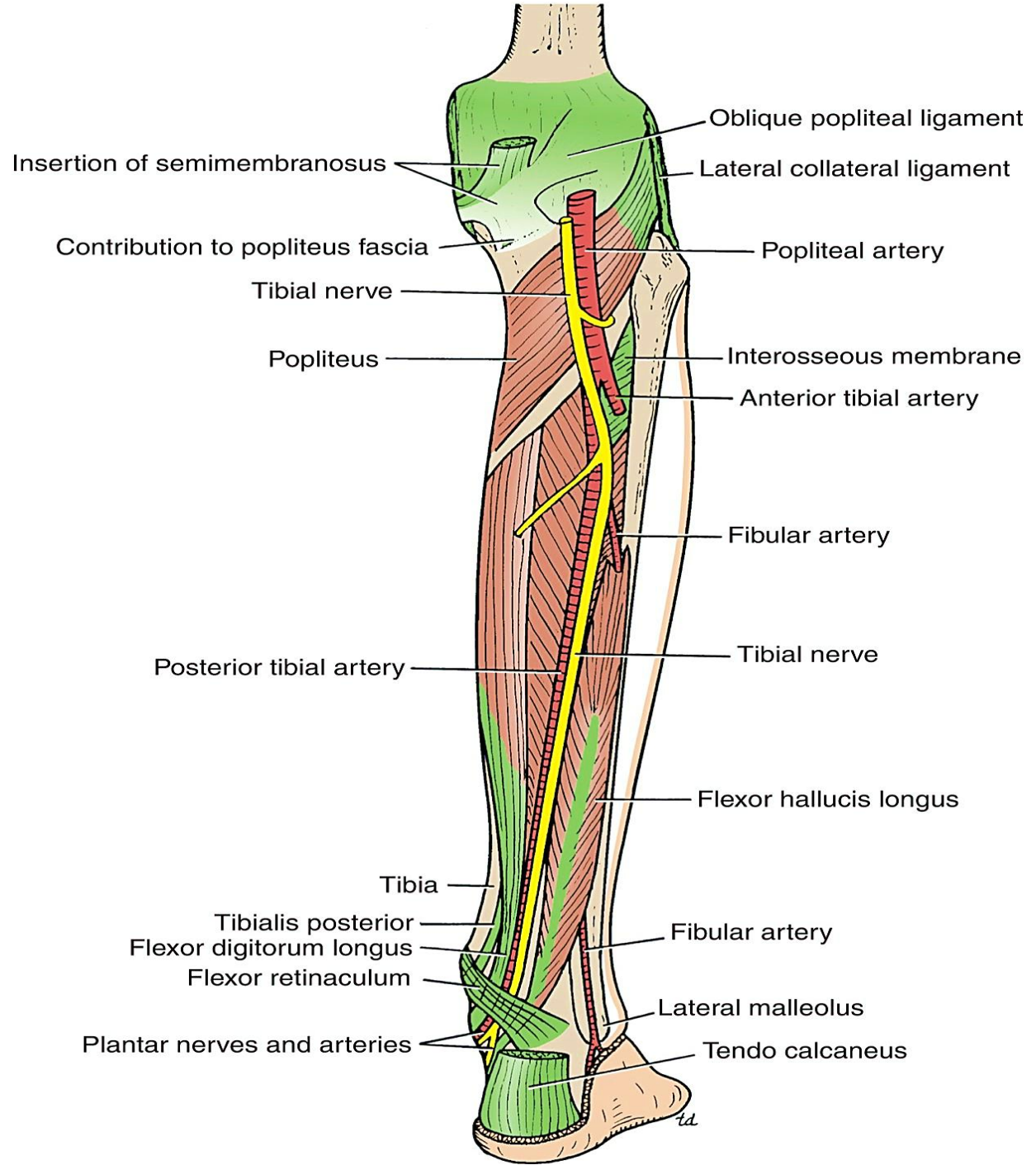
td

## Muscles

**The popliteus muscle** plays a key role in the movements of the knee joint. The muscle arises within the capsule of the knee joint, and its tendon separates the lateral meniscus from the lateral ligament of the joint. It emerges through the lower part of the posterior surface of the capsule of the joint to pass to its insertion. The popliteus acts to flex the knee and also to produce medial rotation of the tibia on the femur or, if the foot is on the ground, lateral rotation of the femur on the tibia. The latter action occurs at the commencement of flexion of the extended knee, and its rotatory action slackens the ligaments of the knee joint. This action is sometimes referred to as **unlocking the knee joint**. Because of its attachment to the lateral meniscus, it also pulls the cartilage backward at the commencement of flexion of the knee.



**Deep structures in the posterior aspect of the right leg.**



## **Popliteal Artery**

The popliteal artery is the continuation of the **femoral artery**. It is deeply placed and enters the popliteal fossa through the adductor hiatus (the opening in the adductor magnus). It ends at the level of the lower border of the popliteus muscle by dividing into **anterior and posterior tibial arteries**.

## **Relations**

**Anteriorly:** The popliteal surface of the femur, the knee joint, and the popliteus muscle.

**Posteriorly:** The popliteal vein, tibial nerve, fascia, and skin.

## **Branches**

The popliteal artery has muscular branches and multiple genicular branches to the knee joint.

## **Arterial Anastomosis around Knee Joint**

There is a profuse anastomosis of small branches of the **femoral artery** with muscular and articular branches of the **popliteal artery** and with branches of the **anterior and posterior tibial arteries**. This network is necessary to compensate for the narrowing of the popliteal artery that occurs during extreme flexion of the knee.

## **Popliteal Vein**

The popliteal vein is formed by the junction of the **venae comitantes** of the **anterior and posterior tibial arteries** at the lower border of the popliteus muscle on the medial side of the popliteal artery. As it ascends through the fossa, it crosses behind the popliteal artery so that it comes to lie on its lateral side. It passes through the adductor hiatus to become the **femoral vein**.

## **Tributaries**

The tributaries of the popliteal vein are as follows:

Veins that correspond to branches **given off by the popliteal artery**

**Small saphenous vein**, which perforates the deep fascia and passes between the two heads of the gastrocnemius muscle to end in the popliteal vein.

## **Popliteal Lymph Nodes**

About six lymph nodes are embedded in the fatty connective tissue of the popliteal fossa. They receive superficial lymph vessels from the lateral side of the foot and leg. These accompany the small saphenous vein into the popliteal fossa. They also receive lymph from the knee joint and from deep lymph vessels accompanying the anterior and posterior tibial arteries.

## **Nerves**

The sciatic nerve divides into its tibial and common fibular components **above the popliteal fossa**, and each nerve passes through the fossa as it descends into the leg.

### **Tibial Nerve**

The larger terminal branch of the sciatic nerve, the tibial nerve, arises in the lower third of the thigh. It runs downward through the popliteal fossa, lying first on the lateral side of the popliteal artery, then posterior to it, and finally medial to it. The popliteal vein lies between the nerve and the artery throughout its course. The nerve enters the posterior compartment of the leg by passing beneath the soleus muscle.

### **Branches**

**Cutaneous:** The sural nerve descends between the two heads of the gastrocnemius muscle and is usually joined by the sural communicating branch of the common fibular nerve. Numerous small branches arise from the sural nerve to supply the skin of the calf and the back of the leg. The sural nerve accompanies the small saphenous vein behind the lateral malleolus and distributes to the skin along the lateral border of the foot and the lateral side of the little toe.

**Muscular branches** supply both heads of the gastrocnemius and the plantaris, soleus, and popliteus.

**Articular branches** supply the knee joint.

## **Common Fibular (Peroneal) Nerve**

The smaller terminal branch of the sciatic nerve, the common fibular (peroneal) nerve, arises in the lower third of the thigh. It runs downward through the popliteal fossa, closely following the medial border of the biceps femoris muscle. It leaves the fossa by crossing superficial to the lateral head of the gastrocnemius muscle. It then passes behind the head of the fibula, winds laterally around the neck of the bone, pierces the fibularis (peroneus) longus muscle, and divides into two terminal branches: the **superficial fibular (peroneal) nerve** and the **deep fibular (peroneal) nerve**. As the nerve lies on the lateral aspect of the neck of the fibula, it is subcutaneous and can easily be rolled against the bone.

### **Branches**

**Cutaneous:** The **sural communicating branch** runs downward and joins the sural nerve.

**The lateral cutaneous nerve of the calf** supplies the skin on the lateral side of the back of the leg.

**Muscular branch** to the short head of the biceps femoris muscle, which arises high up in the popliteal fossa.

**Articular branches** to the knee joint.

## **Posterior Cutaneous Nerve of the Thigh**

The posterior cutaneous nerve of the thigh terminates by supplying the skin over the popliteal fossa.

## **Obturator Nerve**

The posterior division of the obturator nerve leaves the subsartorial canal with the femoral artery by passing through the adductor hiatus. The nerve terminates by supplying the knee joint.

Biceps femoris

Tibial nerve

Common fibular nerve

Superior lateral genicular artery

Lateral sural cutaneous nerve

Sural arteries

Medial sural cutaneous nerve

Tendon of biceps femoris

Gastrocnemius, lateral head

Gracilis

Semitendinosus

Semimembranosus

Popliteal vein

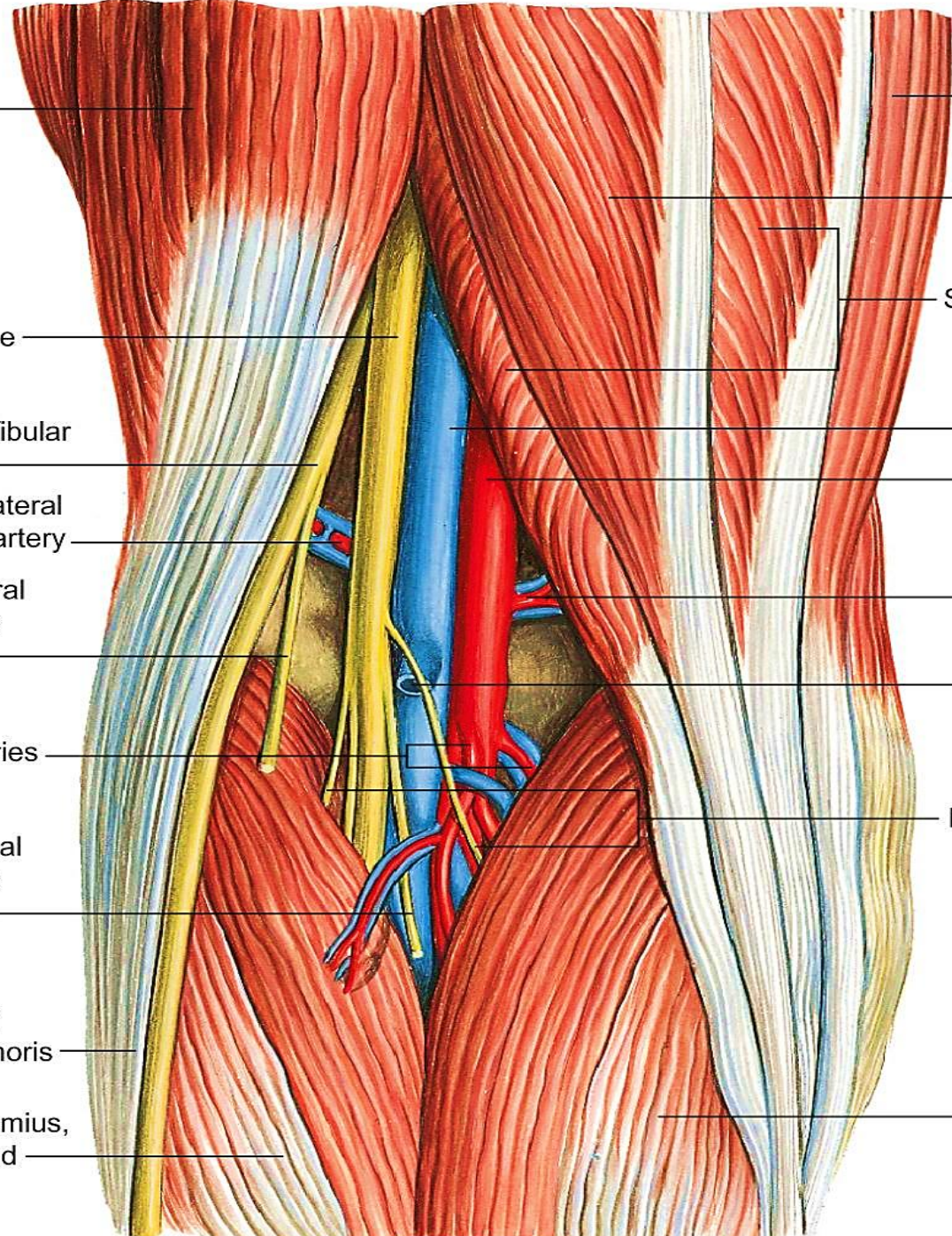
Popliteal artery

Superior medial genicular artery

Short saphenous vein

Muscular branches of tibial nerve

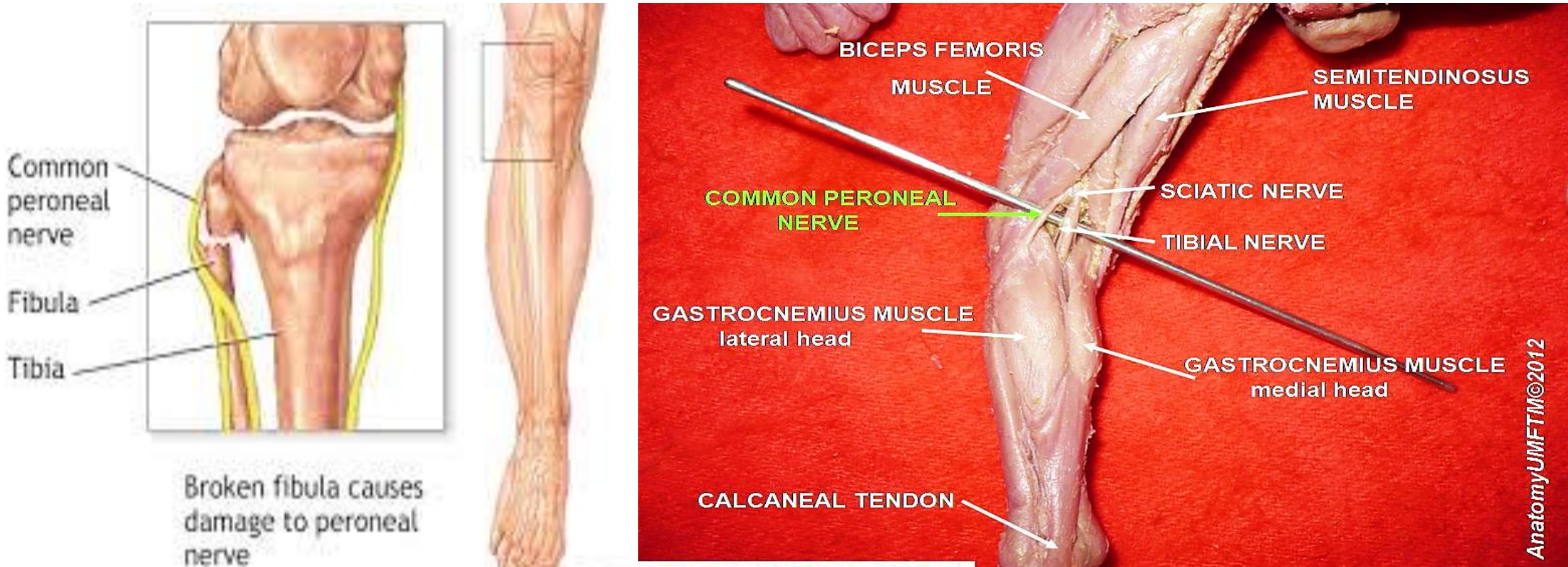
Gastrocnemius, medial head



## Clinical Notes

### Common Fibular (Peroneal) Nerve Injury

The common fibular nerve is extremely vulnerable to injury as it winds around the neck of the fibula. At this site, it is exposed to direct trauma or is involved in fractures of the upper part of the fibula. Injury to the common fibular nerve causes **footdrop**.



**Common Fibular (Peroneal) Nerve Injury**



**THANK YOU!**

