



### Life Cycle of *T.saginata*

*T. saginata* passes its life cycle in 2 hosts.

**Definitive host:** Humans are the definitive hosts and harbor the adult worm.

**Intermediate host:** Cattle (cow or buffalo) are the intermediate host and harbor the larval stage of the worm.

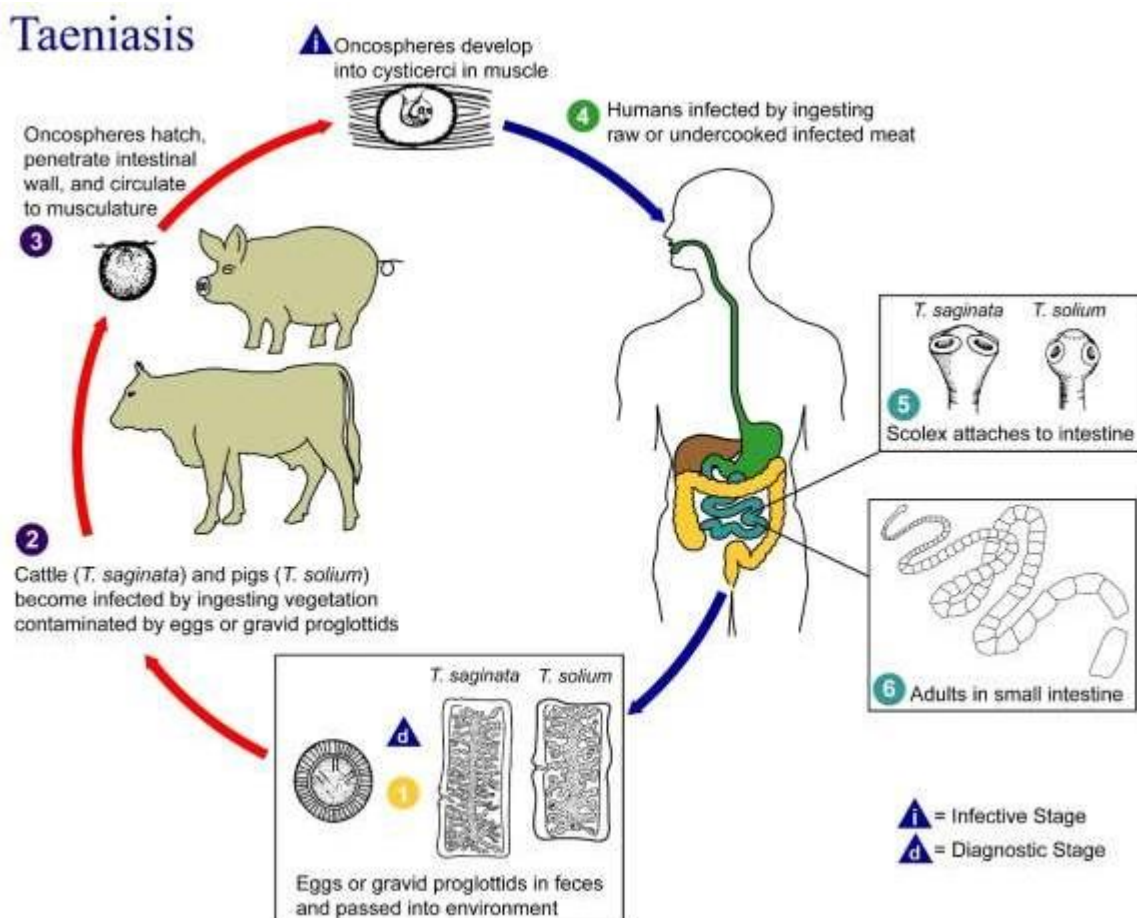
**Infective stage:** *Cysticercus bovis* (larval stage) is the infective stage to man, while eggs are infective to cattle.

-The adult worm lives in the small intestine of man. The gravid segments from the adult worm breakaway and are expelled singly. They actively force their way-out through the anal sphincter.

-The eggs or gravid segments are passed out with feces on the ground.

-The eggs deposited in soil remain viable for several weeks.

-They are infective to cattle, which ingest the eggs while grazing أثناء الرعي.



### Life cycle of *T.saginata*

## Life Cycle of *T. solium*

When *T. solium* causes intestinal taeniasis, its life cycle is similar to that of *T. saginata* except.

**Definitive host:** Man

**Intermediate host:** Pig

**Infective stage:** *Cysticercus cellulosae* (larva)

-Humans are infected by consuming inadequately cooked pork containing *cysticercus cellulosae* (measly pork).

-Man harboring adult worms may autoinfect oneself either by unhygienic personal habits or by reverse peristaltic movements of the intestine.

**When *Taenia* leads to cysticercosis, the life cycle is as follows:**

**Definitive host and Intermediate host:** Both man

**Infective stage:** Eggs of *T. solium* (not larva)

**Mode of infection:** Man acquires infection by ingesting eggs with contaminated food and water.

**Autoinfection:** A man harboring adult worm may autoinfect oneself, either by unhygienic personal habits or by reverse peristalsis of the intestine.

-The further development of the eggs is similar in man and pigs.

-The oncospheres are released in the duodenum or jejunum and penetrate the intestinal wall.

-They enter the **mesenteric venules** or **lymphatics** and are carried in systemic circulation to the different parts of the body.

They are filtered out principally in the muscles, where they develop into the larval stage, ***cysticercus cellulosae*** in about 60–70 days.

-In humans, it is a dead end and the larvae die without further development.

-Intestinal infection with *T. solium* occurs only in persons eating undercooked pork and usually in persons of low socio-economic condition with poor sanitation صرف صحي سيء..

-Eggs of *T. solium* are infective to pigs as well as to man.

## Pathogenicity and Clinical Features

### Intestinal Taeniasis

It can be caused by both *T. saginata* and *T. solium*.

\*The adult worm, in spite of its large size, causes surprisingly little inconvenience to the patient.

\*When the infection is symptomatic, vague abdominal discomfort, indigestion, nausea, diarrhea, and weight loss may be present. Occasional cases of acute intestinal obstruction, acute appendicitis, and pancreatitis have also been reported.

### Cysticercosis

It is caused by larval stage (*cysticercus cellulosae*) of *T. solium*.

\**Cysticercus cellulosae* may be solitary or more often multiple.

\*Any organ or tissue may be involved, the most common being subcutaneous tissues and muscles. It may also affect the eyes, brain, and less often the heart, liver, lungs, abdominal cavity, and spinal cord.

\*The cysticercus is surrounded by a fibrous capsule except in the eye and ventricles of the brain.

\*The larvae evoke a cellular reaction starting with infiltration of neutrophils, eosinophils, lymphocytes, plasma cells, and at times, giant cells. This is followed by fibrosis and death of the larva with eventual calcification.

\*The clinical features depend on the site affected **Subcutaneous nodules** are mostly asymptomatic **Muscular cysticercosis** may cause acute myositis **Neurocysticercosis** (cysticercosis of brain) is the most common and most serious form of cysticercosis.

-In **ocular cysticercosis**, cysts are found in vitreous humor, subretinal space and conjunctiva. The condition may present as blurred vision or loss of vision, iritis, uveitis, and palpebral conjunctivitis.

### Difference between *T. saginata* and *T. solium*

	<i>Taenia saginata</i>	<i>Taenia solium</i>
Length	5–10 m	2–3 m
Scolex	Large quadrate	Small and globular
	Rostellum and hooks are absent	Rostellum and hooks are present
	Suckers may be pigmented	Suckers not pigmented
Neck	Long	Short
Proglottids	1,000–2,000	Below 1,000
Measurement (gravid segment)	20 mm × 5 mm	12 mm × 6 mm
Expulsion	Expelled singly	Expelled passively in chains of 5 or 6
Uterus	Lateral branches 15–30 on each side; thin and dichotomous	Lateral branches 5–10 on each side; thick and dendritic
Vagina	Present	Absent
Accessory lobe of ovary	Absent	Present
Testes	300–400 follicles	150–200 follicles
Larva	Cysticercus bovis; present in cow not in man	Cysticercus cellulosae; present in pig and also in man
Egg	Not infective to man	Infective to man
Definitive host	Man	Man
Intermediate host	Cow	Pig, occasionally man
Disease	Causes intestinal taeniasis	Causes intestinal taeniasis and cysticercosis

## Laboratory Diagnosis

### Stool Examination

#### Eggs

- Microscopic examination of feces shows characteristic eggs of *Taenia* in 20–80% of patients.
- Formal ether sedimentation method of stool concentration is useful.
- Eggs can also be detected by **cellophane swab method** (NIH Swab) in 85–95% patients.
- Species identification cannot be made from the eggs, since the eggs of *T. saginata* and *T. Solium* are Similar.

#### Proglottids

- Species identification can be done by examining with a hand lens, the gravid proglottid pressed between 2 slides, when branching can be made out. (15–20 lateral branches in *T. saginata*; under 13 in *T. Solium*).

#### Scolex

- Definitive diagnosis can also be established by demonstration of unarmed scolex in case of *T. saginata* after antihelminthic treatment.

**Detection of *Taenia* Antigen in Feces:** Antigen capture enzyme-linked immunosorbent assay (ELISA) using polyclonal anti sera against *Taenia* is employed to detect **coproantigen** in feces since 1990 and is more sensitive than microscopy (specificity 100% and sensitivity 98%). The drawback of the test is that it cannot differentiate between *T. saginata* and *T. solium*.

#### Serodiagnosis

Specific antibodies in serum can be demonstrated by ELISA, indirect immunofluorescence test and indirect hemagglutination (IHA) test.

#### Molecular Diagnosis

Both DNA probes and polymerase chain reaction (PCR) technique are used to detect and differentiate between eggs and proglottids of *T. saginata* and *T. solium*.

It can also differentiate between the 2 subspecies of

*T. saginata*, viz *T. saginata saginata* and *T. saginata asiatica*.

