



Medical Laboratory Techniques Department

Lecture 8 : Plasmodium (Malaria)

Dr. Ahmed Khudhair Al- Hamairy

Malaria

- Protozoan parasites characterized by the production of spore-like oocysts containing sporozoites were known as sporozoa.
- They live **intracellularly**, at least during part of their life cycle.
- At some stage in their life cycle, they possess a structure called the **apical complex**, by means of which they attach to and penetrate host cells.
- These protozoa are therefore grouped under the **Phylum Apicomplexa**.
- The medically important parasites in this group are the **malaria parasites, Coccidia, and Babesia**.
- The **Phylum Apicomplexa** includes 2 classes viz. haematozoa and coccidia and 3 orders: eimeriida, haemosporida, and piroplasmida.

Note:

Many minute intracellular protozoa formerly grouped as sporozoa have been reclassified because of some structural differences. These are now called **microspora**. They infect a large spectrum of hosts including vertebrates and invertebrates.

Infection is mostly asymptomatic, but clinical illness is often seen in the immunodeficient.

Classification

Malaria parasite belongs to

Phylum: Apicomplexa **Class:**

Sporozoa

Order: Haemosporida

Genus: *Plasmodium*.

- The genus *Plasmodium* is divided into 2 sub genera, *P. vivax*, *P. malariae* and *P. ovale* belong to the subgenus **Plasmodium** while *P. falciparum* is allocated to subgenus **Laverania** because it differs in a number of aspects from the other 3 species.
- *P. vivax*, *P. malariae*, and *P. ovale* are closely related to other primate malaria parasites. *P. falciparum* on the other hand, is more related to bird malaria parasites and appears to be a recent parasite of humans, in evolutionary terms. Perhaps for this reason, falciparum infection causes the severest form of malaria and is responsible for nearly all fatal cases.
- *P. knowlesi*, a parasite of long-tailed Macaque monkeys may also affect man.

Causative Agents of Human Malaria

**Plasmodium vivax*: Benign Tertian Malaria

**Plasmodium falciparum*: Malignant Tertian Malaria

**Plasmodium malariae*: Benign Quartan Malaria

**Plasmodium ovale*: Benign Tertian Malaria.

Vectors

Human malaria is transmitted by over 60 species of female *Anopheles* mosquito.

*The male mosquito feeds exclusively on fruits and juices, but the female needs at least 2 blood meals, before the first batch of eggs can be laid.

*Out of 45 species of *Anopheles* mosquito in India, only few are regarded as the vectors of malaria. These are *An culicifacies*, *An fluvalilis*, *An stephansi*, *An minimus*, *An phillippenensis*, *An sundaicus*, etc.

Life Cycle

Malaria parasite passes its life cycle in 2 hosts.

Definitive host: Female *Anopheles* mosquito.

Intermediate host: Man.

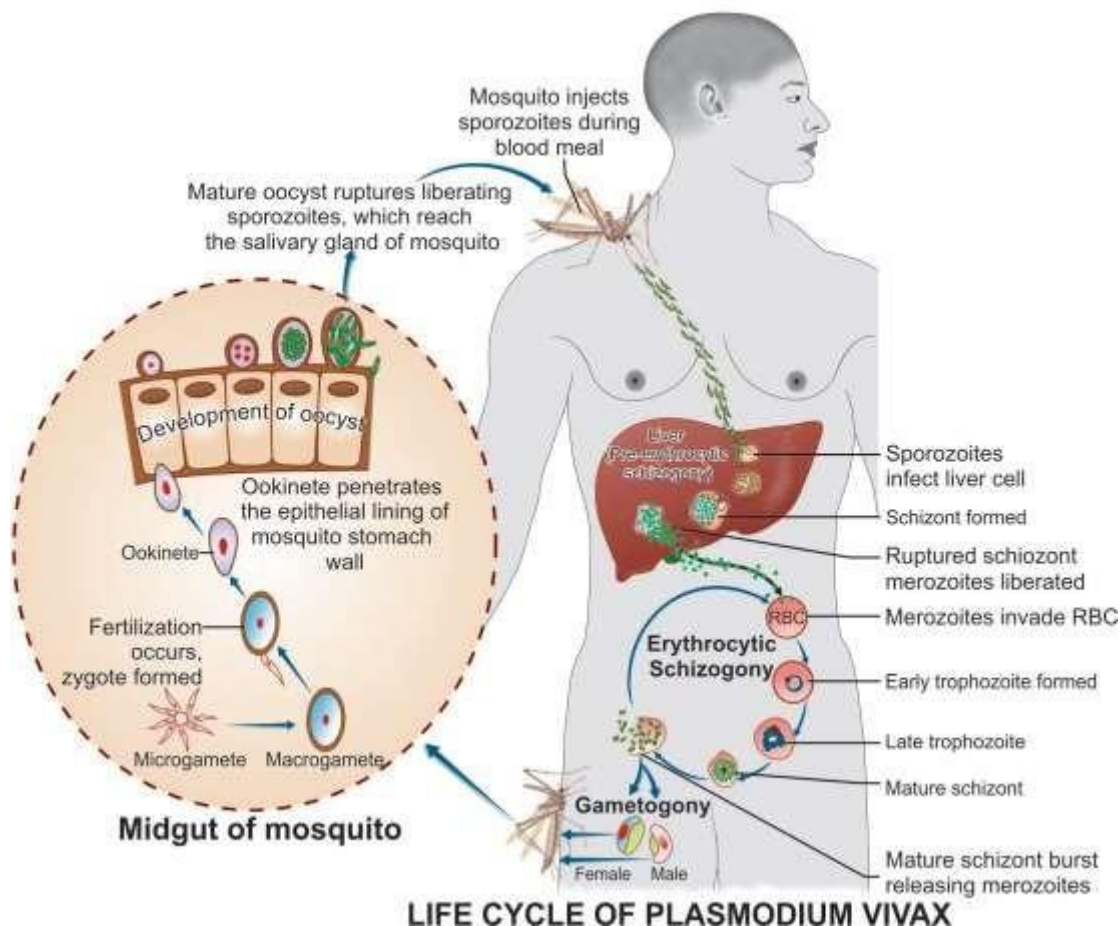
- The life cycle of malarial parasite comprises of 2 stages: **an asexual phase** occurring in humans, who act as the intermediate host and **a sexual phase** occurring in mosquito, which serves as a definitive host for the parasite.

Asexual phase:

- In this stage, the malaria parasite multiplies by division or splitting a process designated to as *Schizogony* (from *schizo*: to split, and *gone*: generation).
- Because this asexual phase occurs in man, it is also called the *vertebrate, intrinsic, or endogenous phase*.
- In humans, schizogony occurs in 2 locations: in the red blood cell (**erythrocytic schizogony**) and in the liver cells (**exoerythrocytic schizogony** or the tissue phase). Because schizogony in the liver is an essential step before the parasites can invade erythrocytes, it is called **pre-erythrocytic schizogony**. The products of schizogony, whether erythrocytic or exoerythrocytic, are called **merozoites** (*meros*: a part, *zoon*: animal).

Sexual phase:

- The sexual phase takes place in the female *Anopheles* mosquito, even though the sexual forms of the parasite (**gametocytes**) originate in human red blood cells.
- Maturation and fertilization take place in the mosquito, giving rise to a large number of sporozoites (from *sporos*: seed). Hence this phase of sexual multiplication is called **sporogony**. It is also called the *invertebrate, extrinsic, or exogenous phase*.
- There is, thus an alternation **تزاوب الأجيال** of generations in the life cycle of malaria parasites: asexual and sexual generations, alternatively.



Human Cycle (Schizogony)

Human infection comes through the bite of the infective female *Anopheles* mosquito.

*The sporozoites, which are infective forms of the parasite are present in the salivary gland of the mosquito.

*They are injected into blood capillaries when the mosquito feeds on blood after piercing the skin.

*Usually, 10–15 sporozoites are injected at a time, but occasionally, many hundreds may be introduced.

*The sporozoites pass into the blood stream, where many are destroyed by the phagocytes, but some reach the liver and enter the parenchymal cells (hepatocytes).

Pre-erythrocytic (Tissue) Stage or Exoerythrocytic Stage

Within an hour of being injected into the body by the mosquito, the sporozoites reach the liver and enter the hepatocytes to initiate the stage of **pre-erythrocytic schizogony or merogony**.

*The sporozoites, which are elongated spindle-shaped bodies, become rounded inside the liver cells.

*They enlarge in size and undergo repeated nuclear division to form several daughter nuclei; each of which is surrounded by cytoplasm.

*This stage of the parasite is called the **pre-erythrocytic** or **exoerythrocytic schizont or meront**.

*The hepatocyte is distended by the enlarging schizont and the liver cell nucleus is pushed to the periphery. خلية الكبد تتضخم عن طريق توسيع الشizont و يتم دفع نواة خلية الكبد إلى المحيط

*Mature liver stage schizonts are spherical (45–60 μm), multinucleate, and contain 2000–50,000 **uninucleate merozoites**.

*Unlike erythrocytic schizogony, there is no pigment in liver schizonts. These normally rupture in 6–15 days and release thousands of merozoites into the blood stream.

***The merozoites infect the erythrocytes by a process of invagination.**

*The interval between the entry of the sporozoites into the body and the first appearance of the parasites in blood is called the **prepatent period**.

*The duration of the pre-erythrocytic phase in the liver, the size of the mature schizont, and the number of merozoites produced vary with the species of the parasite.

***Latent stage:** In *P. vivax* and *P. ovale*, two kinds of sporozoites are seen, some of which multiply inside hepatic cells to form schizonts and others persist and remain dormant (resting phase). The resting forms are called **hypnozoites** (*hypnos: sleep*). From time to time, some are activated to become schizonts and release merozoites, which go on infecting RBCs producing **clinical relapse**.

* In *P. falciparum* and *P. malariae*, initial tissue phase disappears completely, and no hypnozoites are found. However, small number of erythrocytic parasites persist in the blood stream and in due course of time, they multiply to reach significant numbers resulting in clinical disease (**short-term relapse or recrudescence**) التفاس يُصير المدى

Erythrocytic Stage

The merozoites released by pre-erythrocytic schizonts invade the red blood cells.

* The receptor for merozoites is **glycophorin**, which is a major glycoprotein on the red cells. The differences in the glycophorins of red cells of different species may account for the species specificity of malaria parasites.

* Merozoites are **pear-shaped** bodies, about 1.5 μm in length, possessing an **apical complex (rhoptry)**. They attach to the erythrocytes by their apex and then the merozoites lie within an intraerythrocytic parasitophorous vacuole formed by red cell membrane by a process of invagination.

*In the erythrocyte, the merozoite loses its internal organelles and appears as a rounded body having a vacuole in the center with the cytoplasm pushed to the periphery and the nucleus at one pole. These young parasites are, therefore called the **ring forms** or **young trophozoites**. The parasite feeds on the hemoglobin of the erythrocyte. It does not metabolize hemoglobin completely and therefore, leaves behind a hematin-globin pigment called the **malaria pigment** or **haemozoin pigment**, as residue.

The appearance of malaria pigments varies in different species as follows:

••*P. vivax*: Numerous fine golden-brown dust-like particles

••*P. falciparum*: Few 1–3 solid blocks of black pigment

••*P. malariae*: Numerous coarse dark brown particles

••*P. ovale*: Numerous blackish brown particles.

*The malaria pigment released when the parasitized cells rupture is taken up by reticuloendothelial cells. Such pigment-laden cells *محملة بالصبغة* in the internal organs provide histological evidence of previous malaria infection.

*As the ring form develops, it enlarges in size becoming irregular in shape and shows **amoeboid motility**. This is called the **amoeboid form** or late **trophozoite form**.

*When the amoeboid form reaches a certain stage of development, its nucleus starts dividing by mitosis followed by a division of cytoplasm to become mature **schizonts** or **meronts**.

*A mature schizont contains 8–32 merozoites and hemozoin. The mature schizont bursts releasing the merozoites into the circulation.

























*The merozoites invade fresh erythrocytes within which they go through the same process of development.

This cycle of **erythrocytic Schizogony** or **merogony** is repeated sequentially, leading to progressive increase in the parasitemia, till it is arrested by the development of host immune response.

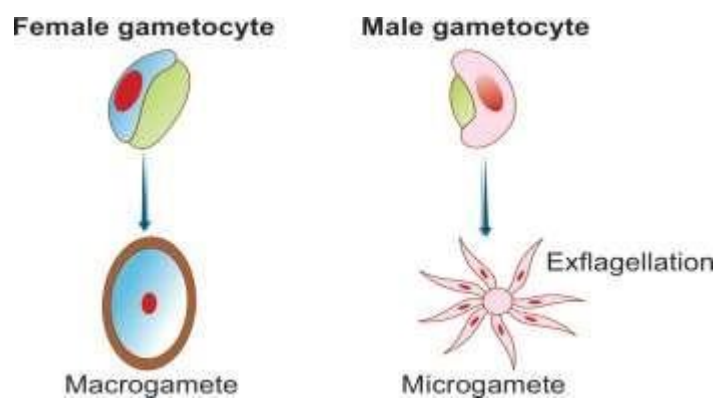
*The rupture of the mature schizont releases large quantities of pyrogens. This is responsible for the febrile paroxysms characterizing malaria.

*The interval between the entry of sporozoites into the host and the earliest manifestation of clinical illness is the **incubation period**, which is the time taken from entry of the sporozoites to the first appearance of malaria parasite in peripheral blood.

*In *P. falciparum*, erythrocytic schizogony always takes place inside the capillaries and vascular beds of internal organs. Therefore, in *P. falciparum* infections, schizonts, and merozoites are usually not seen in the peripheral blood.

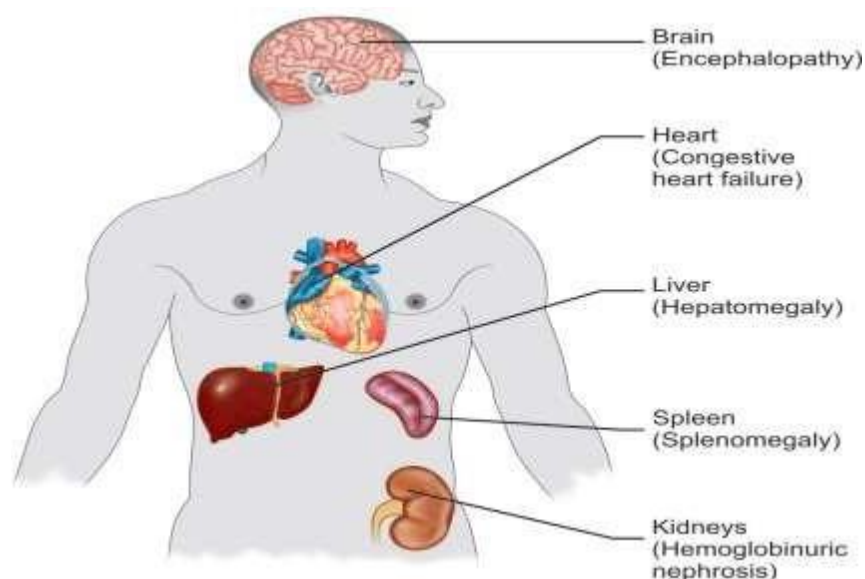
		<i>P. vivax</i>	<i>P. falciparum</i>	<i>P. malariae</i>	<i>P. ovale</i>
Trophozoites	Early				
	Late				
Schizonts	Early				
	Mature				
Gametocytes	Male				
	Female				

Malaria parasites: Erythrocytic stages of the four species (Giemsa stain).



Comparison of the Characteristics of Plasmodia Causing Human Malaria

	<i>P. vivax</i>	<i>P. falciparum</i>	<i>P. malariae</i>	<i>P. ovale</i>
Hypnozoites	Yes	No	No	Yes
Erythrocyte preference	Reticulocytes	Young erythrocytes, but can infect all stages	Old erythrocytes	Reticulocytes
Stages found in peripheral blood	Rings, trophozoites, schizonts, gametocytes	Only rings and gametocytes	As in vivax	As in vivax
Ring stage	Large, 2.5 μm , usually single, prominent chromatin	Delicate, small, 1.5 μm , double chromatin, and multiple rings common, Accole forms found.	Similar to vivax, but thicker	Similar to vivax, more compact
Late trophozoite	Large irregular, actively amoeboid, prominent vacuole	Compact, seldom seen in blood smear	Band form characteristic	Compact, coarse pigment
Schizont	Large filling red cell	Small, compact, seldom seen in blood smear	Medium size	Medium size
Number of merozoites	12–24 in irregular grape-like cluster	8–24 grape-like cluster	6–12 in daisy-head or rosette pattern	6–12 irregularly arranged
Microgametocyte	Spherical, compact, pale blue cytoplasm, diffuse nucleus	Sausage or banana-shaped pale blue or pink cytoplasm, large diffuse nucleus	As in vivax	As in vivax
Macrogametocyte	Large, spherical, deep blue cytoplasm, compact nucleus	Crescentic, deep blue cytoplasm, compact nucleus	As in vivax	As in vivax
Infected erythrocyte	Enlarged, pale, with Schuffner's dots	Normal size, Maurer's clefts, sometimes basophilic stippling	Normal, occasionally Ziemann's stippling	Enlarged, oval fimbriated, prominent Schuffner's dots
Duration of schizogony (days)	2	2	3	2
Prepatent period (days)	8	5	13	9
Average incubation period (days)	14	12	30	14
Appearance of gametocyte after parasite patency (days)	4–5	10–12	11–14	5–6
Duration of sporogony in mosquito (25°C) (days)	9–10	10–12	25–28	14–16
Average duration of untreated infection (years)	4	2	40	4



Major pathological changes in organs in malaria

Causes of anemia in malaria

- ❖ Destruction of large number of RBCs by complement mediated and autoimmune hemolysis.
- ❖ Suppression of erythropoiesis in the bone marrow
- ❖ Increased clearance of both parasitized and non-parasitized RBCs by the spleen.
- ❖ Failure of the host to recycle the iron bound in hemozoin pigment
- ❖ Antimalarial therapy in glucose-6-phosphate dehydrogenase (G6PD) deficient patients.

Clinical Features

Benign Malaria

The typical picture of malaria consists of periodic bouts of **fever** with rigor, followed by **anemia** and **splenomegaly**. Severe headache, nausea, and vomiting are common.

- The febrile paroxysm comprises of 3 successive stages: **cold stage, hot stage, and sweating stage**.
- ❖ In the cold stage, that lasts for 15–60 minutes, the patient experiences intense cold and uncontrollable shivering.
- ❖ This is followed by the hot stage, lasting for 2–6 hours, when the patient feels intensely hot. The temperature mounts to 41°C or higher.
- ❖ Afterwards comes the sweating stage, when the patient is drenched in profuse sweat. The temperature drops rapidly and the patient usually falls into deep sleep, to wake up refreshed.

Incubation period

It is the interval between the infective mosquito bite and the first appearance of clinical symptoms. The duration of incubation period varies with the species of the parasite. The average incubation periods of different species of *Plasmodium* are as follows:

***P. vivax*—14 (8–31) days**

***P. falciparum*—12 (8–14) days**

***P. ovale*—14 (8–31) days**

***P. malariae*—28 (18–40) days**

The incubation period is to be distinguished from the *pre-patent period*, which is the interval between the entry of the parasites into the host and the time when they first become detectable in blood. The paroxysm usually begins in the **early afternoon** and lasts for 8–12 hours. The febrile paroxysm synchronises with the erythrocytic schizogony.

- The periodicity is approximately 48 hours in tertian malaria (in *P. vivax*, *P. falciparum*, and *P. ovale*) and 72 hours in quartan malaria (in *P. malariae*).
- Quotidian periodicity, with fever occurring at 24 hour intervals may be due to 2 broods of tertian parasites maturing on successive days or due to mixed infection.

- Regular periodicity is seldom seen in primary attack, but is established usually only after a few days of continuous, remittent, or intermittent fever. True rigor is typically present in vivax malaria and is less common in falciparum infection.
- There can be both hypoglycemia or hyperglycemia in malaria.
- Sometimes, there may be **hyperkalemia** due to red cell lysis and fall in blood Ph.
- Infection with *P. vivax* usually follows a chronic course with periodic relapses, whereas *P. ovale* malaria is generally mild. Although *P. malariae* malaria is less severe, but it may lead to renal complications.
- Other features of benign malaria are anemia, splenomegaly, and hepatomegaly.

Malignant Tertian Malaria

The most serious and fatal type of malaria is malignant tertian malaria caused by *P. falciparum*. When not treated promptly and adequately, dangerous complications develop. The term **pernicious malaria** has been applied to a complex of life-threatening complications that sometimes supervene in acute falciparum malaria. These may present in various forms, the most important of which are the cerebral, algid, and septicemic varieties.

Cerebral Malaria:

It is the most common cause of death in malignant malaria.

- Even with treatment, death occurs in 15% of children and 20% of adults who develop cerebral malaria.
- ❖ It is manifested by headache, hyperpyrexia, coma or confusion, and paralysis.
- ❖ This occurs particularly when non-immune persons have remained untreated or inadequately treated for 7–10 days after development of the primary fever.
- ❖ Late stage schizonts of *P. falciparum* secrete a protein on the surface of RBCs to form knob-like deformities. This knob produces specific adhesive proteins, which promote aggregation of infected

RBCs to other non-infected RBCs and capillary endothelial cells. These sequestered RBCs cause **capillary plugging** of cerebral microvasculature, which results in anoxia, ischemia, and hemorrhage in brain.

Black water fever:

A syndrome called black water fever (malarial hemoglobinuria) is sometimes seen in falciparum malaria, particularly in patients, who have experienced repeated infections and inadequate treatment with quinine.

-Patients with G6PD deficiency may develop this condition after taking oxidant drugs, even in the absence of malaria. Clinical manifestation include bilious vomiting القيء الصفراوي and prostration انهيار, with passage of dark red or blackish urine (**black water**). The pathogenesis is believed to be massive intravascular hemolysis caused by anti-erythrocyte antibodies, leading to massive absorption of hemoglobin by the renal tubules (hemoglobinuric nephrosis) producing black water fever. Complications of black water fever include renal failure, acute liver failure, and circulatory collapse انهيار الدورة الدموية.

Algid Malaria: This syndrome is characterized by peripheral circulatory failure, rapid thready pulse with low blood pressure, and cold clammy skin. There may be severe abdominal pain, vomiting, diarrhea, and profound shock.

Septicemic malaria: It is characterized by high continuous fever with dissemination of the parasite to various organs, leading to multi organ failure. Death occurs in 80% of the cases

Transfusion Malaria:

Blood transfusion can accidentally transmit malaria, if the donor is infected with malaria. The parasites may remain viable in blood bank for 1–2 weeks. As this condition is induced by direct infection of red cells by the merozoites, pre-erythrocytic schizogony and hypnozoites are absent. **Relapse does not occur and incubation period is short.**

- **Congenital malaria:** A natural form of merozoite induced malaria, where the parasite is transmitted transplacentally from mother to fetus.
- **Renal transplantation** may lead to malaria if the donor had parasitaemia.
- **Shared syringes** among drug addicts may be responsible.

Differences between Recrudescence and Relapse

Recrudescence	Relapse
Seen in <i>P. falciparum</i> and <i>P. malariae</i>	Seen in <i>P. vivax</i> and <i>P. ovale</i>
Due to persistence of the parasite at a subclinical level in circulation	Due to reactivation of hypnozoites present in liver cells
Occurs within a few weeks or months of a previous attack	Occurs usually 24 weeks to 5 years after the primary attack
Can be prevented by adequate drug therapy or use of newer antimalarial drugs in case of drug resistance	Can be prevented by giving primaquine to eradicate hypnozoites

Laboratory Diagnosis

Demonstration of Parasite by Microscopy

Diagnosis of malaria can be made by demonstration of malarial parasite in the blood. Two types of smears are prepared from the peripheral blood. One is called **thin smear** and the other is called **thick smear**.

- ❖ **Thin smears:** They are prepared from capillary blood of fingertip and spread over a good quality slide by a second slide held at an angle of 30°–45° from the horizontal such that a tail is formed. A properly made thin film will consist of an unbroken smear of a single layer of red cells, ending in a tongue, which stops a little short of the edge of the slide. Thin smears are air dried rapidly, fixed in alcohol and stained by one of the Romanowsky stains such as Leishman,

Giemsa, Fields, or JSB stain (named after Jaswant Singh and Bhattacharjee). Thin smears are used for detecting the parasite and **determining the species**.

❖ **Thick smears:**

They can be made on the same slide of thin smear or separately. In a thick film, usually 3 drops of blood are spread over a small area (about 10 mm). The amount of blood in thin smear is about 1–1.5 μL , while in a thick smear it is 3–4 μL .

The thick film is dried and kept in a koplun jar for 5–10 minutes for dehemoglobinization. It is not fixed in methanol.

- Thick film is stained similar to thin film. The stained film is examined under the oil immersion microscope.
- The thick film is more **sensitive**, when examined by an experienced person, because it concentrates 20–30 layers of blood cells in a small area.
- Thick film is more suitable for rapid detection of malarial parasite, particularly when they are few (as low as 20 parasites/ μL).
- The dehemoglobinized and stained thick film does not show any red cells, but only leucocytes, and, when present, the parasites. But the parasites are often distorted in form, and as the diagnostic changes in blood cells such as **enlargement** and **stippling** cannot be made out, **species identification is difficult**.
- Thin film is examined first at the tail end and if parasites are found, there is no need for examining thick film. If parasites are not detected in thin film, then thick film should be examined. It is recommended that 200 oil immersion fields should be examined before a thick film is declared negative.

Quantitative Buffy Coat, Smear

The Quantitative buffy coat (QBC) test developed by Becton- Dickinson, USA is a new simplified method for diagnosing malaria, wherein a small quantity of blood (50–110 μL) of blood is spun in QBC centrifuge at 12,000 revolutions per minutes for 5 minutes.

- RBC containing malaria parasites are less dense than normal RBCs and concentrate just below the buffy coat of leucocytes at the top of the erythrocytic column.

- Pre-coating of the tube with acridine orange induces a fluorescence on the parasites, which can then be readily visualized under the oil immersion microscope because the parasite contains DNA, but the mature RBCs do not contain DNA and RNA. The nucleus of the parasite is detected by acridine orange stains and appears as fluorescing greenish yellow against red background. The advantage of QBC is that it is faster and more sensitive than thick blood smear.
- The disadvantage of the test is that it is less sensitive than thick film and is expensive.
- A careful smear examination still remains as the '**gold standard**' in malaria diagnosis.

Serodiagnosis

Serodiagnosis is not helpful in clinical diagnosis because they will not differentiate between an active and past infection. It is used mainly for seroepidemiological survey and to identify the infected donors in transfusion malaria. The tests used are indirect hemagglutination (**IHA**), indirect fluorescent antibody test (**IFA**), and enzyme-linked immunosorbent assay (**ELISA**).

Newer Methods of Diagnosis

Fluorescence Microscopy

Fluorescent dyes like acridine orange or benzothiocarboxy purine are used, which stain the parasites entering the RBCs but not WBCs. This is a method of differential staining.

- Acridine orange stains DNA as fluorescent green and cytoplasmic RNA as red.
- The stained slide is examined under fluorescent microscope.
- The method is mainly used for mass screening in field laboratory.

Rapid Antigen Detection Tests

Rapid diagnostic test are based on the detection of antigens using immunochromatographic methods. These rapid antigen detection tests have been developed in different test formats like the dipstick, card, and cassette bearing monoclonal antibody, directed against the parasite antigens. Several kits are available commercially, which can detect *Plasmodium* in 15 minutes.

Parasite-F Test

This test is based on detection of histidine rich protein-2 (HRP-2) antigen produced by the asexual stages of *P. falciparum* expressed on the surface of red cells.

-Monoclonal antibody produced against HRP-2 antigen (Pf band) is employed in the test strip.

Advantage: It is widely popular and has high sensitivity (98%) and specificity.

- The test is said to detect low asexual parasitemia of more than 40 parasites/ μ L.
- The test can be performed within 10 minutes.

Disadvantage: Pf HRP-2 antigen detection test cannot detect the other 3 malaria species.

- It remains positive up to 2 weeks after cure.
- In *P. falciparum* infection, Pf HRP-2 is not secreted in gametogony stage. Hence in 'carriers', the Pf band may be absent.

Dual Antigen Test

The test detects pLDH – (parasite lactate dehydrogenase) produced by trophozoites and gametocytes of all plasmodium species and PF HRP-2 antigen.

- Thus, one band (Pv band) is genus specific (*Plasmodium specific*) and other is *Plasmodium falciparum* specific.
- This test is a rapid 2-site sandwich immunoassay used for specific detection and differentiation of *P. falciparum* and *P. vivax* malaria in areas with high rates of mixed infection.
- The 'Pv' band can be used for monitoring success of antimalarial therapy in case of stained alone *P. vivax* infection as the test will detect only live

parasites and therefore will be negative, if the parasite has been killed by the treatment.

- The disadvantage of the test is that it is expensive and cannot differentiate between *P. vivax*, *P. ovale*, and *P. malariae*.

Molecular Diagnosis

DNA Probe

DNA probe is a highly sensitive method for the diagnosis of malaria. It can detect less than 10 parasites/ μ L of blood.

Polymerase Chain Reaction

Polymerase chain reaction (PCR) is increasingly used now for species specification and for detection of drug resistance in malaria.

Laboratory diagnosis of malaria

- ❖ Demonstration of malarial parasites in thick and thin blood smear examination by Leishman, Giemsa, or JSB stain
- ❖ Immunofluorescence staining and QBC smear
- ❖ Rapid immunochromatographic test (ICT) for detection of malaria antigen (PfHRP2 and PLDH)
- ❖ Molecular diagnosis: DNA probe and PCR
- ❖ Routine blood examination for Hb%, PCV, and blood sugar.