

# The Ankle Joint

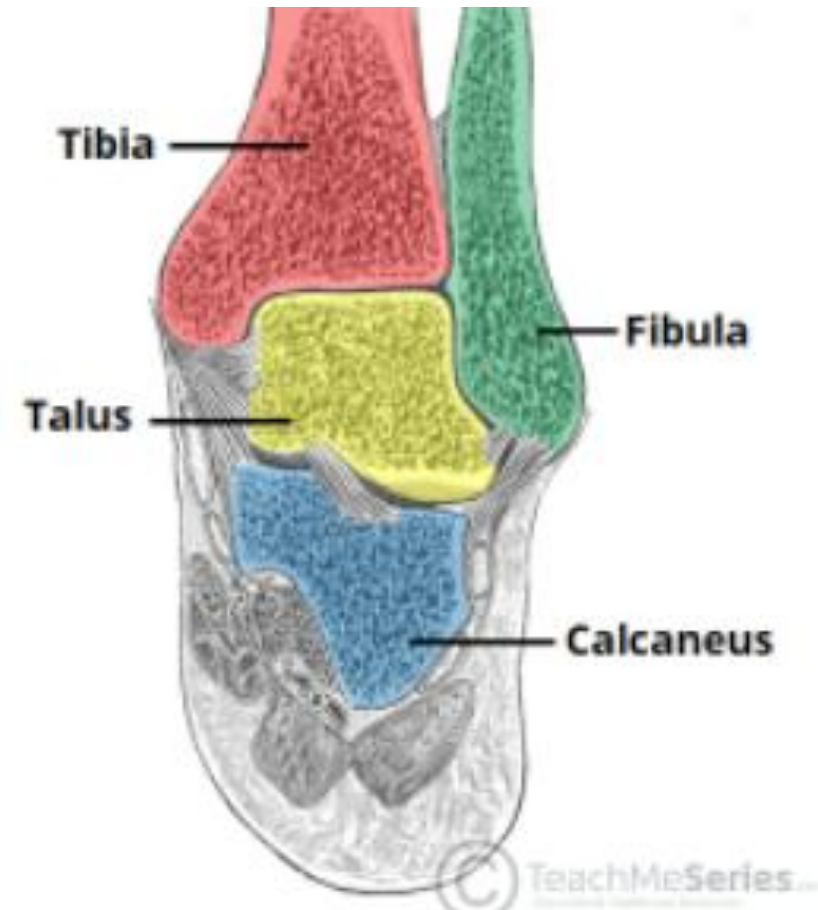
Presented by  
Dr. Fadhil sahib

# Anatomy of the Ankle Joint

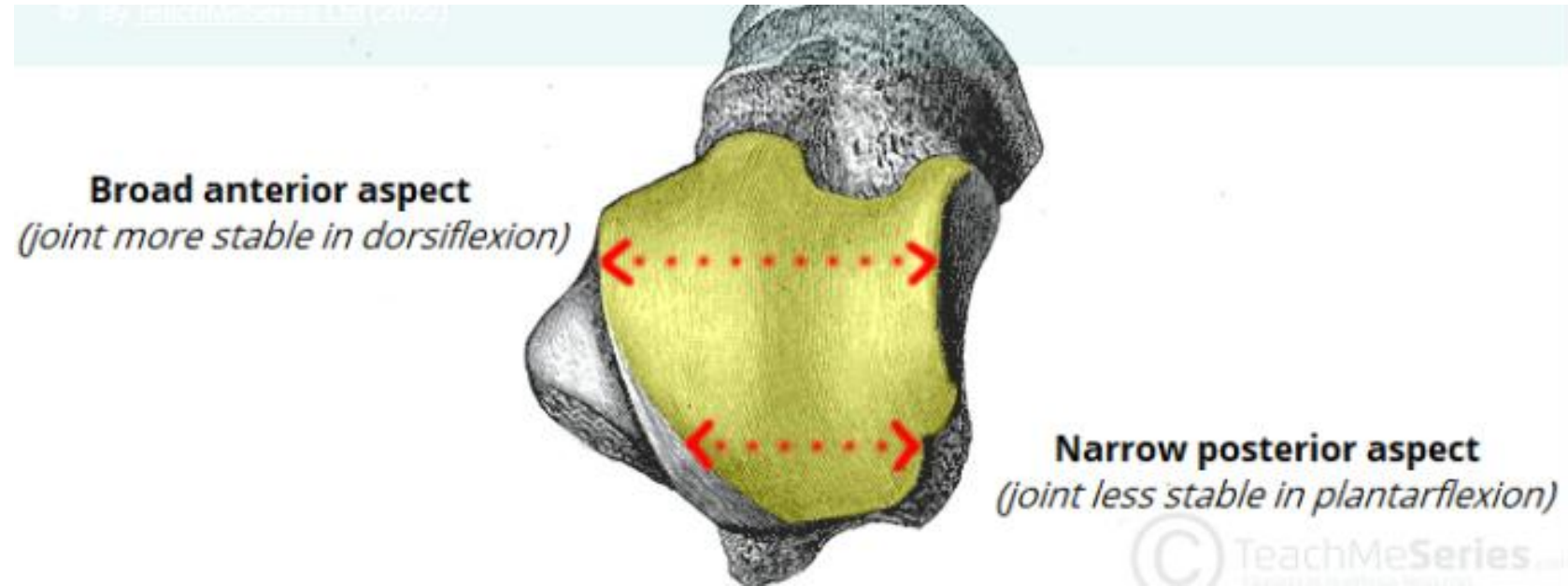
The ankle joint is a synovial hinge joint

## Articular surfaces:

- the lower tibia and the inner surface of the medial malleolus.
- the medial surface of the lateral malleolus of the fibula.
- the trochlear surface of the head of the talus



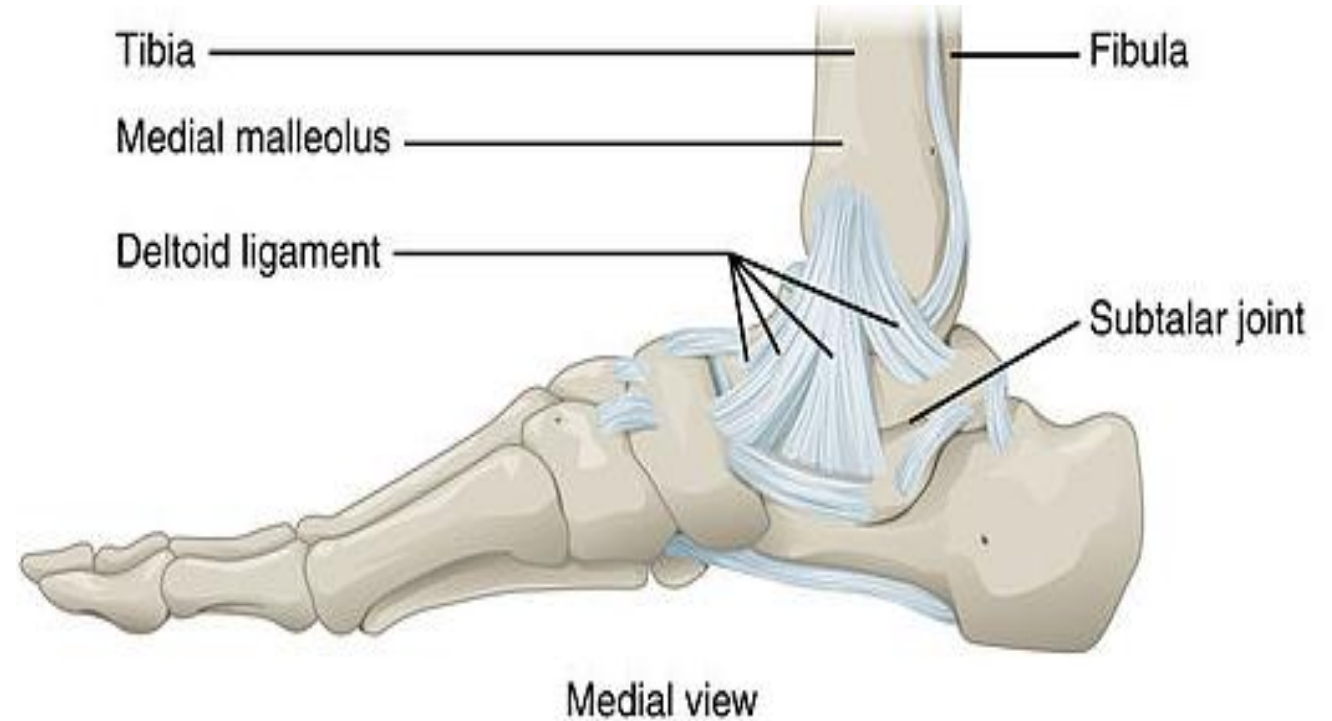
- **Capsule** This is attached to the margins of the articular surfaces, except where it extends distally to the neck of the talus
- **Synovium** This lines the capsule and frequently passes up between the lower ends of the tibia and the fibula



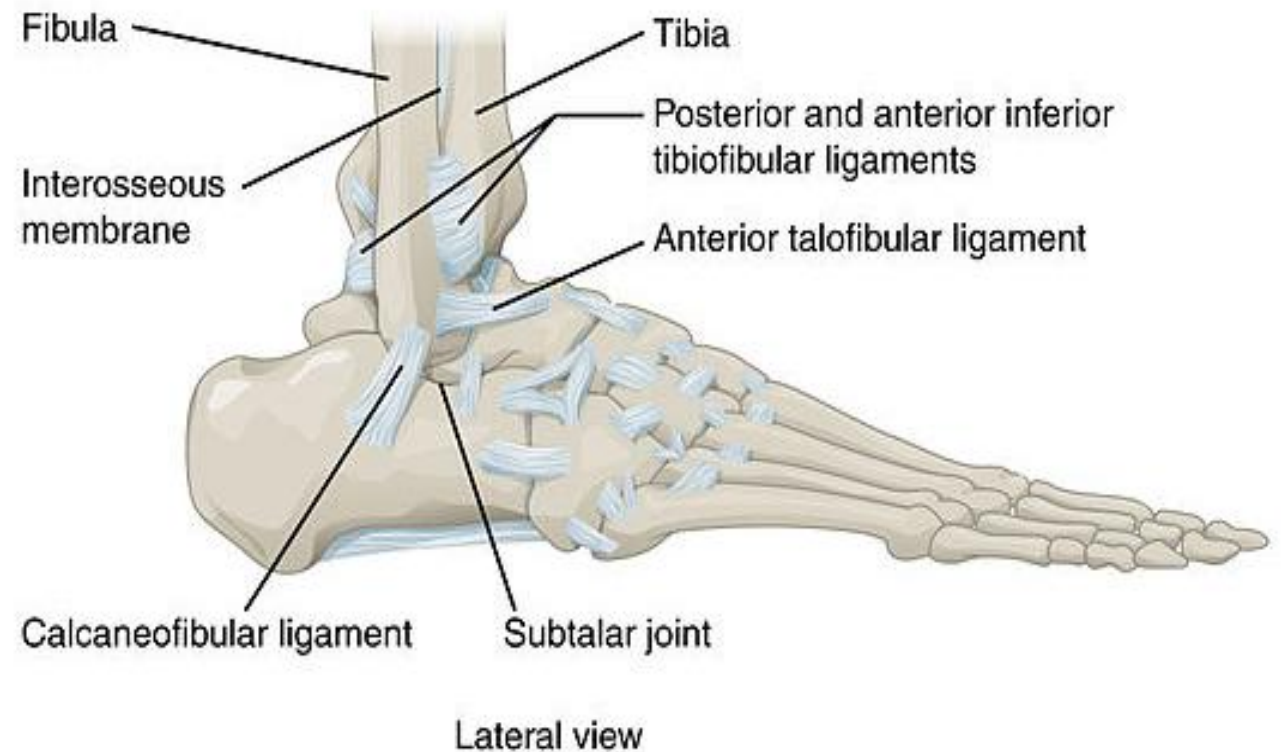
The articular surface of the talus is **broader anteriorly than posteriorly**. This makes the ankle more stable in dorsiflexion (i.e. standing) and more mobile in plantar flexion.

# Ligaments

- The capsule of the ankle joint is thickened with ligaments medially and laterally but is weak anteriorly and posteriorly
- The **deltoid ligament** is a triangular ligament on the medial aspect of the ankle. It is attached to the apex of the medial malleolus and inferiorly to the medial aspect of the talus, the sustentaculum tali of the calcaneus and the tuberosity of the navicular.



- Laterally, the ankle is strengthened by three ligaments:
- the **posterior talofibular ligament** , which passes medially from the lowest part of the malleolar fossa of the fibula to the posterior process of the talus.
- **the calcaneofibular ligament** , which passes from the apex of the lateral malleolus to the calcaneus.
- **the anterior talofibular ligament** , which passes anteromedially from the lateral malleolus to the lateral aspect of the neck of the talus



## **Syndesmotic ligaments**

The syndesmotic ligaments connect your tibia and fibula bones.

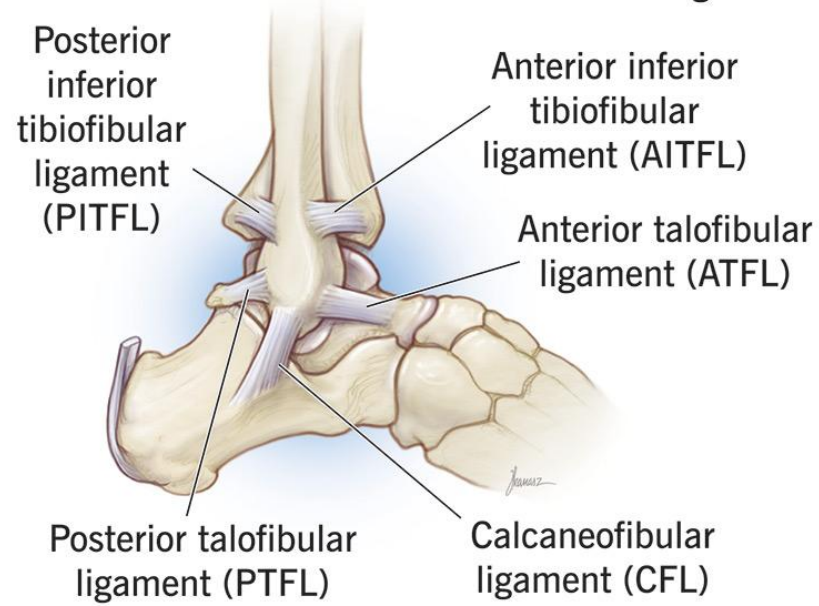
The five main syndesmotic ligaments are:

- Anterior inferior tibiofibular ligament (AITFL)
- Posterior inferior tibiofibular ligament (PITFL)
- Inferior transverse ligament (ITL)
- Transverse tibiofibular ligament (TTFL)
- Interosseous ligament (IOL)

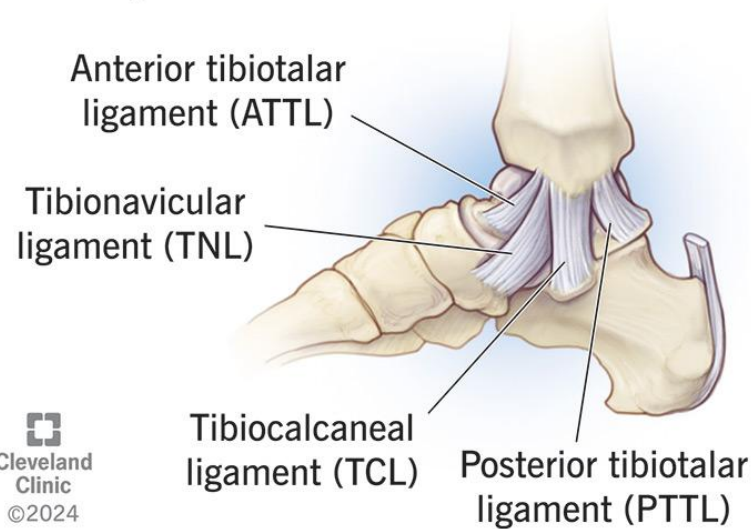
## **Function**

# Ankle ligaments

## Lateral ligaments

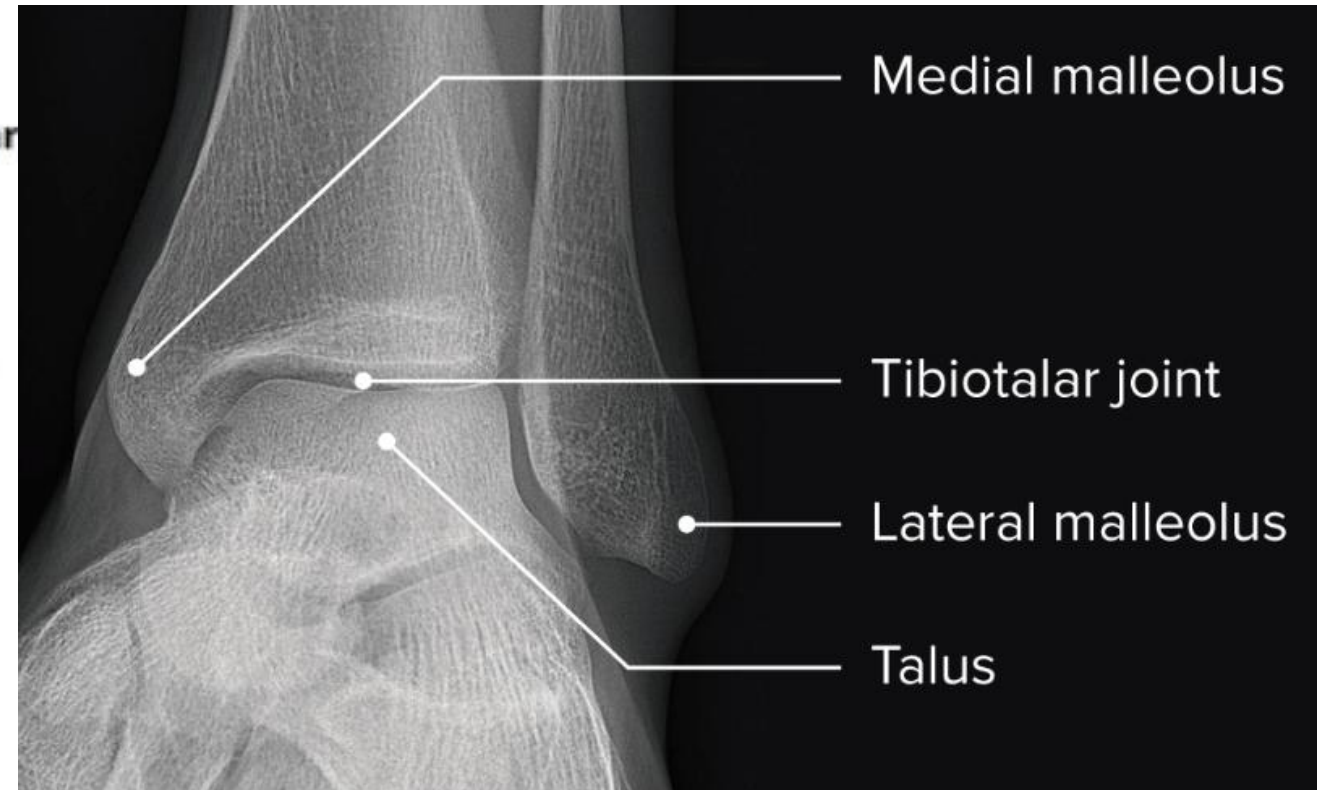
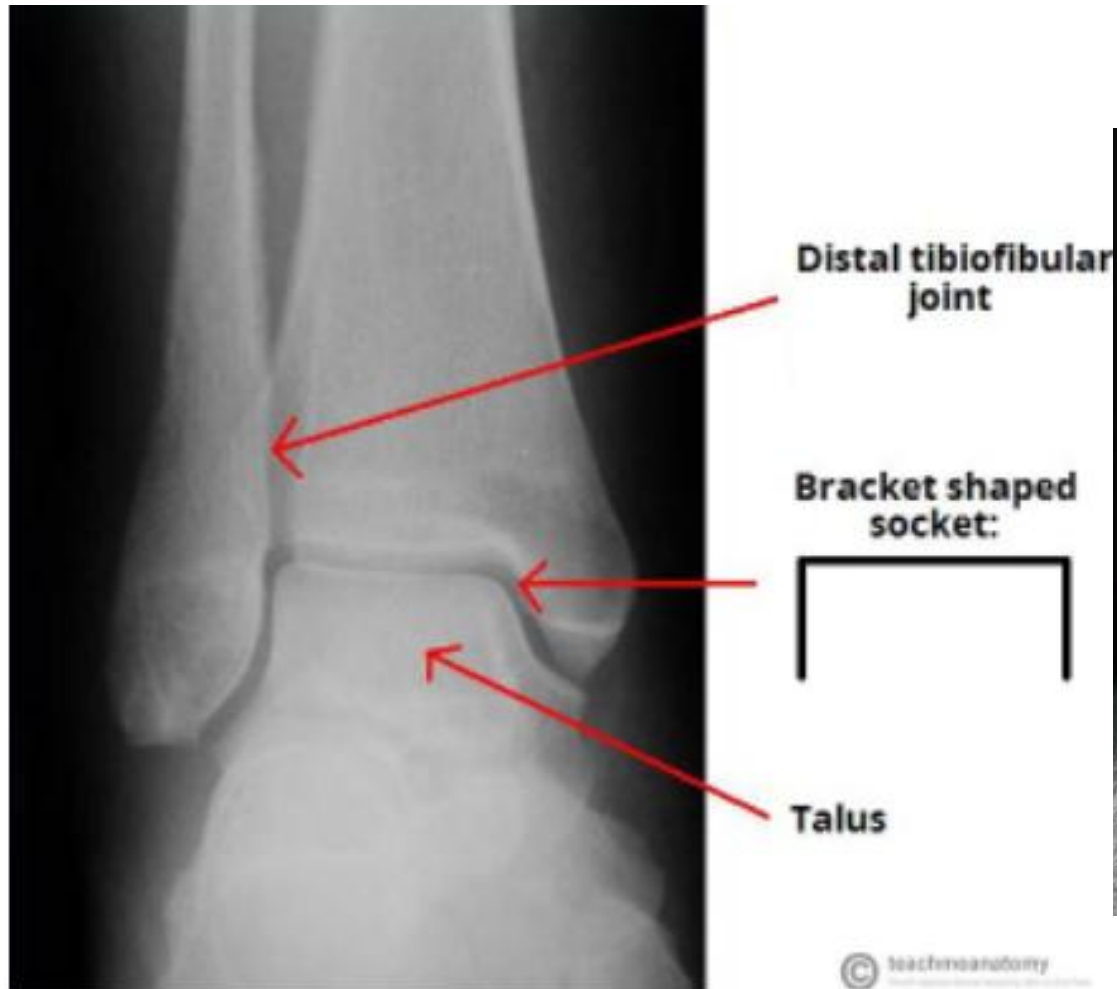


## Medial ligaments

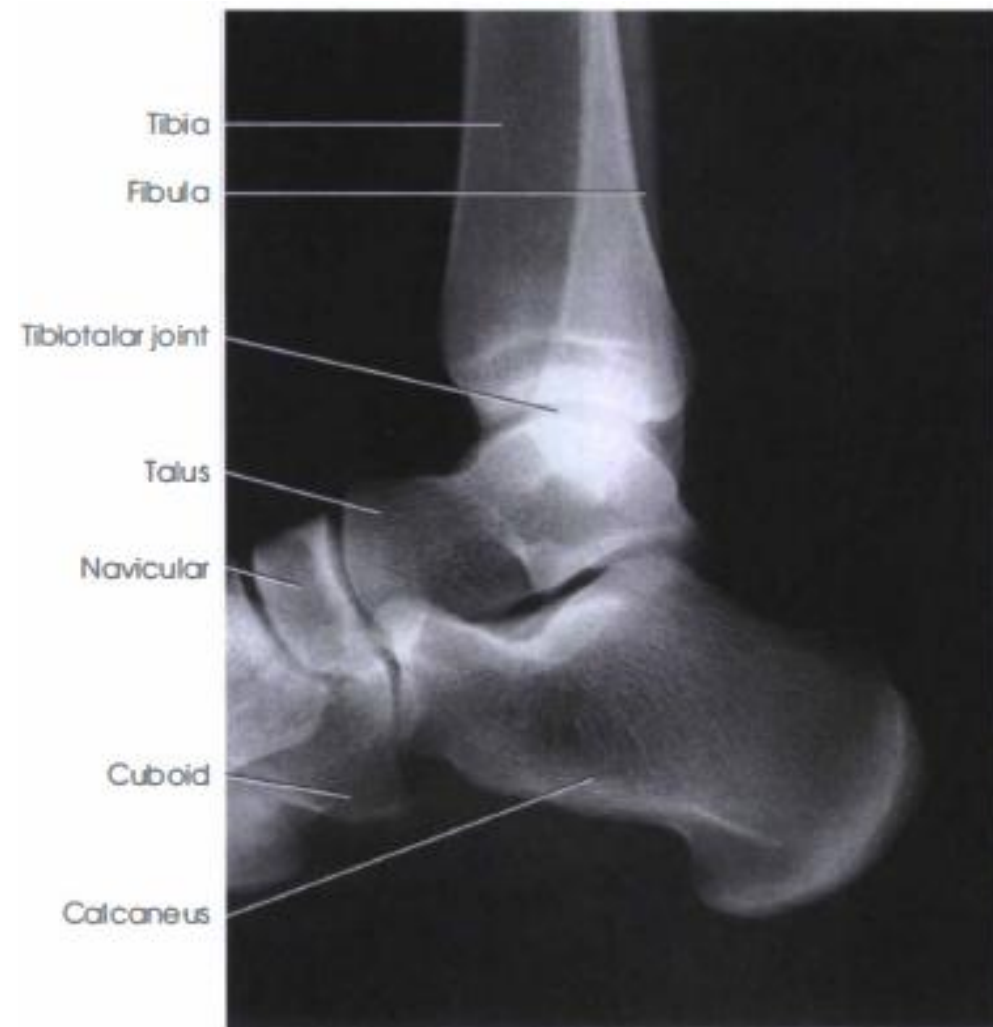
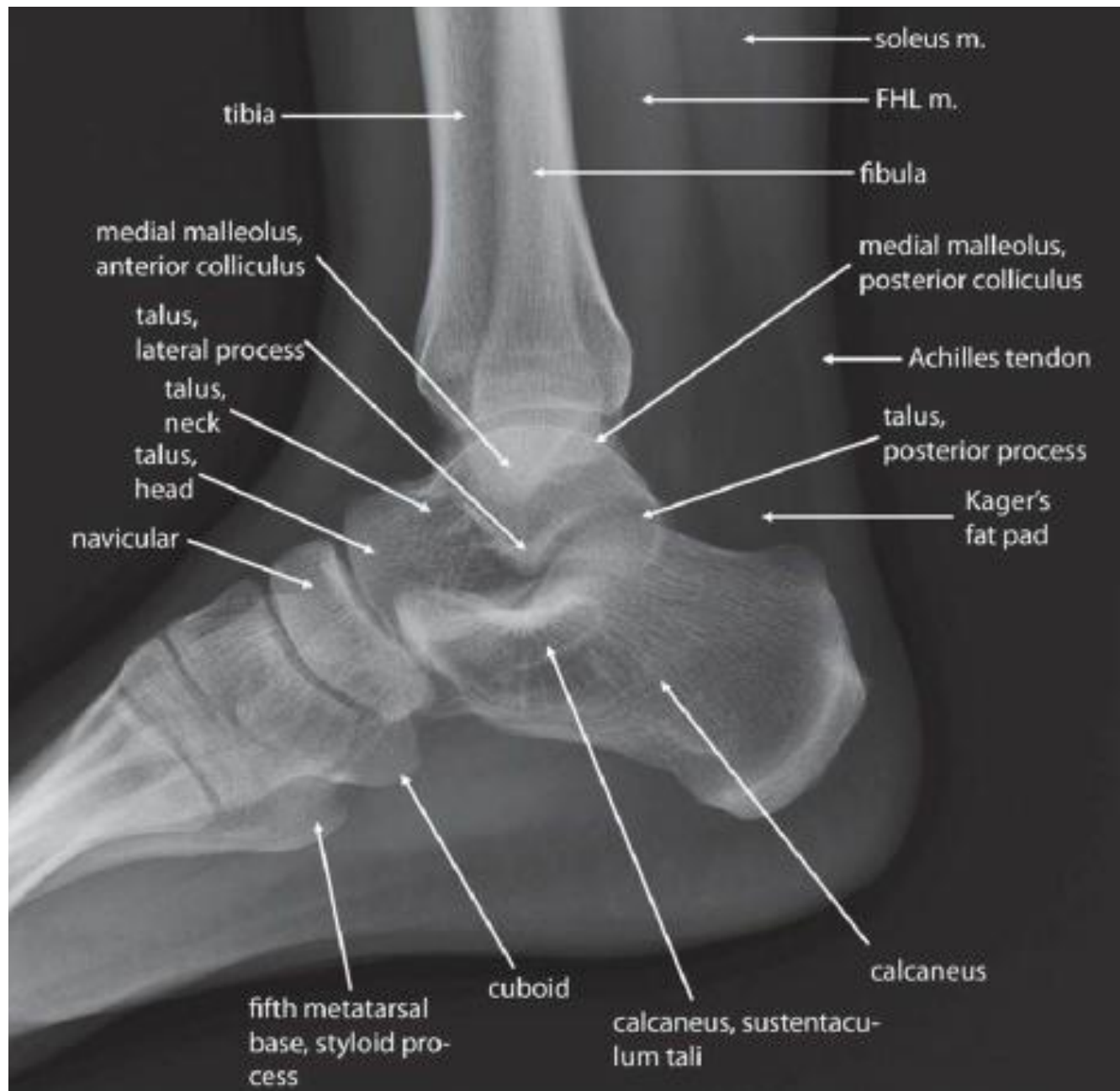


# Radiological features of the ankle joint

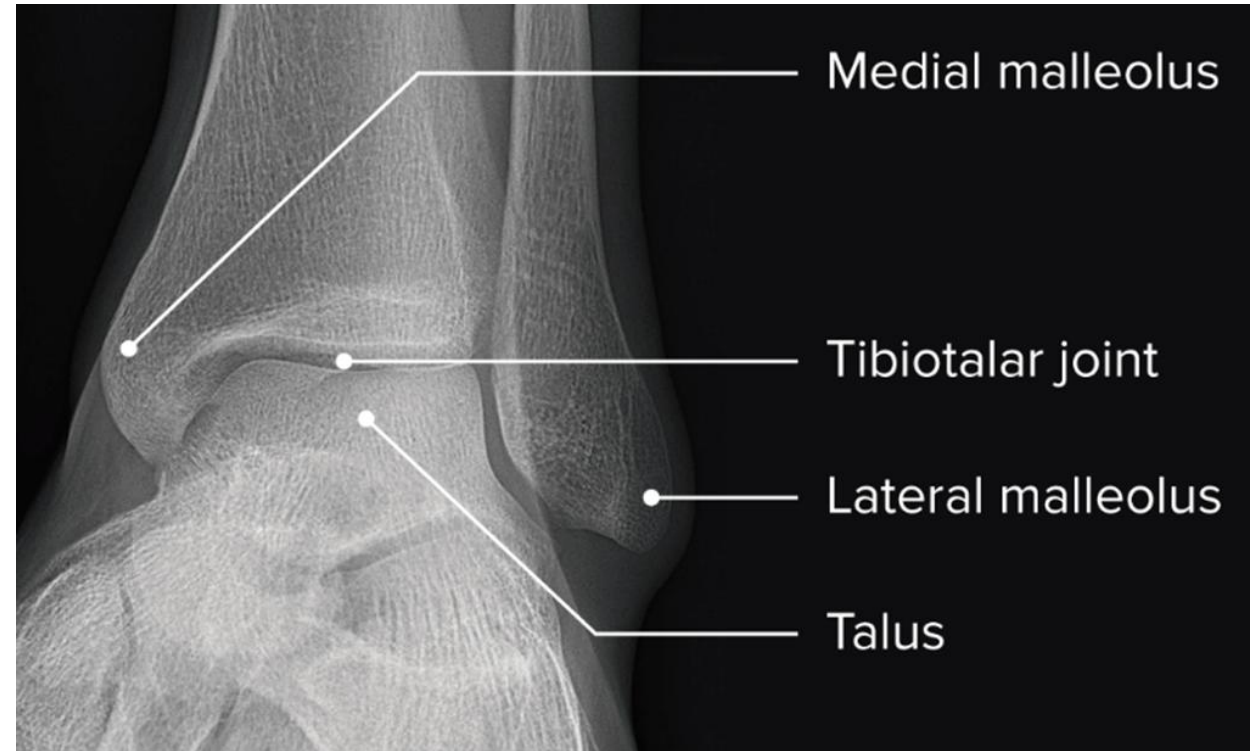






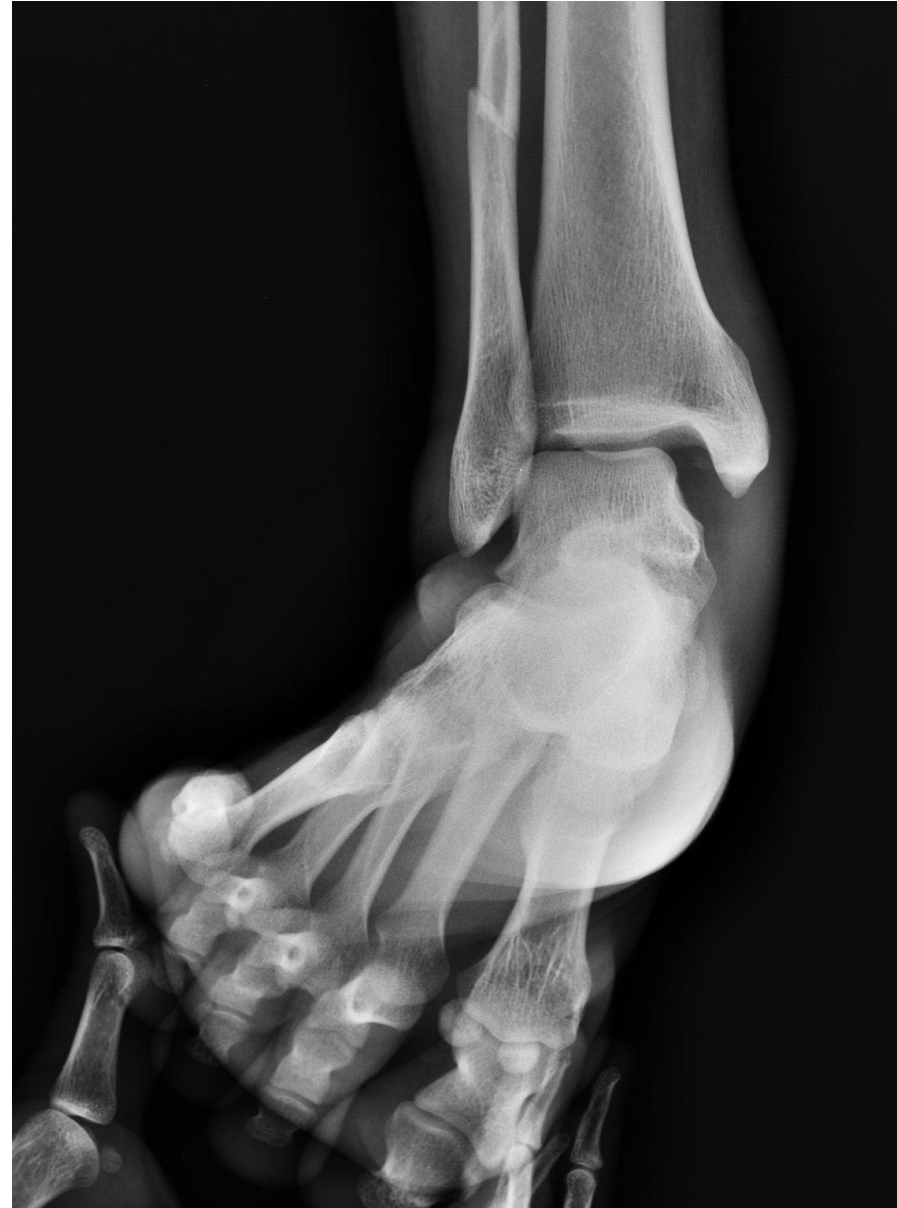# Plain radiographs of Ankle joint

- On AP radiographs
- The tibiotalar **surfaces** are seen to be parallel to each other and **perpendicular** to the shaft of the tibia.
- The articular surfaces of the malleoli on each side are symmetrical about a line through the shaft of the tibia, **each making an equal angle with the inferior surface of the tibia**



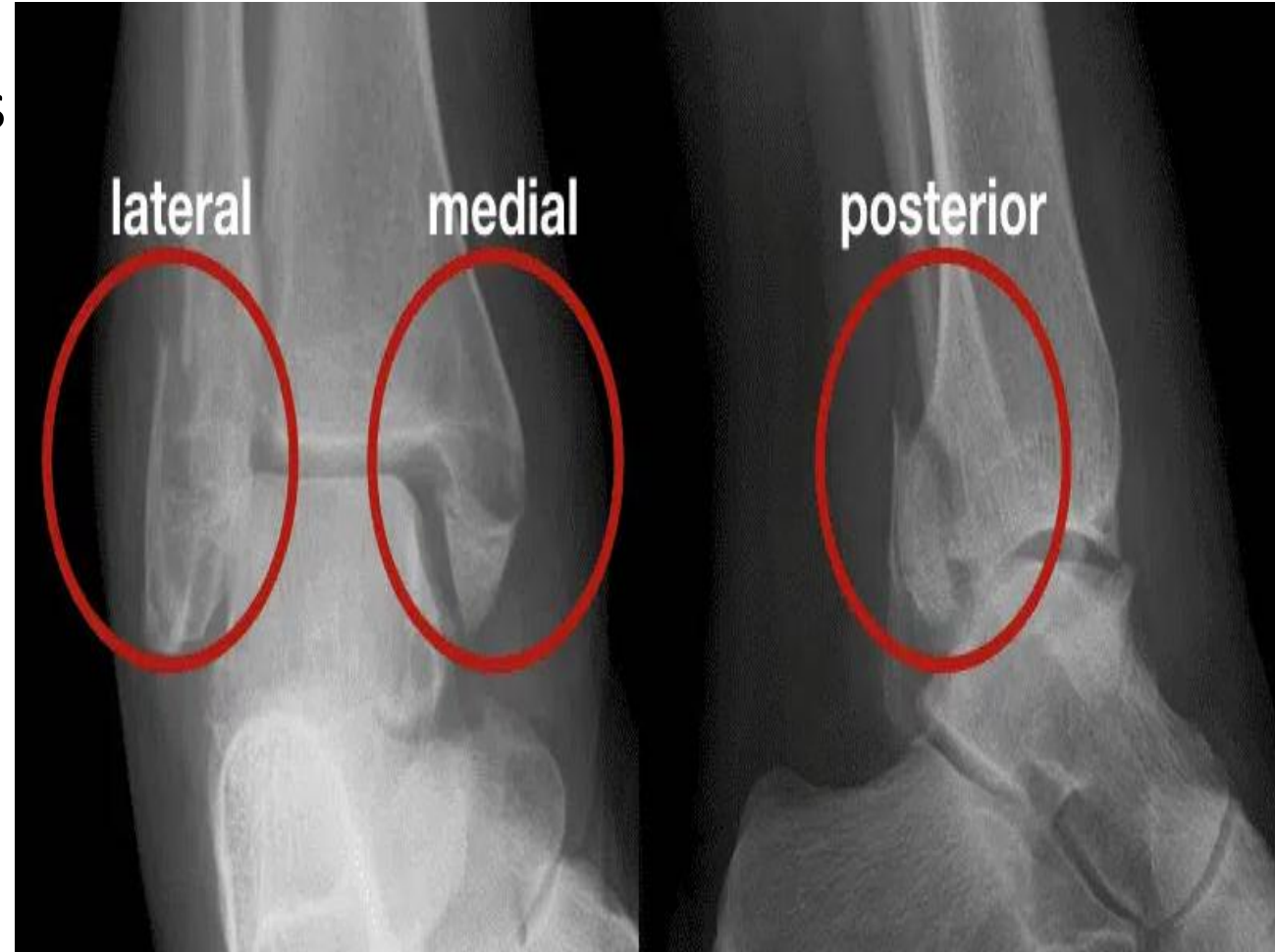
# X ray on Stress View

- The **medial and lateral ligaments of the ankle joint** are not visible on plain radiographs.
- **Stress views** Where the distance between the medial malleolus and the talus is increased ,this means disruption of the deltoid ligament. Where there is increased distance between the lateral malleolus and the talus without bony injury this is due to disruption of the lateral ligaments.



# Trimalleolar fracture

- The term **trimalleolar fracture** is sometimes used, although there are only two malleoli. The third 'malleolus' is the posterior lip of the tibial articular surface.

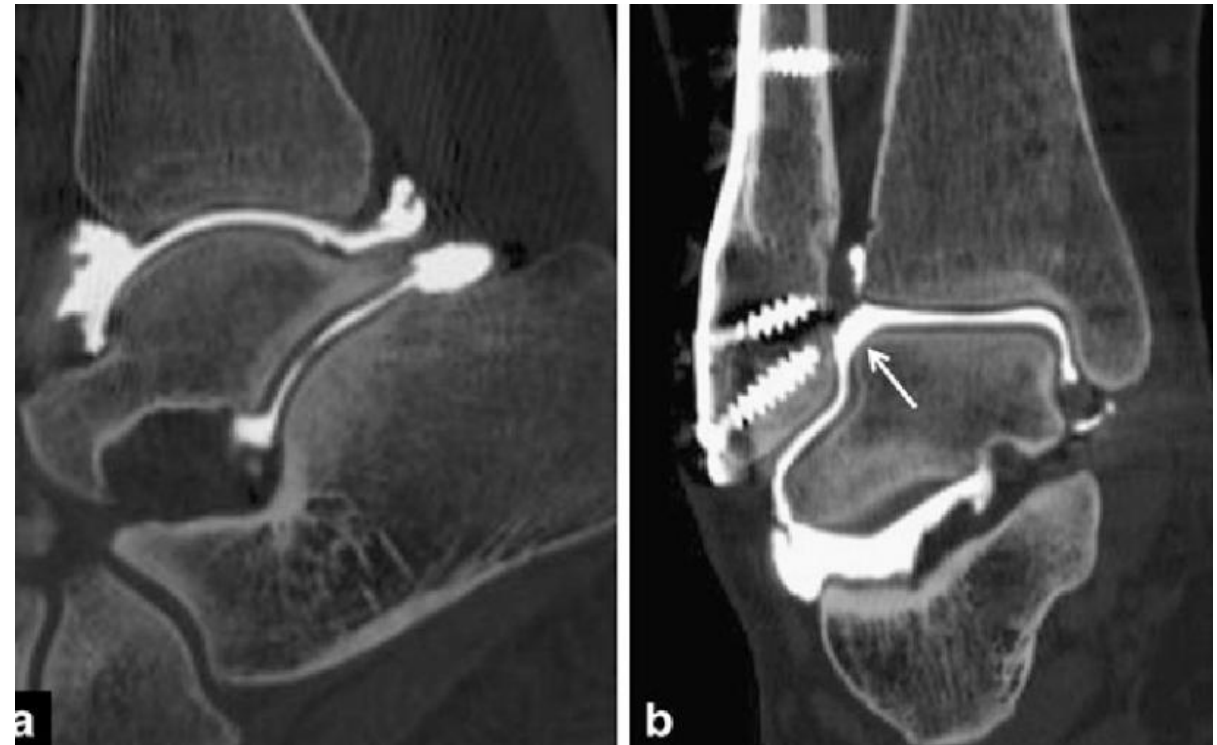


- **Arthrography**

- The synovial cavity is outlined by injection of contrast and the integrity of the medial and lateral ligaments can be assessed The normal articular surfaces are seen to be smooth and parallel

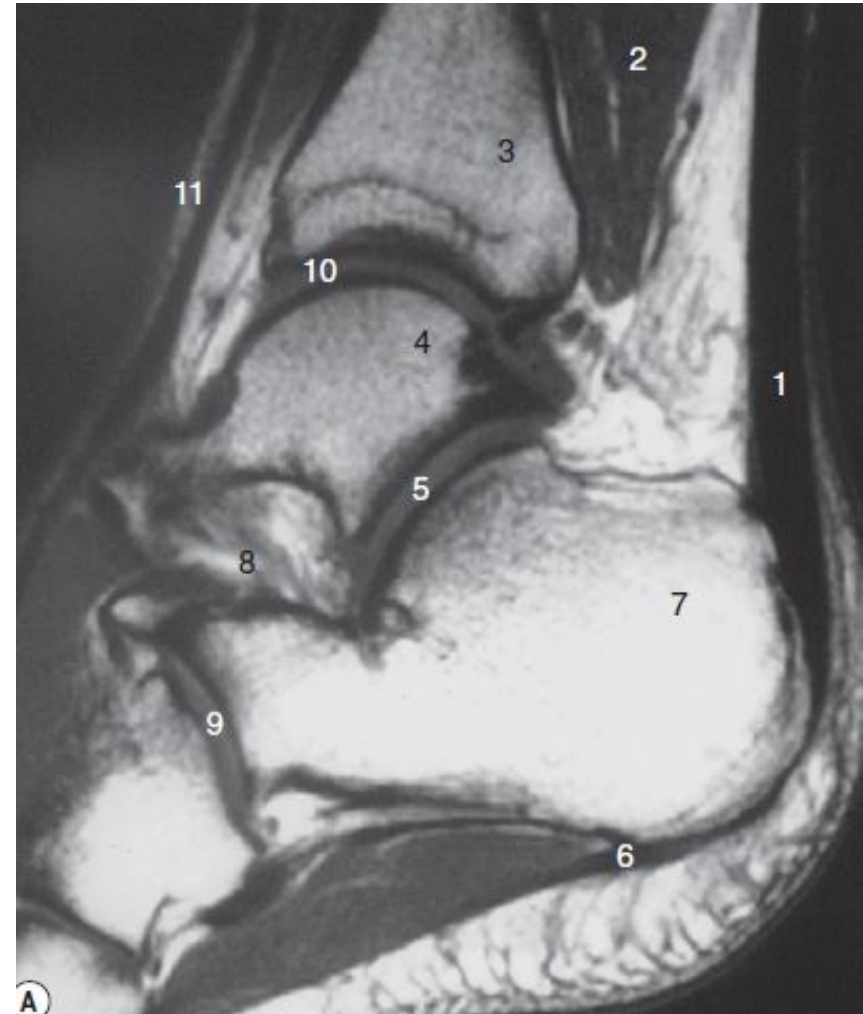- **Computed tomography**

- This can be combined with arthrography to assess the bony components of the ankle joint
- Direct coronal and axial images are routinely acquired in slices 2 mm thick



# Magnetic resonance imaging

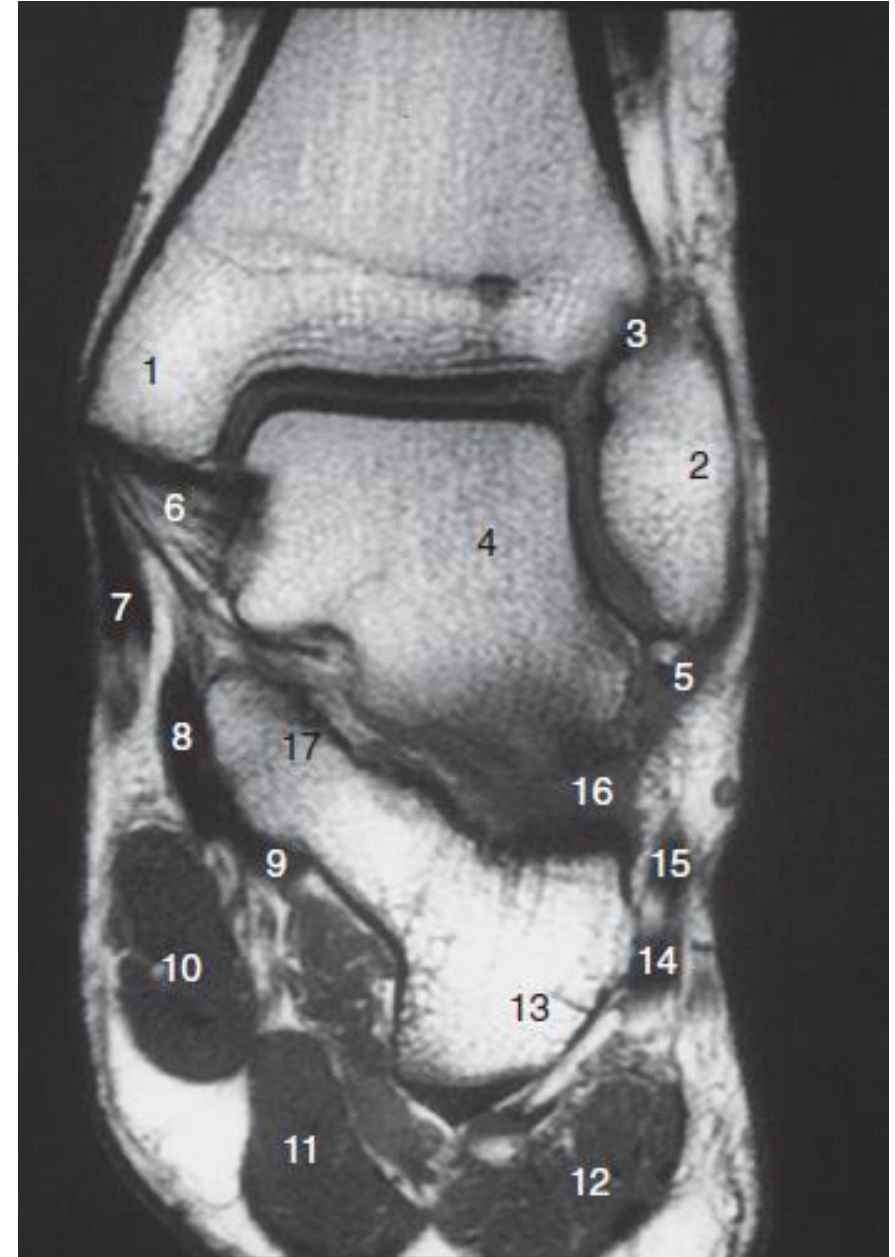
- This technique is particularly useful for soft tissues, especially ligaments and tendons.
- The Achilles tendon can be seen inserting into the posterior aspect of the calcaneus, separated from the posterior surface of the tibia by a fat pad
- The cartilaginous surface of the articulating bones can be visualized directly.





# The ankle ligaments

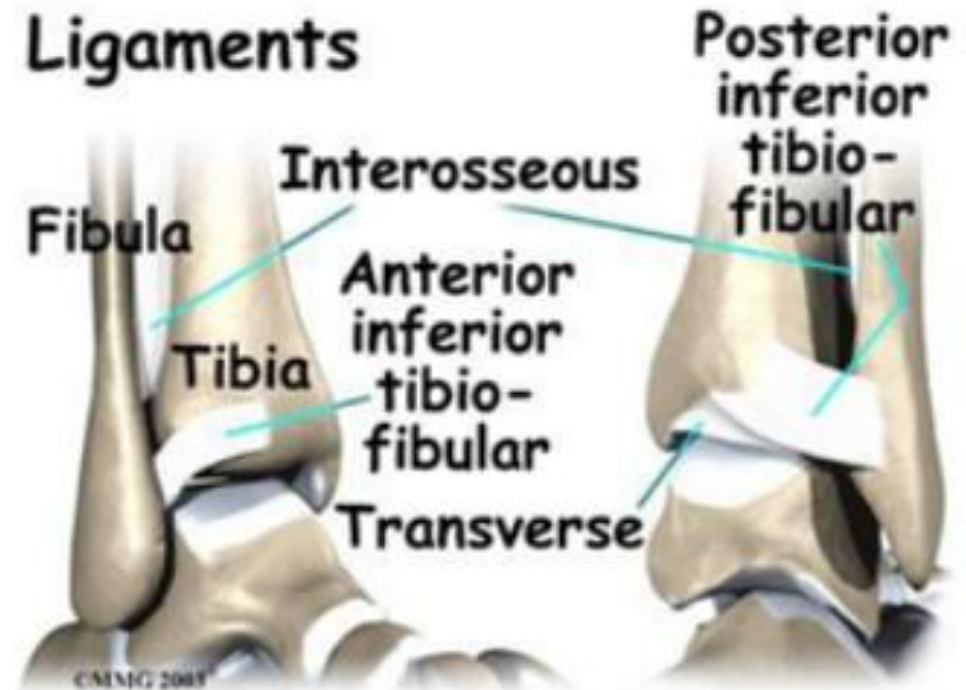
- There are four major ligamentous stabilizers in the foot and ankle:
- the lateral collateral ligament.
- the medial collateral ligament (the deltoid ligament).
- the syndesmotic complex and
- the interosseous ligament (talocalcaneal ligament) in the sinus tarsi





# The syndesmosis.

- Syndesmosis is the term used to describe the three stabilizing components of the inferior tibiofibular articulation: the anterior and posterior tibiofibular ligaments (ATIF, PTIF) and the interosseous membrane Injury to the syndesmosis is extremely uncommon in the absence of a fracture
- Injury to the syndesmosis usually involves rupture to the anterior tibiofibular ligament and spares the posterior.



# The Achilles tendon

- Formed by merging of the gastrocnemius and soleus tendons, the Achilles tendon extends inferiorly to insert on the dorsal margin of the calcaneus. It is readily visualized on both ultrasound and MRI in the sagittal plane.

