

Department of Radiology Techniques

Radiological Position

The Second Stage



Leg

Lecture 8

Assist. Lecturer

Tariq Nadhim Jassim

Basic Positions of Leg

1- Anterior -Posterior

2- Lateral

Cassette out – Bucky (14x17 Inch)

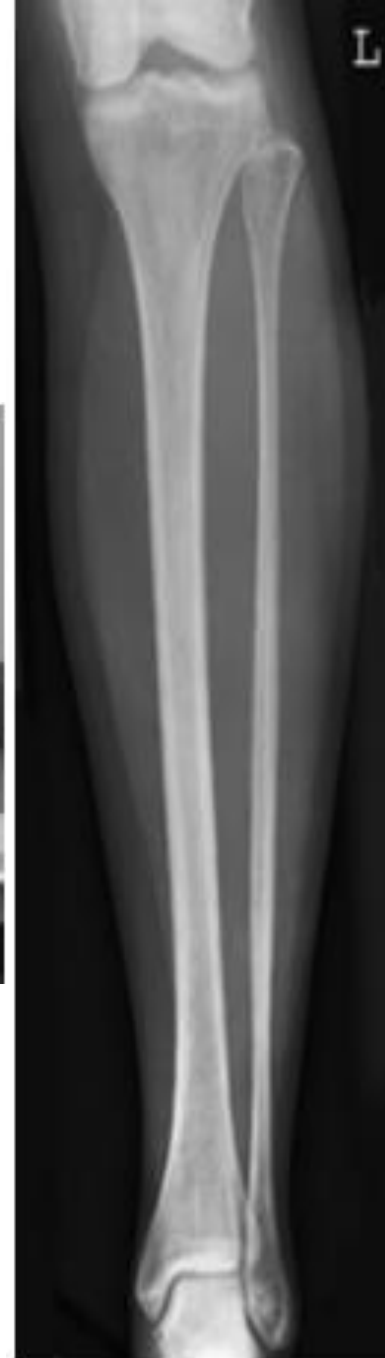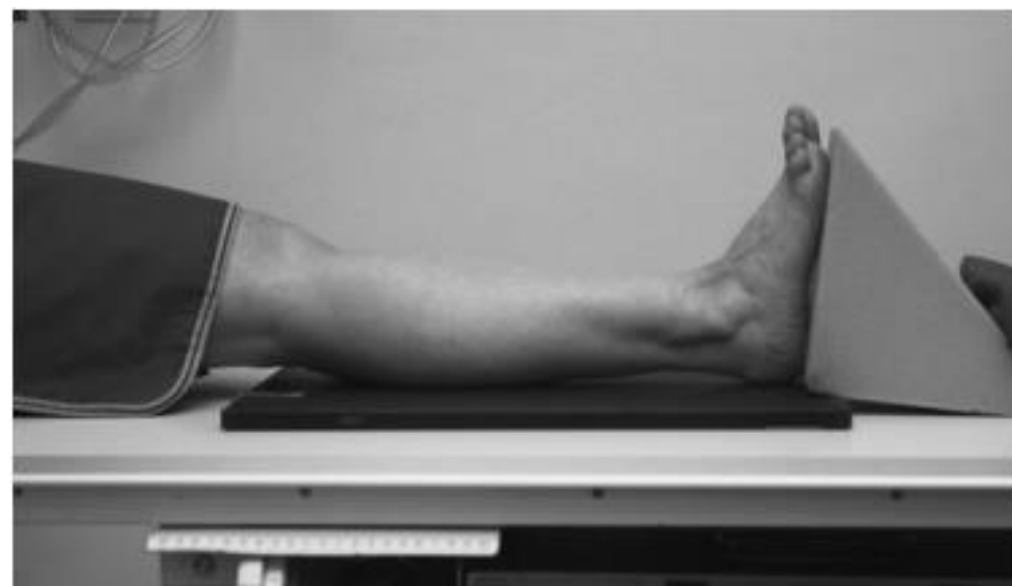Antero-posterior (Basic)

Position of patient and cassette

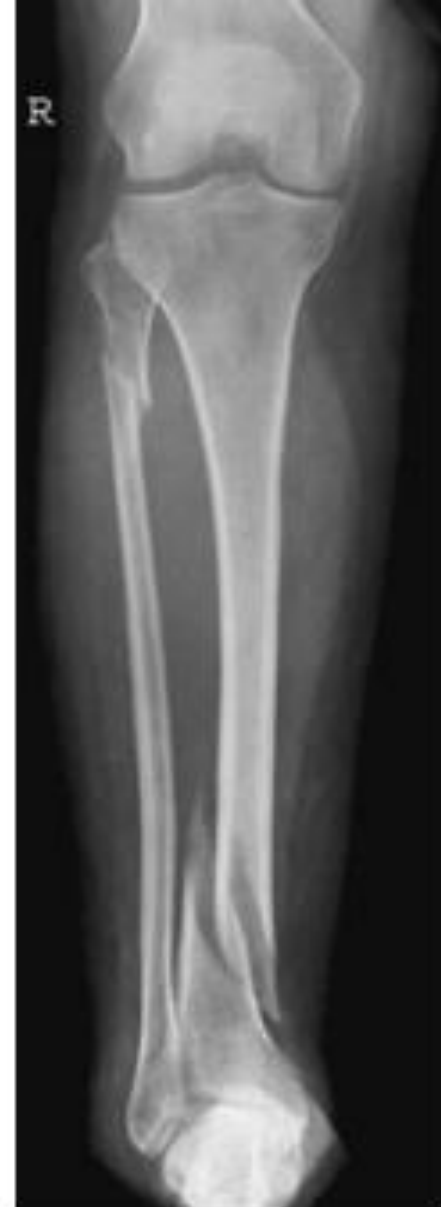- The patient is either supine or seated on the X-ray table, with both legs extended.
- The ankle is supported in dorsiflexion by a firm 90-degree pad placed against the plantar aspect of the foot. The limb is rotated medially until the medial and lateral malleoli are equidistant from the cassette.
- The lower edge of the cassette is positioned just below the plantar aspect of the heel.

Direction and centering of the X-ray beam

- Centre to the middle of the cassette, with the central ray at right-angles to both the long axis of the tibia and an imaginary line joining the malleoli.



Antero-posterior



Antero-posterior
radiograph showing
fracture of proximal
fibula and distal tibia

Lateral – (Basic)

Position of patient and cassette

- From the supine/seated position, the patient rotates on to the affected side.
- The leg is rotated further until the malleoli are superimposed vertically.
- The tibia should be parallel to the cassette.
- A pad is placed under the knee for support.
- The lower edge of the cassette is positioned just below the plantar aspect of heel.

Direction and centering of the X-ray beam

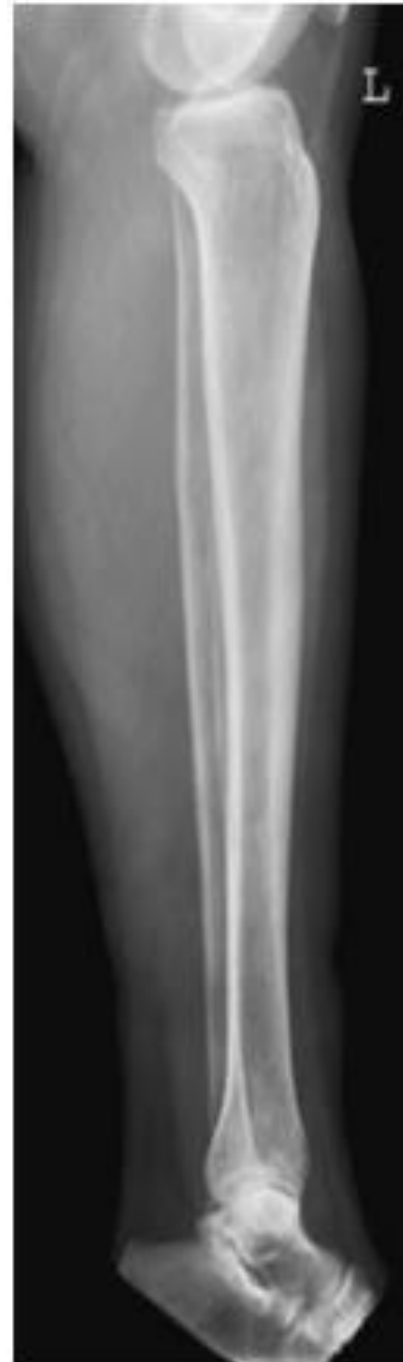- Centre to the middle of the cassette, with the central ray at right-angles to the long axis of the tibia and parallel to an imaginary line joining the malleoli.

Essential image characteristics

- The knee and ankle joints must be included, since the proximal end of the fibula may also be fractured when there is a fracture of the distal fibula.

Notes

- If it is impossible to include both joints on one image, then two films should be exposed separately, one to include the ankle and the other to include the knee. Both images should include the middle third of the lower leg, so the general alignment of the bones may be seen.
- If it is impossible for the patient to rotate on to the affected side, then the cassette should be supported vertically against the medial side of the leg and the beam directed horizontally to the middle of the cassette.



Lateral

Proximal tibio-fibular joint

Basic projections

Either a **lateral oblique** or an **anterior oblique projection** is taken to demonstrate the tibio-fibular articulation **Cassette out – Bucky (10x12 Inch)**.

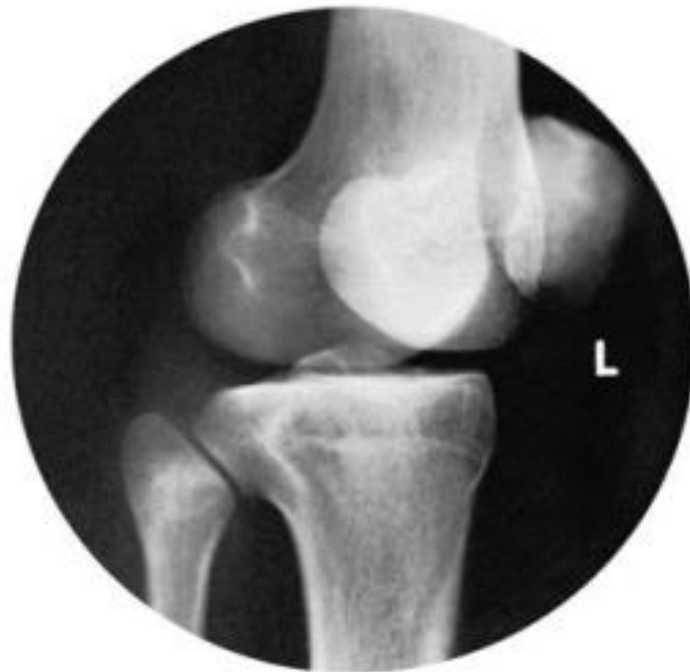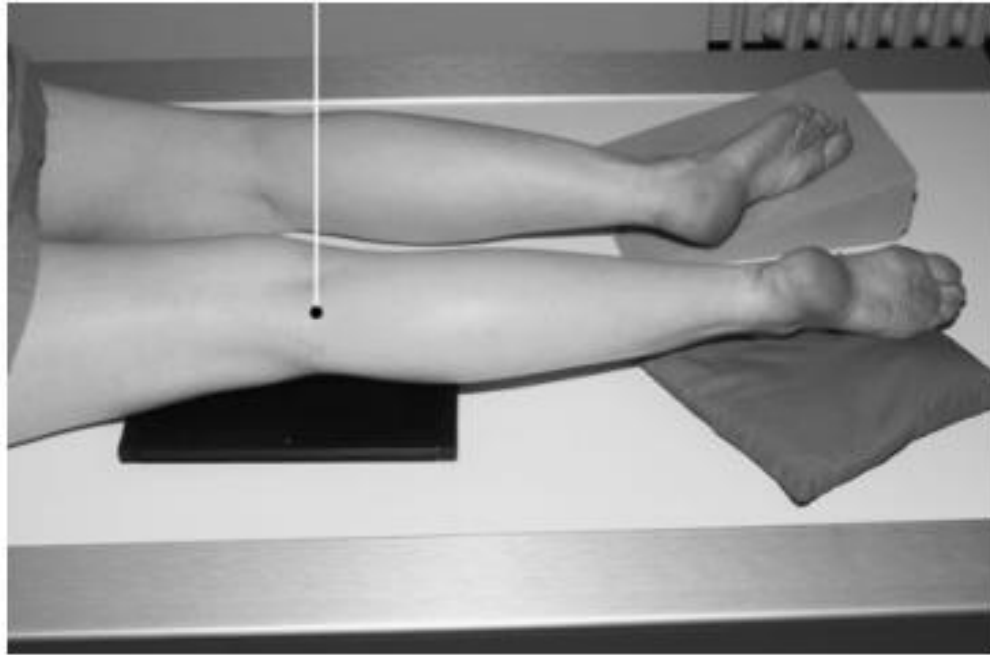
Lateral oblique – Basic

Position of patient and cassette

- The patient lies on the affected side, with the knee slightly flexed.
- The other limb is brought forward in front of the one being examined and supported on a sandbag.
- The head of the fibula and the lateral tibial condyle of the affected side are palpated and the limb rotated laterally to project the joint clear of the tibial condyle.
- The Centre of the cassette is positioned at the level of the head of the fibula.

Direction and centering of the X-ray beam

- The vertical central ray is directed to the head of the fibula.



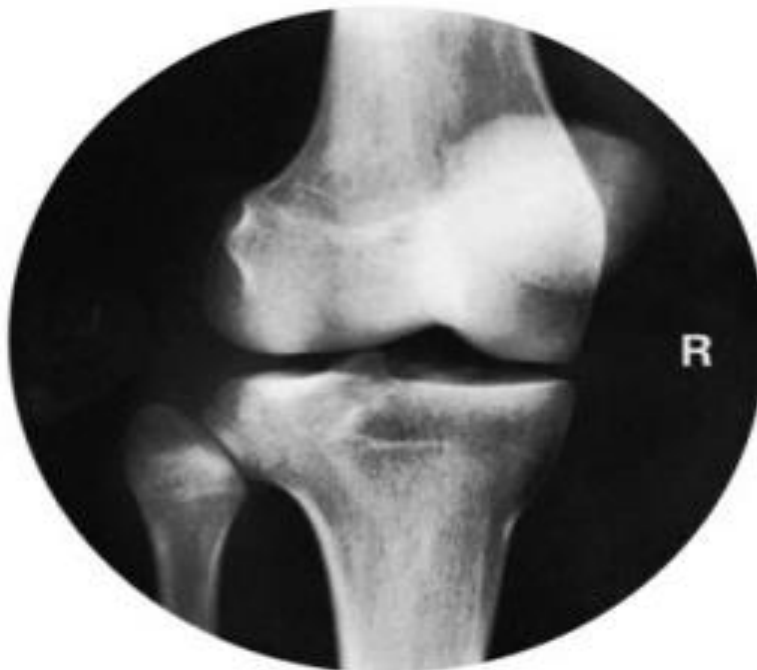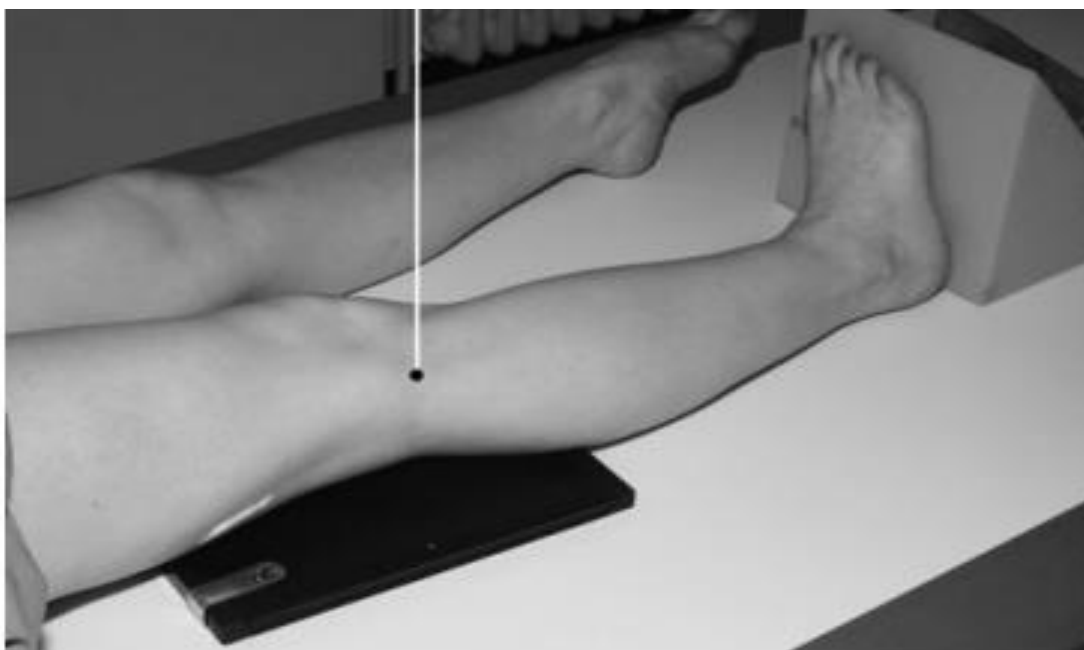
Antero-posterior oblique

Position of patient and cassette

- The patient is either supine or seated on the X-ray table, with both legs extended.
- Palpate the head of fibula and the lateral tibial condyle.
- Rotate the limb medially to project the tibial condyle clear of the joint.
- The limb is supported by pads and sandbags.
- The center of the cassette is positioned at the level of the head of the fibula.

Direction and centering of the X-ray beam

- The vertical central ray is directed to the head of the fibula.



Thanks

The word "Thanks" is written in a large, pink, serif font with a subtle texture. It is surrounded by several pink roses and green leaves, some of which are positioned as if they are part of the letters themselves. The background is a solid, light pink color.