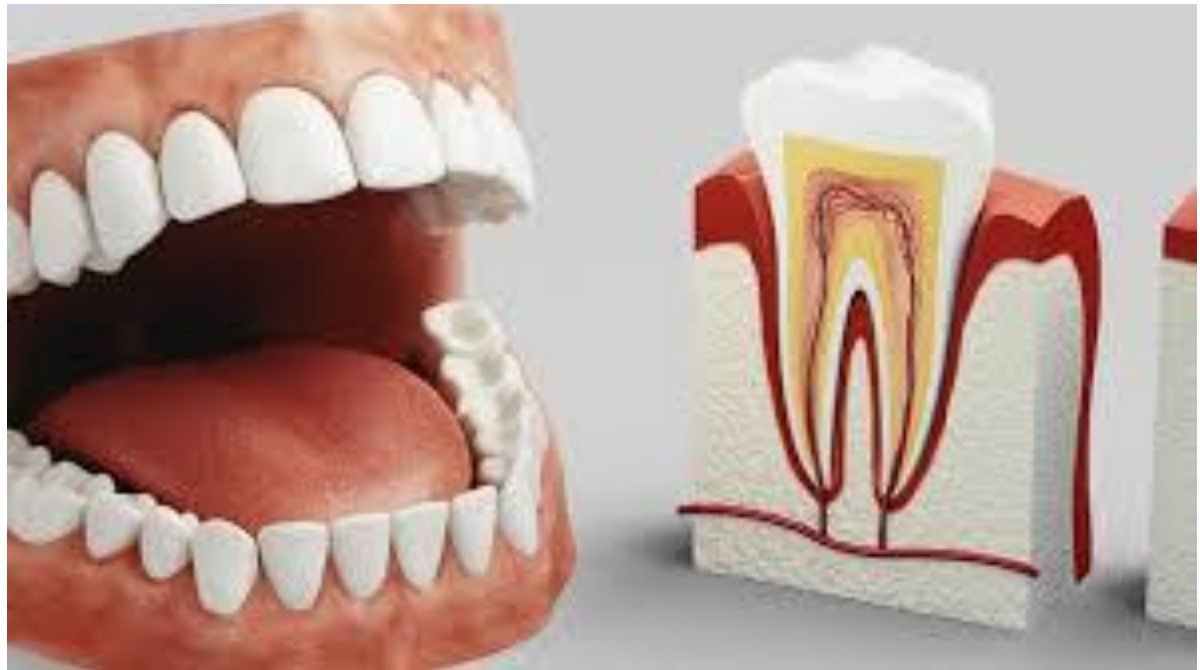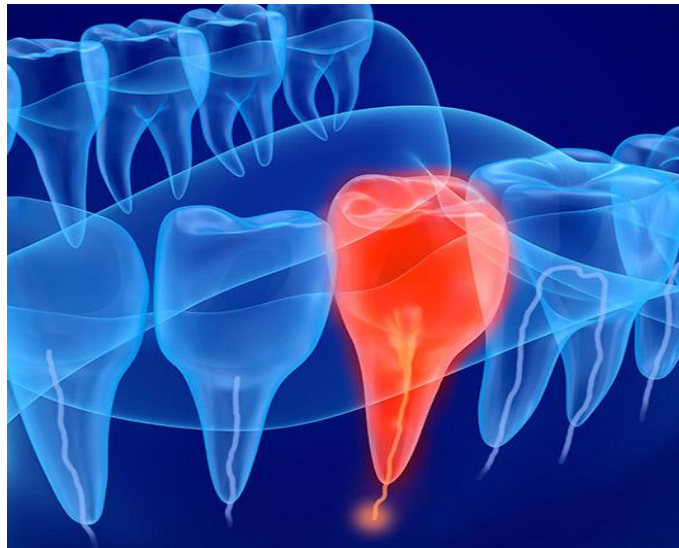


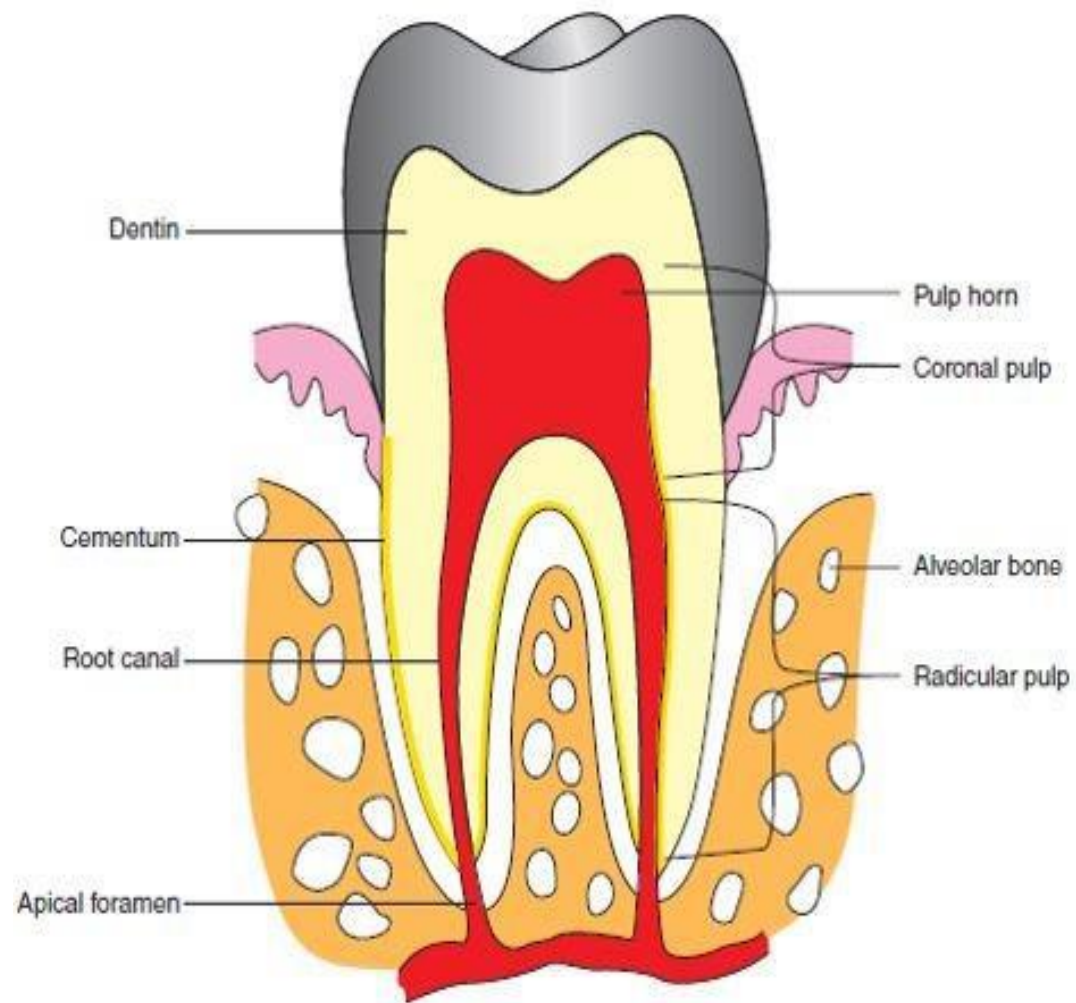
Lec 8

Pulp



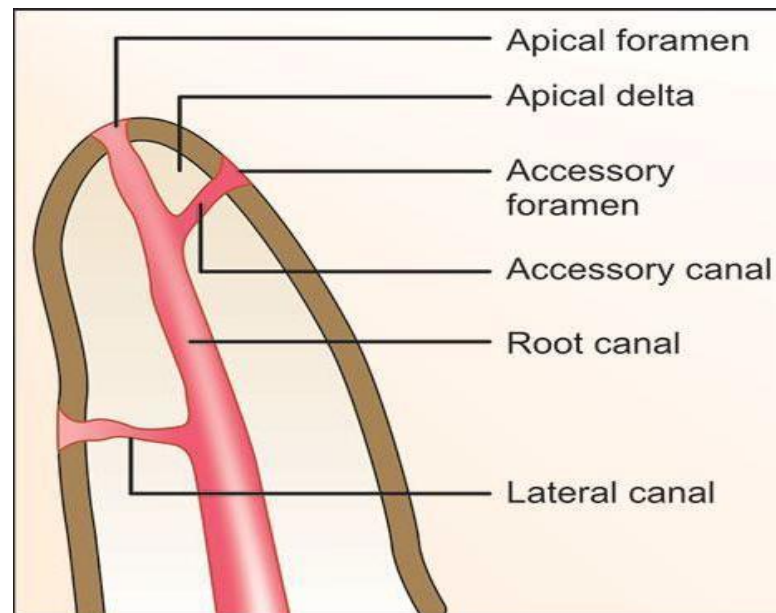
- **Dental pulp** is a richly vascularized and innervated connective tissue of mesodermal origin enclosed by dentin with communications to the periodontal ligament.
- The dental pulp occupies the centre of each tooth and consists of soft connective tissue.
- Pulp is enclosed within the central cavity of a tooth called the pulp chamber, which occupies the space in the centre of the crown and extends through the roots up to the apex.
- Dental pulp is sometimes improperly called the nerve of the tooth



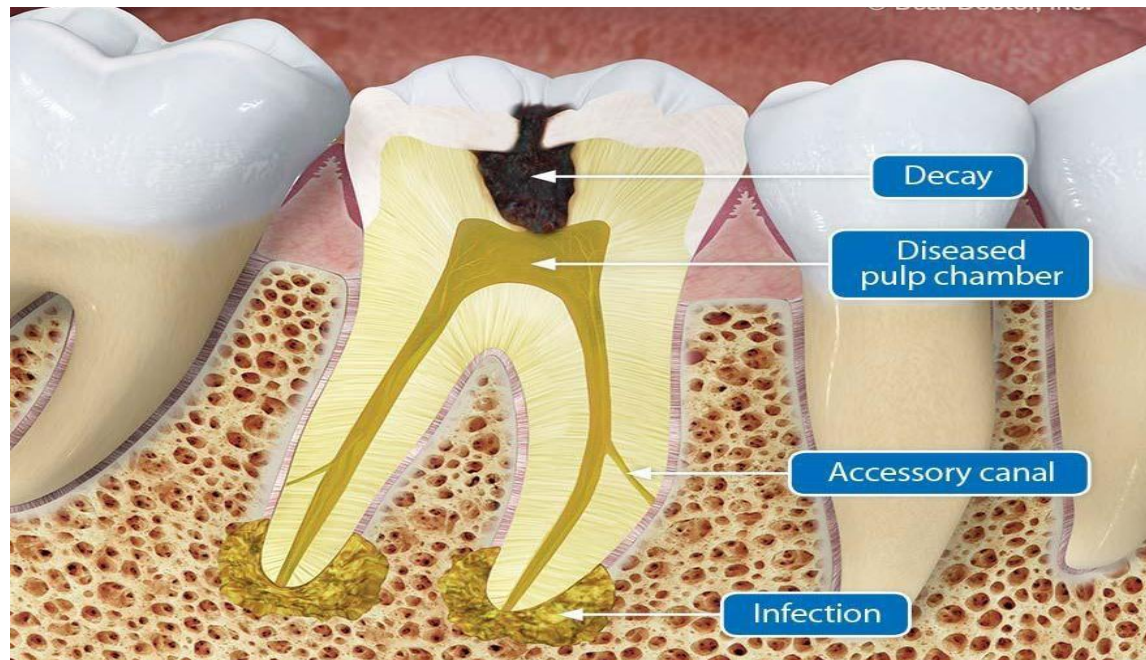


- **Types of Pulp**
- **1. Coronal pulp** : occupies the crown of the tooth and has six surfaces; occlusal, mesial, distal, buccal, lingual and the floor.
- Pulp horns are protrusions of the pulp that extend up into the cusps of the tooth. With age, pulp horns diminish and the coronal pulp decreases in volume due to continued (secondary) dentin formation
- **2. Radicular pulp** : extends from the cervical region of the crown down to the root apex. Molars and premolars exhibit multiple radicular pulps. This pulp is tapered, it also decreases in volume with age due to continued dentin formation. The radicular portions of the pulp are continuous with the periapical connective tissues through the apical foramen or foramina

- **Apical foramen** The average size of the apical foramen of the maxillary teeth in the adult is 0.4 mm. In the mandibular teeth it is slightly smaller, being 0.3 mm in diameter. Sometimes the apical opening is found on the lateral side of the apex, although the root itself is not curved. Frequently, there are two or more foramina separated by a portion of dentin and cementum or by cementum only



- **Accessory canals** leading from the radicular pulp laterally through the root dentin to the periodontal tissue may be seen anywhere along the root but are **most numerous in the apical third of the root.**



- **STRUCTURAL FEATURES**
- **Zones of the Pulp:**
 - **Odontogenic zones:** This is a peripheral aspect of dental pulp, which contains the odontoblast cells.
 - **Cell-free zone or zone of Weil :** This region does not contain cells but contains numerous bundles of fibers, numerous capillaries and nerves.
 - **Cell-rich zone:** This contains numerous fibroblasts (the predominant cell type of pulp) and undifferentiated mesenchymal cells are also present in the pulp and can give rise to new odontoblasts, fibroblasts or macrophages.
- **Pulp core:** This contains Raschkow plexus of nerves and main blood vessels in the pulp.

- **Histology of dental pulp:**
- Dental pulp is a loose connective tissue ,so it contains the components common to all connective tissues such as:
- **Cells:** Which include fibroblasts and undifferentiated mesenchymal cells as well as other cell types (macrophages, lymphocytes, etc.) required for the maintenance and defense of the tissue . Also odontoblasts comprise the outermost region of the pulp, immediately adjacent to the dentin component of the tooth.
- **Fibrous matrix:** Which contain type I and II collagen fibers .
- **Ground substance:** it represents the environment that surrounds both cells and fibers of the pulp and is rich in proteoglycans, glycoproteins and large amounts of water.

- **Cells of the pulp**
- 1.Odontoblasts cells
- 2.Fibroblast cells
- 3.Undifferentiated cells
- 4.Defence cells
- **1.Odontoblasts cells**
- Peripheral cell layer of the pulp area
- Located immediately subjacent to the predentin
- Pass through the predentin into the dentin
- Tall columnar cell
- Have large process extending in to dentin
- Function of the odontoblast cell synthesis of collagen and organic substance
- **2.Fibroblast cells**
- **The pulp organ is consist of specialized connective tissue .**
- **Fibroblasts are the most numerous cell type in the pulp, they function in collagen fiber formation throughout the pulp during the life of the tooth.**
- **They have the typical stellate shape and extensive processes that contact and joined by intercellular junctions to the processes of other fibroblasts.**

- **3.Undifferentiated cells**
- **Undifferentiated mesenchymal cells are the primary cells in the very young pulp, but a few are seen in the pulps after root completion.**
- **They are found along pulp vessels, in the cell-rich zone and scattered throughout the central pulp.**
- **4.Defence cells**
- They play a major role in inflammation and immunity
- They are recruited from the blood stream and remain as transient inhabitant in the pulp
- **These cells are**
- Macrophage cells
- Mast cells
- Plasma cells
- Lymphocyte cells neutrophil,basophil,eosinophil,and monocytes

- **Functions of Dental Pulp:**

- The primary function of dental pulp is ***providing vitality to the tooth***. Dental pulp also has several other functions:-
- **Inductive:** very early in development the future pulp interacts with surrounding tissues and initiates tooth formation.
-
- **Formative:** the odontoblasts of the outer layer of the pulp organ form the dentin that surrounds and protects.
- **Protective:** A direct response to cutting procedures, caries, extreme pressure, etc., involves the formation of ***reparative dentin*** by the odontoblast layer of the pulp.
- **Age- Changes in the Pulp:**
- Specific changes occur in dental pulp with age ,which include:
- less cellular
- more fibrous
- overall reduction in volume due to the continued deposition of dentin (secondary or reparative).
- increase the number of pulp stones .
- **Pulp Stones or denticles:**

- Small calcified bodies are present in up to 50% of the pulp of newly erupted teeth and in over 90% of older teeth. These bodies are classified by either their structures or locations:
- **1. Structure of the pulp stones :**
- A calcified body containing tubular dentin is referred to as a *"true" pulp stone*.
- **True pulp stones exhibit radiating striations of dentinal tubules.**
- **Irregularly calcified tissue as such is referred to as a *"false" pulp stone*.** False pulp stones generally exhibit either a hyaline-like homogeneous morphology or appear to be composed of concentric lamellae.
- **Locations of the pulp stones:**
 - Free in the pulp
 - Embedded inside the dentin
 - Attached to the dentin