



**Al-Mustaqbal University
College of Engineering
Biomedical Engineering Department**



Subject Name: Medical Measurements Lab 2

4th Class, Second Semester

Subject Code: [MU0114208]

Academic Year: 2025-2026

Lecturer: Assist lect. Abdullah Qays Hashim

Eng: Ikram Falah Hadi

Email: abdullah.qays.hashim@uomus.edu.iq

Email: ikram.falah.hadi@uomus.edu.iq

Lecture No.: - 1 -

Lecture Title: [Introduction to Electrocardiography]

Introduction to Electrocardiography

An electrocardiogram (ECG or EKG) is a graphical recording of the electrical events occurring within the heart. In a healthy heart there is a natural pacemaker in the right atrium (the *sinoatrial node*) which initiates an electrical sequence. This impulse then passes down natural conduction pathways between the atria to the atrioventricular node and from there to both ventricles. The natural conduction pathways facilitate orderly spread of the impulse and coordinated contraction of first the atria and then the ventricles. The electrical journey creates unique deflections in the EKG that tell a story about heart function and health (Figure 1). Even more information is obtained by looking at the story from different angles, which is accomplished by placing electrodes in various positions on the chest and extremities. A positive deflection in an EKG tracing represents electrical activity moving toward the active lead (the green lead in this experiment).

Five components of a single beat are traditionally recognized and labeled P, Q, R, S, and T. The P wave represents the start of the electrical journey as the impulse spreads from the sinoatrial node downward from the atria through the atrioventricular node and to the ventricles. Ventricular activation is represented by the QRS complex. The T wave results from ventricular repolarization, which is a recovery of the ventricular muscle tissue to its resting state. By looking at several beats you can also calculate the rate for each component.

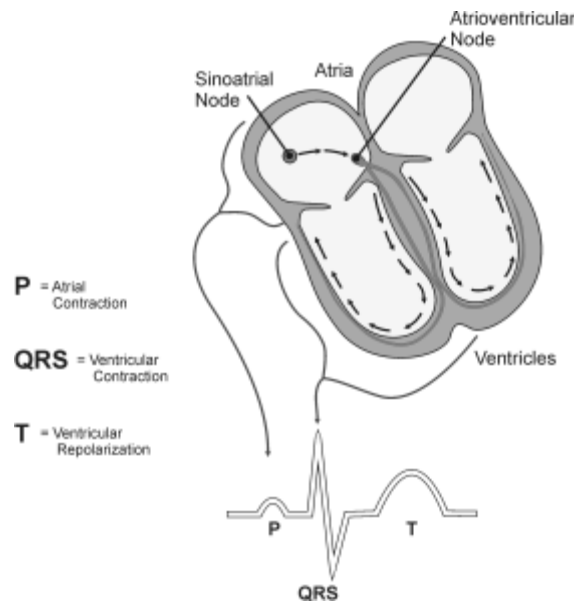


Figure 1

Doctors and other trained personnel can look at an EKG tracing and see evidence for disorders of the heart such as abnormal slowing, speeding, irregular rhythms, injury to muscle tissue (*angina*), and death of muscle tissue (*myocardial infarction*). The length of an interval indicates whether an impulse is following its normal pathway. A long interval reveals that an impulse has been slowed or has taken a longer route. A short interval reflects an impulse which followed a shorter route. If a complex is absent, the electrical impulse did not rise normally, or was blocked at that part of the

heart. Lack of normal depolarization of the atria leads to an absent P wave. An absent QRS complex after a normal P wave indicates the electrical impulse was blocked before it reached the ventricles. Abnormally shaped complexes result from abnormal spread of the impulse through the muscle tissue, such as in myocardial infarction where the impulse cannot follow its normal pathway because of tissue death or injury. Electrical patterns may also be changed by metabolic abnormalities and by various medications.

In this experiment, you will use the EKG sensor to make a five second graphical recording of your heart's electrical activity, and then switch the red and green leads to simulate the change in electrical activity that can occur with a myocardial infarction (heart attack). You will identify the different components of the waveforms and use them to determine your heart rate.

OBJECTIVES

- Obtain graphical representation of the electrical activity of the heart over a period of time.
- Learn to recognize the different wave forms seen in an EKG and associate these wave forms with activity of the heart.
- Determine the heart rate by determining the rate of individual wave forms in the EKG.
- Compare wave forms generated by alternate EKG lead placements.

MATERIALS

Chromebook, computer, **or** mobile device
Graphical Analysis 4 app
Go Direct EKG
electrode tabs

PROCEDURE

Part I Standard limb lead EKG

1. Launch Graphical Analysis. Connect Go Direct EKG to your Chromebook, computer, or mobile device.
2. Attach three electrode tabs to your arms as shown in Figure 2. Place a single patch on the inside of the right wrist, on the inside of the right upper forearm (distal to the elbow), and on the inside of the left upper forearm (distal to elbow).

Introduction to Electrocardiography

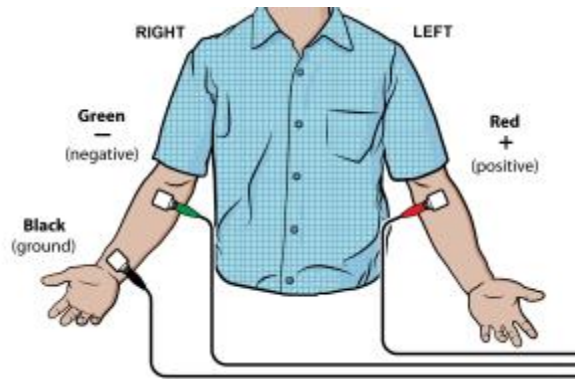


Figure 2

3. Connect the EKG clips to the electrode tabs as shown in Figure 2. Sit in a relaxed position in a chair, with your forearms resting on your legs or on the arms of the chair. When you are properly positioned, have someone click or tap Collect to start data collection. Data collection will stop after 3 seconds.
4. Determine the length of each of the intervals listed in Table 1. Use Figure 3 as your guide when determining these intervals.
 - a. Click or tap the data point at the beginning of the interval and record the time component of this point.
 - b. Click or tap the point at the end of the interval and record the time component of this point.
 - c. Determine the difference between the two time values and record this value to the nearest 0.01 s as the duration of the interval in Table 1.
5. Calculate the heart rate in beats/min using the EKG data. Record the heart rate to the nearest whole number in Table 1.

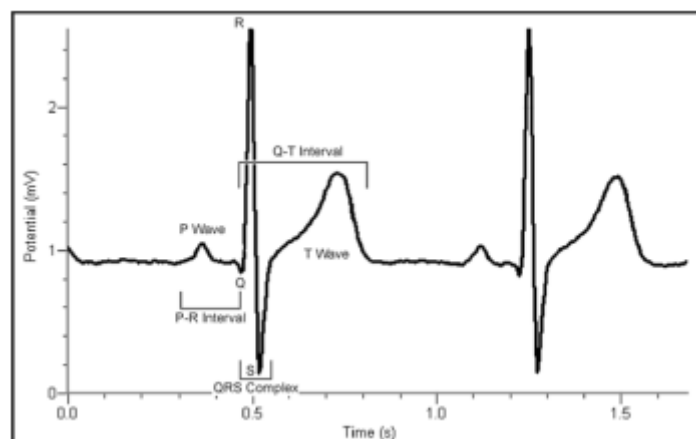


Figure 3

- **P-R interval:** time from the beginning of P wave to the start of the QRS complex
- **QRS complex:** time from Q deflection to S deflection
- **Q-T interval:** time from Q deflection to the end of the T

Part II Alternate limb lead EKG

6. Exchange the red and green EKG clips so that the green clip is now attached to the electrode tab on the left arm and the red clip is on the right arm. Sit in a relaxed position in a chair, with your forearms resting on your legs or on the arms of the chair. When you are properly positioned, have someone click or tap Collect to start data collection. **Note:** The previous data set is automatically saved.
7. Export, print, or sketch the tracing for alternate limb lead placement only.

DATA

Table 1			
Interval	Beginning time (s)	Ending time (s)	Time (s)
P-R			
QRS			
Q-T			
R-R			

Heart rate (bpm)	
------------------	--

Table 2: Standard Resting Electrocardiogram Interval Times	
P-R interval	0.12 to 0.20 s
QRS interval	less than 0.12 s
Q-T interval	0.30 to 0.40 s

DATA ANALYSIS

Health-care professionals ask the following questions when interpreting an EKG:

- Can all components be identified in each beat?
- Are the intervals between each component and each complex consistent?
- Are there clear abnormalities of any of the wave components?

Using these questions as guides, analyze each of the following three-beat EKG tracings and record your conclusions in Table 3 (indicate presence or absence of the P wave, and whether other intervals and/or shapes are normal or abnormal). The first analysis (a) is done for you.

