



Medical Measurements Lab 2
Asst. lec. Abdullah Qays Hashim
Eng: Ikram Falah Hadi
Biomedical Engineering Department
4th Class, Second Semester
2026-2025



Electrocardiogram (ECG)

- An electrocardiogram records the electrical signals in the heart. It's a common and painless test used to quickly detect heart problems and monitor the heart's health.
- An electrocardiogram — also called ECG— is often done in a health care provider's office, a clinic or a hospital room. ECG machines are standard equipment in operating rooms and ambulances. Some personal devices, such as smartwatches, offer ECG monitoring.

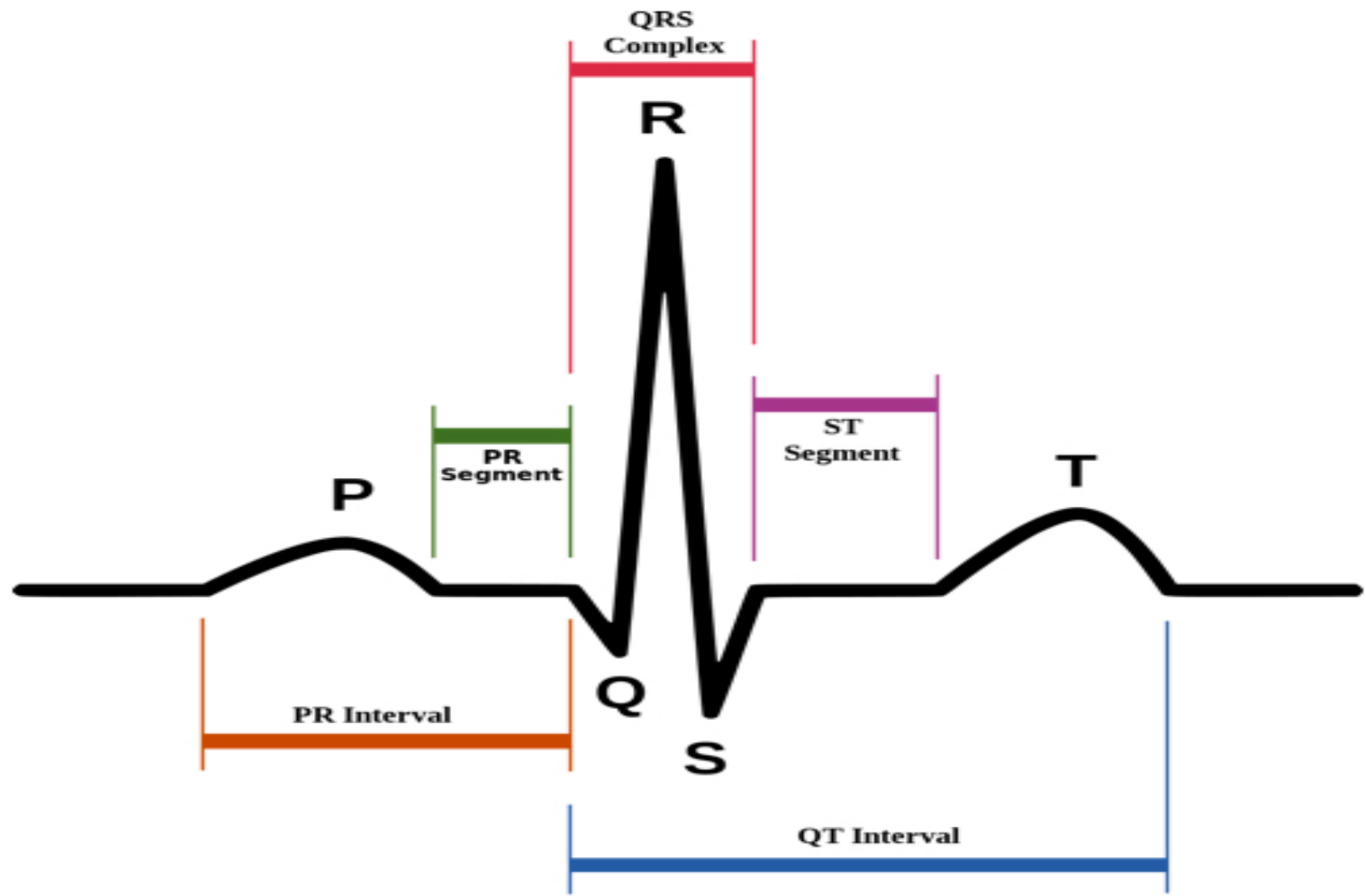
Behavioral Objectives

By the end of this session, the student will be able to:

1. Define the ECG lead system.
2. Differentiate between bipolar leads and unipolar leads.
3. Explain the concept of the Einthoven triangle and identify its components.
4. Identify the placement and names of different ECG leads.
5. Describe the electrical axis of the heart.
6. Determine the mean electrical axis (QRS axis).
7. Interpret normal and abnormal deviations of the electrical axis.

Parts of the ECG explained

- **P waves** :Represents atrial depolarization; begins at the first deflection from the baseline and ends when it returns to the baseline.
- **PR interval** :Represents conduction from the atria to the ventricles; begins at the start of the P wave and ends at the start of the QRS complex.
- **QRS complex** :Represents ventricular depolarization; begins at the start of the Q wave (or R wave if Q is absent) and ends at the end of the S wave.
- **ST segment** :Represents the plateau (isoelectric phase) during ventricular contraction; begins at the end of the QRS complex and ends at the start of the T wave.
- **T wave** :Represents ventricular repolarization; begins at the end of the ST segment and ends when it returns to the baseline.
- **RR interval** :Represents the time between two consecutive heartbeats; begins from the peak of one R wave to the peak of the next R wave.
- **QT interval** :Represents total ventricular electrical activity; begins at the start of the QRS complex and ends at the end of the T wave.



The components of an ECG

ECG Leads:

When two electrodes are positioned at different locations, the electrical potential difference resulting from cardiac activity is measured. This recorded electrical difference is called a **Lead**

ECG leads are divided into two main types. The first type is **Bipolar Leads**, which measure the potential difference between two active electrodes. They are three in number: Lead I, Lead II, and Lead III. The second type is **Unipolar Leads**, which measure the electrical potential at one active electrode relative to a reference point. They are **nine** in number and include **three augmented limb leads (aVR, aVL, and aVF)** and **six chest leads (V1 to V6)**. Therefore, the total number of ECG leads is **12 leads**.

1. Bipolar leads:

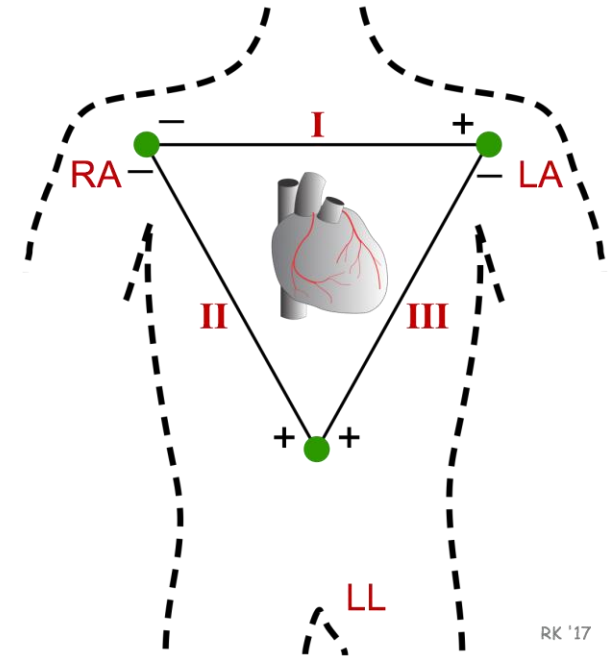
In bipolar leads, ECG is recorded by using two electrodes such that the final trace corresponds to the difference of electrical potentials existing between them. They are called standard leads or **Einthoven leads**.

$$\text{I} = V_{\text{LA}} - V_{\text{RA}}$$

$$\text{II} = V_{\text{LL}} - V_{\text{RA}}$$

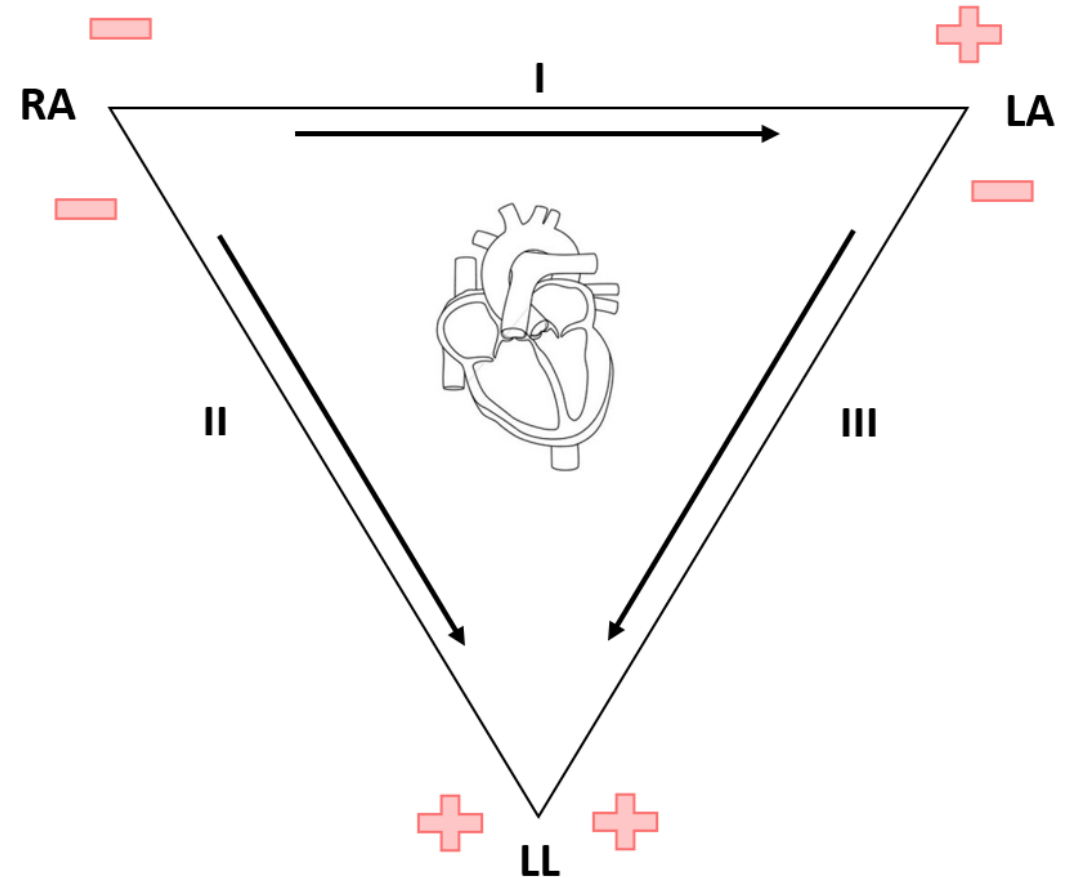
$$\text{III} = V_{\text{LL}} - V_{\text{LA}}$$

RA = right arm, LA = left arm, and LL = left leg with the right leg as the reference point.



Einthoven triangle

- **Einthoven's triangle:** an imaginary triangle with the heart at its center, formed by the axes of the three bipolar limb leads.



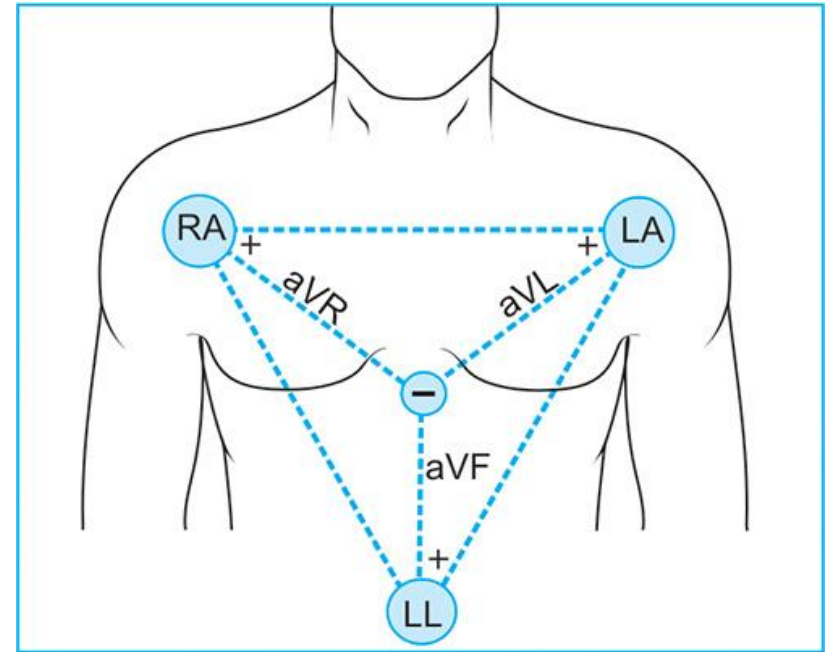
2. Unipolar leads:

In this arrangement, the electrocardiogram is recorded between a single electrode and the center of body, In practice, the reference electrode or central terminal is obtained by a combination of several electrodes tied together at one point .

Two types of unipolar leads are employed which are:

I. limb leads

- **In the lead identified as aVR**, the right arm is recorded with respect to a reference established by joining the left arm and left leg electrodes.
- **In the aVL lead**, the left arm is recorded with respect to the common junction of the right arm and left leg.
- **In the aVF lead**, the left leg is recorded with respect to the two arm electrodes tied together.



II. Chest leads

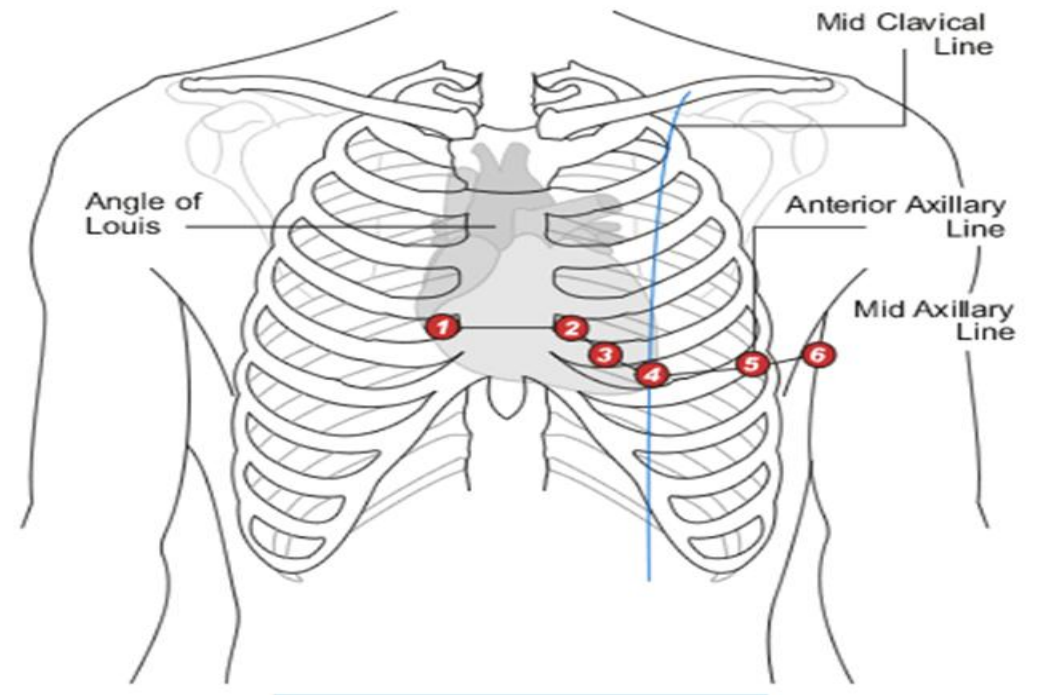
V1 and **V2** are on either side of sternum at 4th intercostal space.

V4 is midclavicular line, 5th intercostal space.

V3 is halfway between **V2** and **V4**.

V6 is at midaxillary line, 5th intercostal space.

V5 is halfway between **V4** and **V6**, 5th intercostal space.



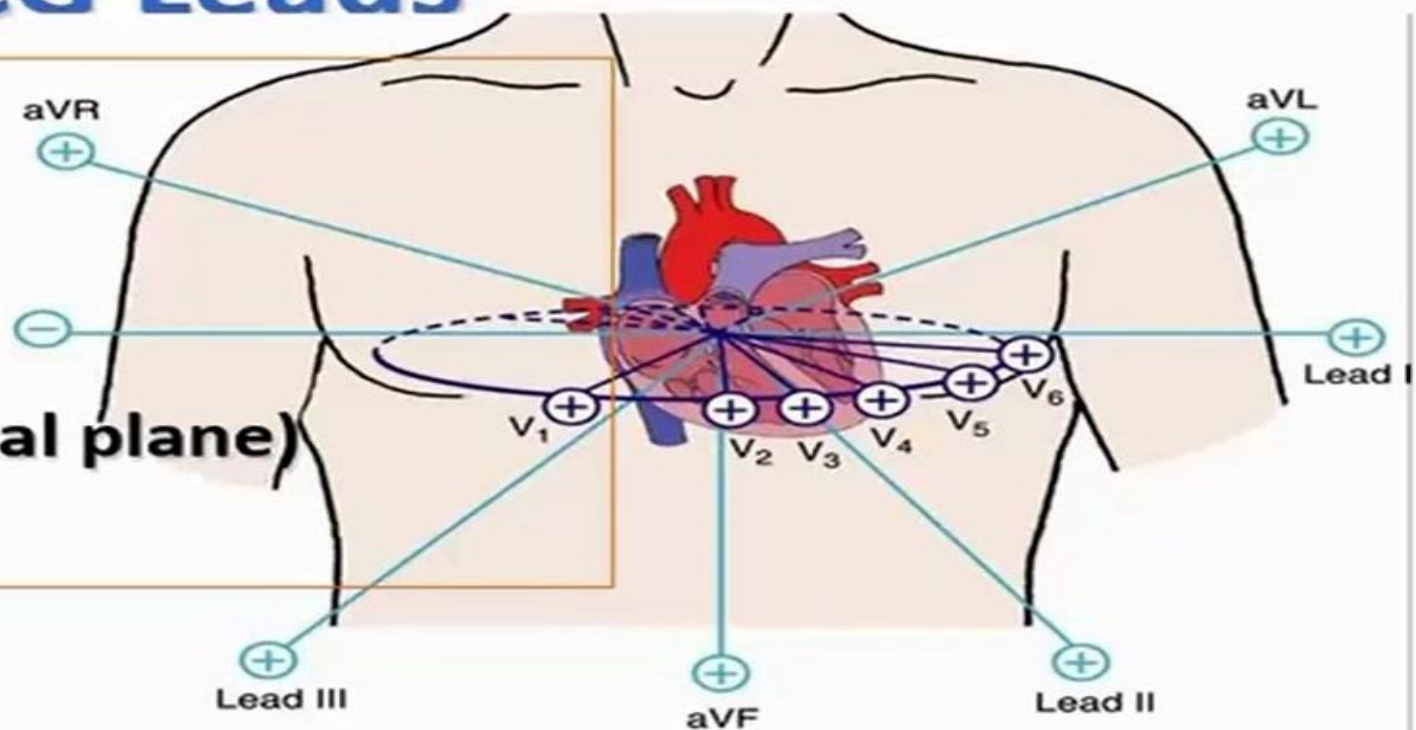
ECG Leads

- **6 limb leads (frontal plane)**

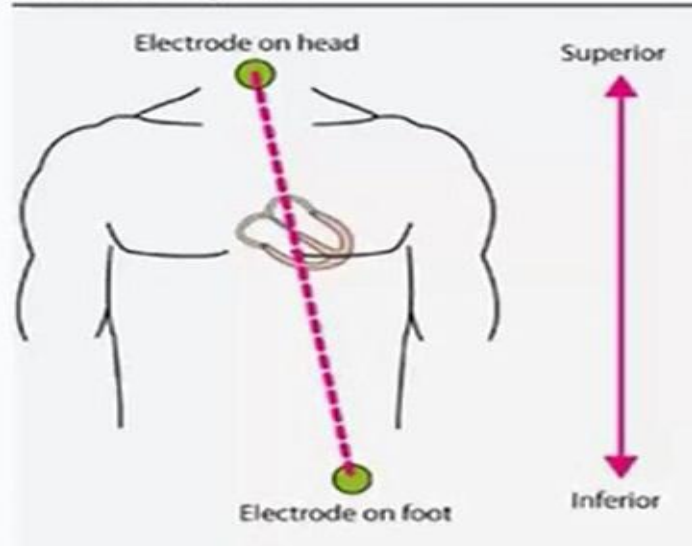
- 3 bipolar leads
- 3 unipolar leads

- **6 precordial leads (horizontal plane)**

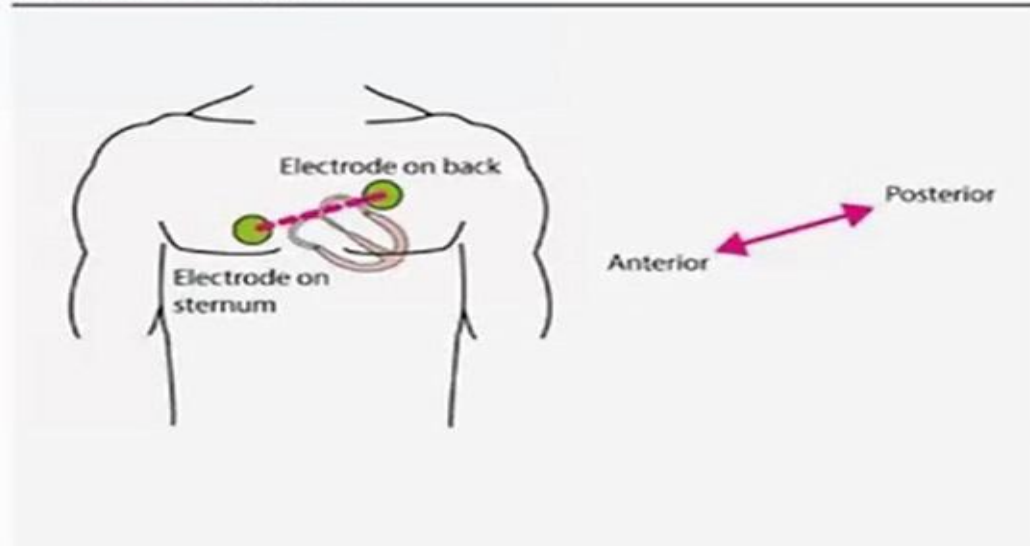
- V1 – V6



(A) Frontal plane



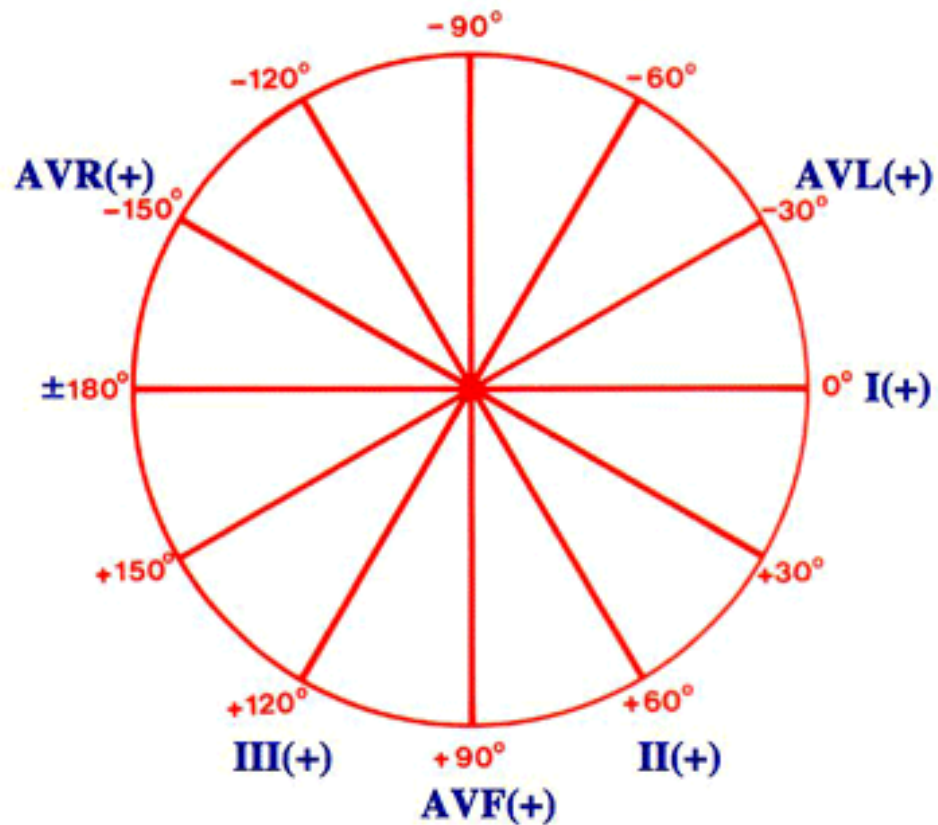
(B) Horizontal plane

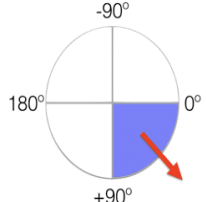
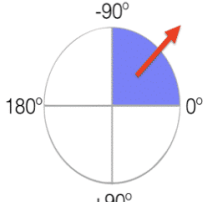
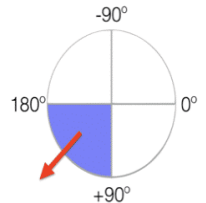
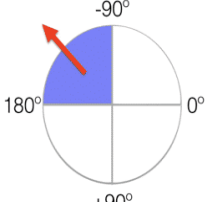


How to Determine the Axis

Quadrant Method

Hexaxial Reference System



Lead 1	Lead aVF	Quadrant	Axis
POSITIVE	POSITIVE		Normal Axis (0 to +90°)
POSITIVE	NEGATIVE		**Possible LAD (0 to -90°)
NEGATIVE	POSITIVE		RAD (+90° to 180°)
NEGATIVE	NEGATIVE		Extreme Axis (-90° to 180°)

Electrical Axis of the Heart

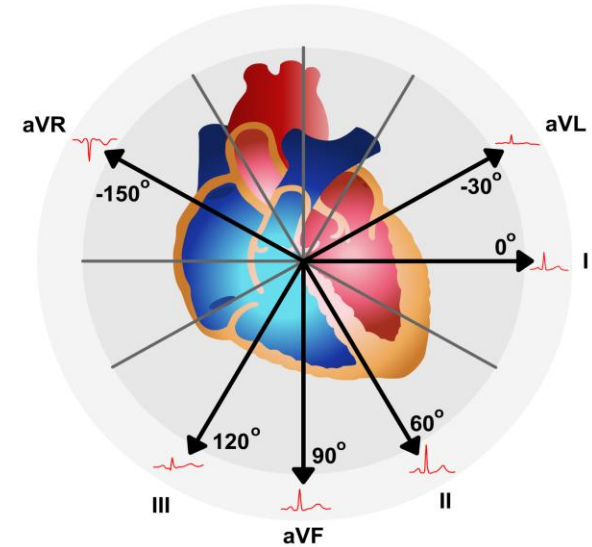
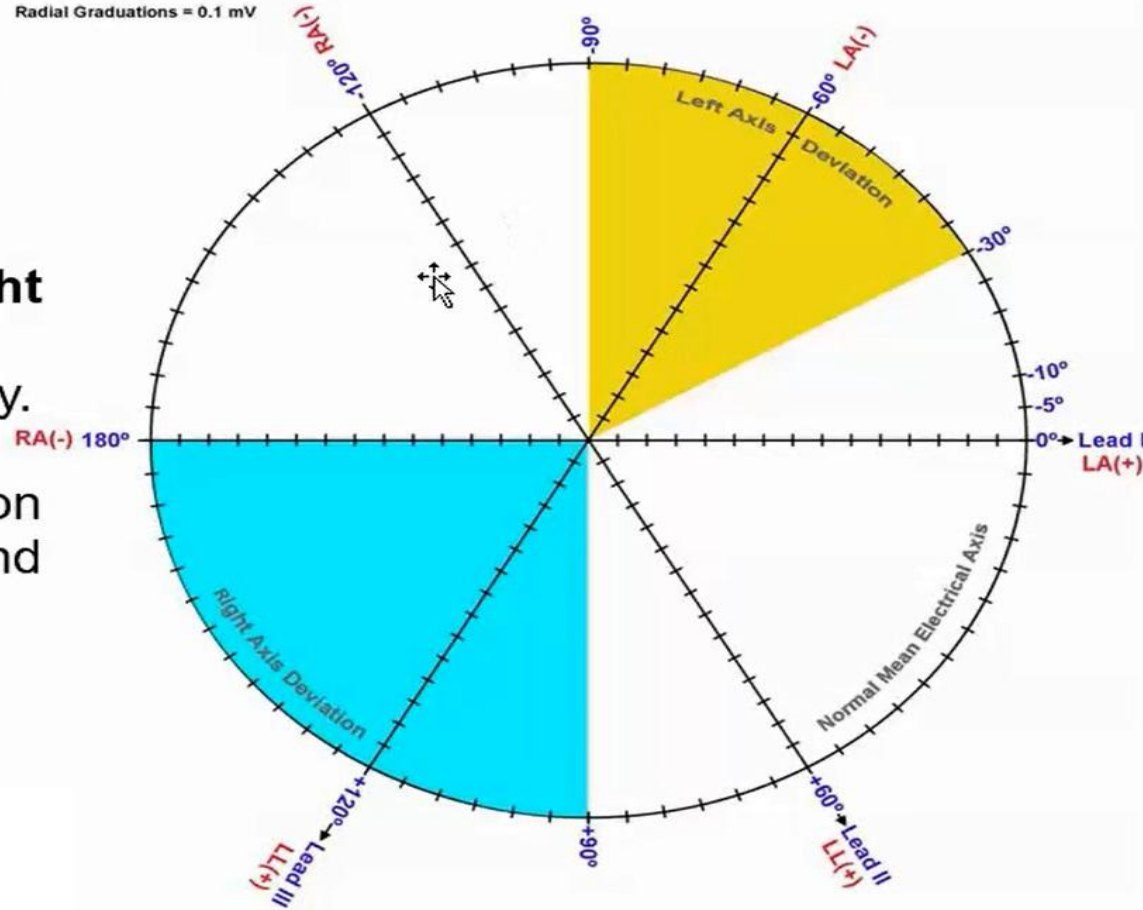
CAUSES OF AXIS DEVIATION

Common Causes of Left Axis Deviation:

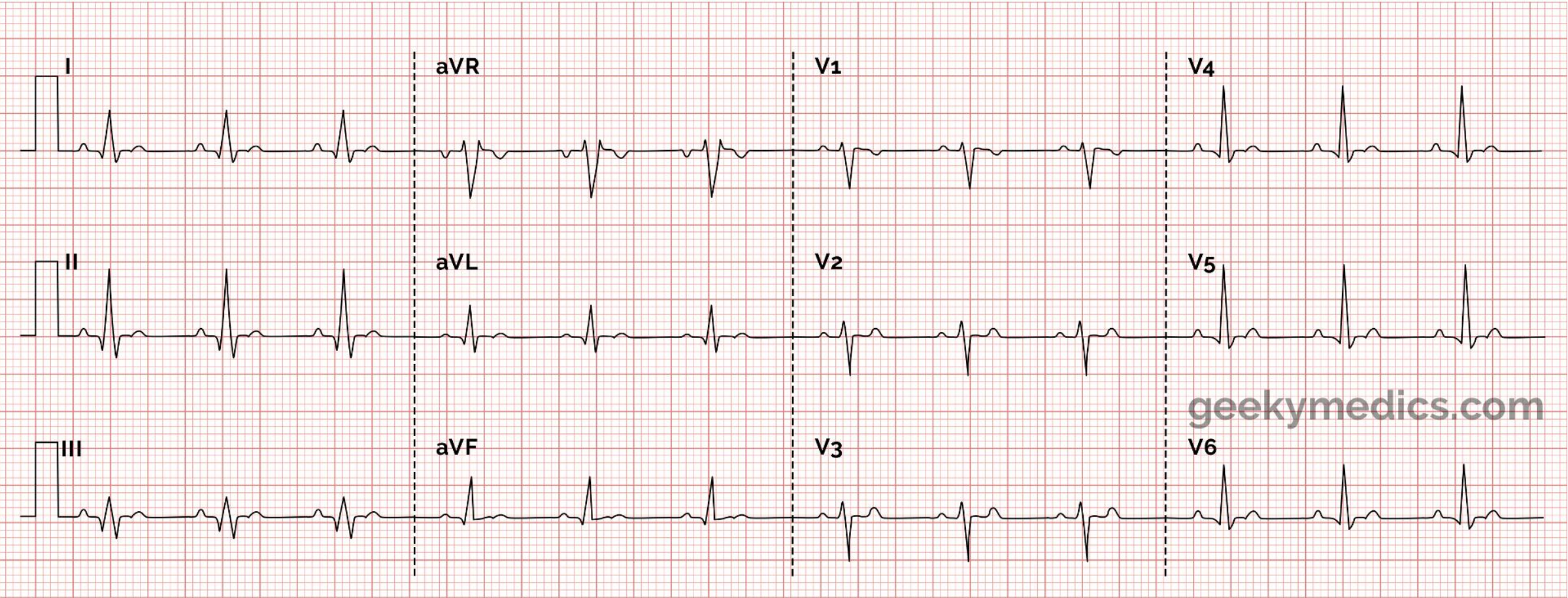
- a. Left ventricular hypertrophy.
- b. Pregnancy.
- c. Obesity.
- d. Infarct in right ventricle.

Common Causes of Right Axis Deviation:

- a. Right ventricular hypertrophy.
- b. Infarct in left ventricle.
- c. Slight right axis deviation may be normal for children and very tall, thin adults.



Normal ECG



geekymedics.com

