



Subject Name: Biomedical Instrumentation Design I_2

4th Class, Second Semester

Subject Code: MU0114202

Academic Year: 2025-2026

Lecturer: Mr. Mahir Rahman

Email: mahir.rahman@uomus.edu.iq

Lecture No.: 3

Lecture Title: ENG and EMG.

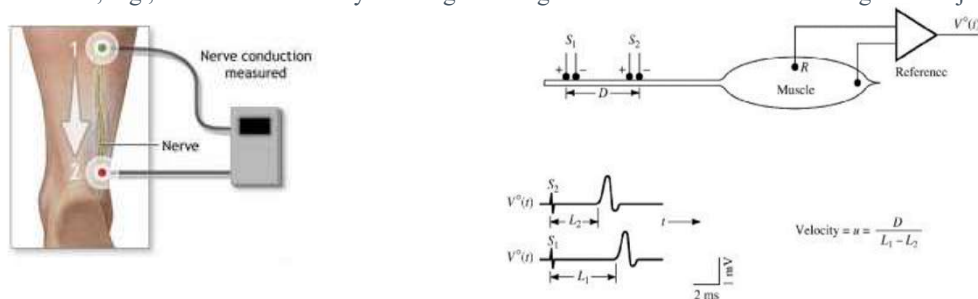


<https://eng.uomus.edu.iq/DefaultDep.aspx?depid=13>



The Electroneurogram

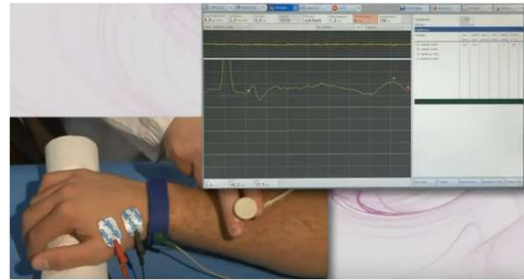
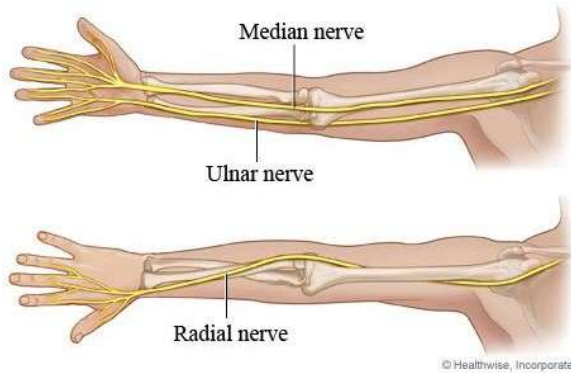
- › Conduction velocity in a peripheral nerve is measured by stimulating a motor nerve at two points a known distance apart along its course. Subtraction of the shorter latency from longer latency gives the conduction time along the segment of nerve between the stimulating electrodes.
- › Knowing the separation distance, we can determine the conduction velocity of the nerve, which has potential clinical value since, e.g., conduction velocity in a regenerating nerve fiber is slowed following nerve injury.





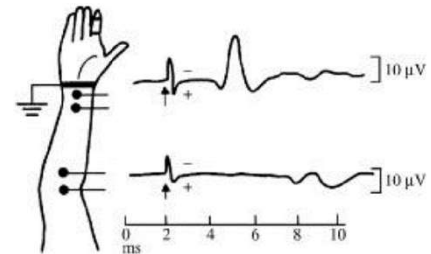
The field potential of sensory nerves

- › Extracellular field responses from sensory nerves can be measured from the median or ulnar nerves of the arm by using ring-stimulating electrodes applied to the fingers, and the conduction speed is computed at two sites of known distance along the course of the nerve.



The field potential of sensory nerves

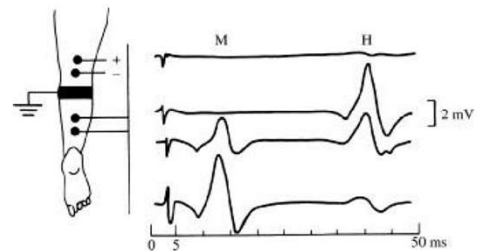
- › Long pulses cause muscle contractions, limb movement, and undesired signals (artifacts). These are avoided by positioning the limb in a comfortable, relaxed posture and applying a brief, intense stimulus (square pulse of approximately 100 V amplitude with a duration of 100 to 300 μ s).
- › The measured ENG signals are 10 μ V, and power-line interference is sometimes a problem even with good amplifier common-mode properties. The input leads should be twisted appropriately together and shielded. In addition, if warranted, the subject could be placed in an adequately shielded room or cage.





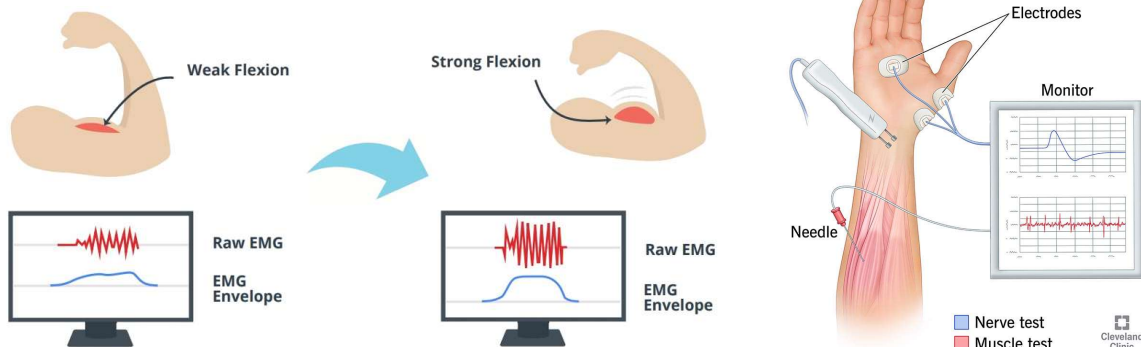
Reflex-evoked field potentials

- › When a peripheral nerve is stimulated, and an evoked field potential is recorded in the muscle it supplies, it is sometimes possible to record a second potential that occurs later than the initial response. **DISCUSS !!!**
- › The four traces show potentials evoked by stimulation of the medial popliteal nerve with pulses of increasing magnitude (the stimulus artifact increases with stimulus magnitude). The later potential or H wave is a low-threshold response, maximally evoked by a stimulus too weak to evoke the muscular response (M wave). As the M wave increases in magnitude, the H wave diminishes. **DISCUSS !!!**



Electromyography (EMG)


- › The EMG is a neurophysiological technique for examining the electrical activity of skeletal muscles.
- › The source of electrical signal in EMG is the muscle membrane potential. The muscle fibres innervated by the axonal branches of a motor neuron form a motor unit (MU).





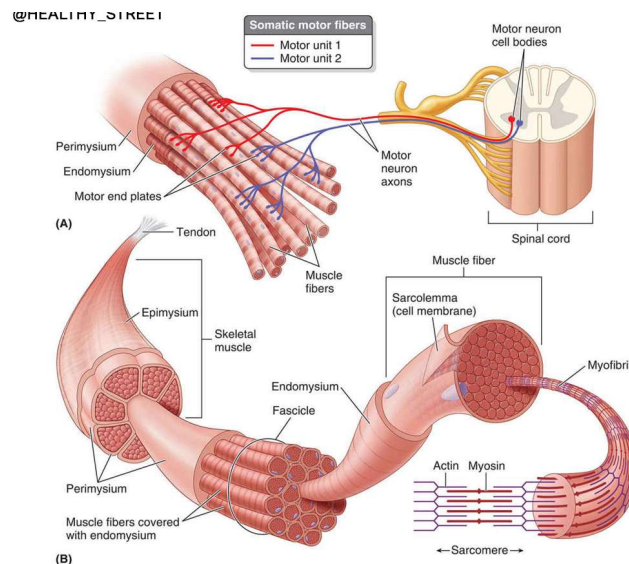
Electromyography (EMG)

- › The summation of action potentials of MUs is called motor unit action potential (MUAP). The anatomical and physiological characteristics of the motor system are reflected in the biosignal obtained from a muscle or its fibers.
- › EMG recording and analysis are powerful neurophysiological techniques that can be employed to:
 - a) identify the health status of the motor system;
 - b) localize and typify peripheral and central abnormalities and lesions;
 - c) determine the temporal course and the severity of motor system abnormalities, and
 - d) determine and evaluate the effectiveness of treatment strategies.



Electromyography (EMG)

- The skeletal muscle is organized functionally on the basis of the motor unit, which consists of a single motor nerve fiber and the bundle of muscle fibers to which it is attached.





Electromyography (EMG)

- The fibers of a given motor unit are interspersed with fibers of other motor units. Thus, the active muscle fibers of the single motor unit (SMU) constitute a distributed bioelectric source located in a volume conductor that consists of all other fibers within the muscle (active and inactive), blood vessels and connective tissue.
- The evoked field potential from the active fibers of an SMU has a triphasic form of brief duration (3 to 15ms) and an amplitude of 20 to 2000 μ V, depending on the size of the motor unit.
- The frequency of discharge usually varies from 6 to 30 per second.

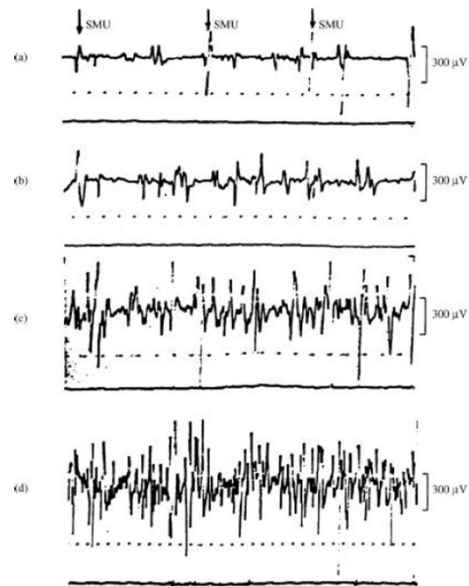


Electromyography (EMG)

Motor unit action potentials from normal dorsal interosseus muscle during progressively more powerful contractions.

(c) In the interference pattern, individual units can no longer be clearly distinguished.

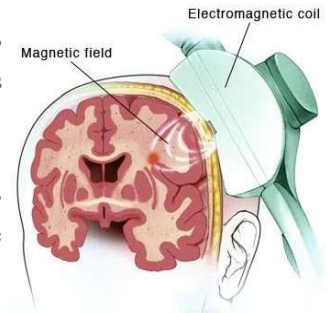
(d) Interference pattern during very strong muscular contraction. Time scale is 10ms per dot.





Electromyography (EMG)

- › Muscle activity can be detected during resting state or during voluntary movement. In addition, induction of compound action potential (CMAP: Evoked by directly stimulating a peripheral nerve with an electrical current) and motor evoked potential (MEP: Evoked by stimulating the motor cortex of the brain, usually with transcranial magnetic stimulation (TMS)) can be obtained by means of peripheral nerve stimulation (PNS) and cortical stimulation, respectively.
- › While PNS provides measurement of integrity of the peripheral motor system, cortical stimulation through techniques such as Transcranial Magnetic Stimulation (TMS), permit examining the integrity of the corticospinal tract.



Feature	CMAP	MEP
Stimulation Method	Peripheral nerve	Motor cortex
Recorded Response	Muscle activity	Corticospinal tract activity
Clinical Applications	Nerve conduction, neuromuscular disorders, nerve injuries	Corticospinal tract integrity, surgical monitoring, motor control
Size	Larger amplitude	Smaller amplitude
Latency	Shorter latency	Longer latency
Interpretation	More straightforward	More variable, subject to confounding factors



Electromyography (EMG)

Feature	Needle EMG	Surface EMG
Invasiveness	Invasive	Non-invasive
Recording location	Inside muscle	Skin surface
Muscle fiber coverage	Individual fibers	Group of fibers
Applications	Neuromuscular disorder diagnosis	Muscle function assessment, rehabilitation, biofeedback, sports analysis
<ul style="list-style-type: none"> ➤ Needle EMG provides more detailed information, but it is more uncomfortable and requires specialized training to perform. ➤ Surface EMG is more convenient and widely used, but it may not be as sensitive for detecting certain neuromuscular disorders. 		



THANK YOU

