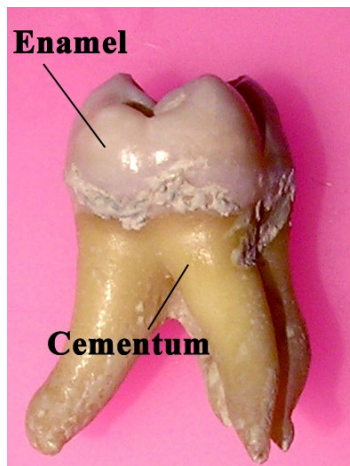


### Enamel:



#### Enamel(E.)

1. is **the hardest calcified tissue in the human body.**
2. It is **an ectodermal in origin** ,
3. protective covering the crown of the teeth.
4. The cells that formed it called **Ameloblasts which are lost as the tooth erupts in the oral cavity**, and **so the E, can not renew it self after destruction.**

#### -Physical characteristics of E.:

1. E, is extremely hard, because of its high mineral content a property that enables it to withstand the mechanical forces applied during mastication.
2. The structure and hardness of the E. render it brittle, which is particularly apparent when the E. loses it's foundation of sound dentin. If this supportive layer of D. is destroyed by caries or improper cavity preparation, **the unsupported E, fractured easily.**
3. E- is translucent, it reflect the color of underlying D. It varies in color from light yellow to gray white

4. It also varies in thickness, from 2.5mm over the cusp tip and incisal region to the **knife edge at cervical region**.

5. E, is permeable, but its permeability depends on the age of the human. Its permeability is higher in children than in the adult, so the **E. can take fluoride ions that fuse with hydroxyapatite crystals** forming **fluorapatite crystals** and give more resistance to the tooth in children.

### **Chemical composition:**

E. consists mainly **96% inorganic** and **4% organic material and water**. The inorganic content is a crystalline calcium phosphate (hydroxyapatite) which is also found in bone, dentine and cementum as in this **formula  $\text{Ca}_{10}(\text{PO}_4)_6(\text{OH})_2$** . The organic materials of the E. are amelogenin and enamel proteins.

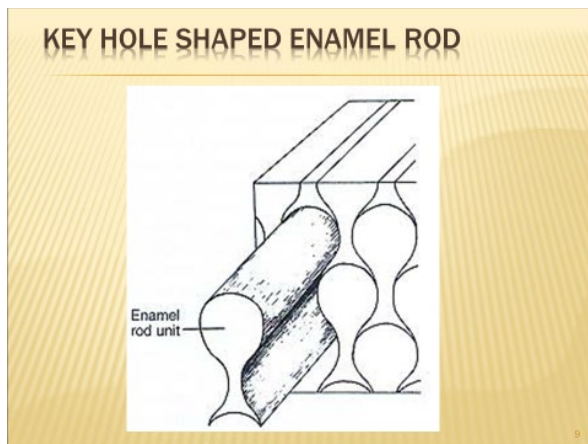
### **Structure of the E**

**The basic unit of E- that is composed of E. rod or prism, rod sheath, and inter-rod substance.**

- E. is built from closely packed hydroxyapatite crystals measuring 60-70nm in width and 25-30nm in thickness which are arranged in E. rods or prisms. It is believed that the length of the crystals spans the entire thickness of the E. layer.
- The E. rod is shaped like a cylinder and is made up of crystals with long axes that run parallel to the longitudinal axis of the rod,
- **Each E. rod is formed by 4 ameloblasts** and each rod runs from DEJ to the E. surface.
- The direction of E- rod is wavy or oblique so the length of the E. rod is greater than the thickness of E.
- The No. of E. rod is about **5 millions in the lower lateral incisor** and **12 millions in the upper first molars**.
- The rod appears as a **key hole** in **longitudinal section**. Each key hole consists of head and tail, head represents rod and tail represents the inter-rod region.

Head of the key hole is at occlusal or incisal regions and the tail is at the cervical direction. While in **cross section the E. rod appear as hexagonal, or oval, or round , or sometimes as fish-scale appearance.**

- The direction of E. rods in cuspal and incisal areas are vertical but as soon as progress to the cervical part of the crown, they became oblique and then horizontal and finally they Inclined apically.
- Rod sheath it represent the organic matrix(4%) of the E. It surround the head of E, rod, but not completely encircle it, only  $\frac{2}{3}$  of it- Rod sheath develops due to irregular arrangement of the crystals and its less calcified than E, rod. So dental caries when first attack the E., they invade the rod sheath,
- The inter rod substance is a region between 2 rods and it represent the tail ,and its crystals are oriented in direction different from those making up the rod.



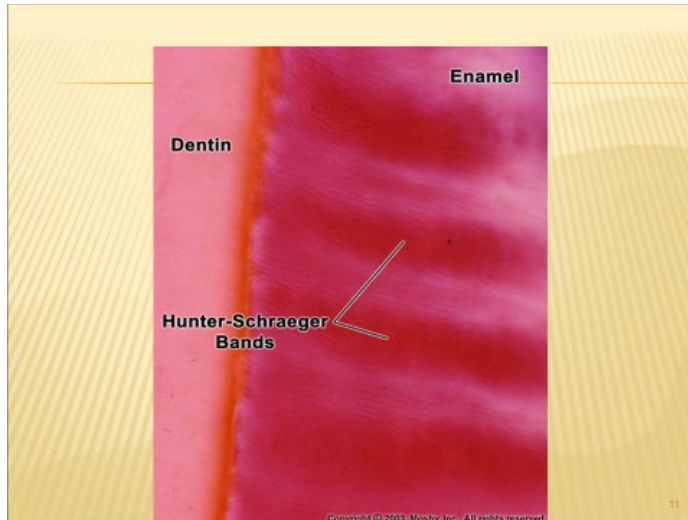
### **Gnarled E:**

It's the **hardest type of E. present in the crown to with stand the force of mastication applied on the cusps and the incisal edge.** The direction of E. Rods is much complicated in the E, of the cusp tips and the incisal edge. At these regions the **E- rods are interwine more irregularly** as an optical appearance.

### **Hunter- Schreger bands:**

They are **an optical phenomenon produced by changes in the direction between adjacent groups of rods.** These bands are seen most clearly in

**longitudinal ground section** viewed by reflecting light and are found in the inner 2\3 of the E, These bands appear as dark and light alternating zones.



## **Hypocalcified structures in E :**

### **1. E. tufts**

They are best seen in the transverse ground section of the tooth. **E. tufts project from DEJ for a short distance into the E**, They appear to be branched and contain greater concentrations of E. protein than the rest of the enamel E, tufts are believed to occur developmentally because of **abrupt changes in the direction of E. rods.**


### **2. E. lamellae**

**extend for varying depths from the surface of E. and consist of linear longitudinally oriented defects filled with organic materials.** So it represent a **site of weakness in the tooth and may act as a way for the entrance of bacteria that initiate dental caries,**

### **3.E. spindle**

**Its a finger- like extensions arise from DEJ into E, about few micron length, they represent extensions of the odontoblastic process of dentinal**

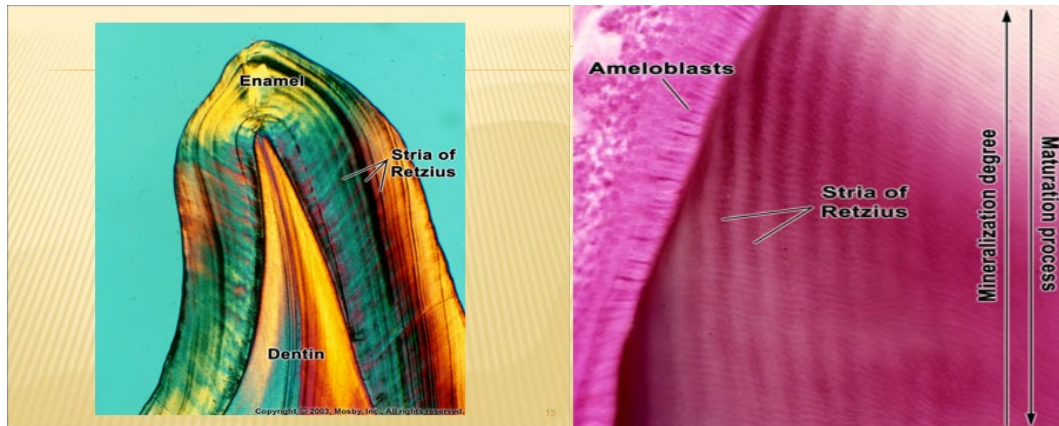
tubules that penetrate the DEJ and because D. formed before E. So these odontoblastic process penetrates the junction and then E- formed around it and so these spindle represent the only mesenchymal structure in E.



## Incremental lines of the E:

### 1- Striae of Retzius:

They are identity in ground section of the teeth. In longitudinal ground section, they are seen as a series of dark or brown lines extending from DEJ toward tooth surface. While in cross ground section they appear as concentric rings. Although Striae of Retzius generally are ascribed to a weekly rhythm in E. production resulting in a structural alteration of rod, the basis for their production is still not clear.



## 2-Cross. striation:

They are fine growth lines seen in ground section of E. In longitudinal section the rods appear segmented by these periodic bands or cross striations. These striations **indicating that the E. matrix is formed by periodic manner of ameloblasts at about 4 micrometer per day.**

## 3-Neonatal line;

Its an enlarged striae of retzius that apparently reflects the great physiologic changes occurring at birth. So these **lines demarcating the boundary between E. formed before and after birth.**

## **Amelogenesis (Enamel formation)**

E. is formed from E.organ which is derived from dental lamina. The cells that forming E. called ameloblasts which differentiated from inner E. epithelium of E. organ.

Amelogenesis begins at cusp tips and the incisal edges and then it separated down the cusp slopes until all the cells of inner E. epith. differentiate into ameloblasts. Amelogenesis begins shortly after dentinogenesis (D. formations) at the advanced or late bell stage. The



delicate basement membrane between inner E- epith. and odontoblasts will disintegrate after dentinogenesis and before amelogenesis.

Amelogenesis is a complex process , it involves 2 stages which are:

1- E. matrix deposition,

2- Maturation or mineralization of the E. matrix.

### **E. matrix deposition:**

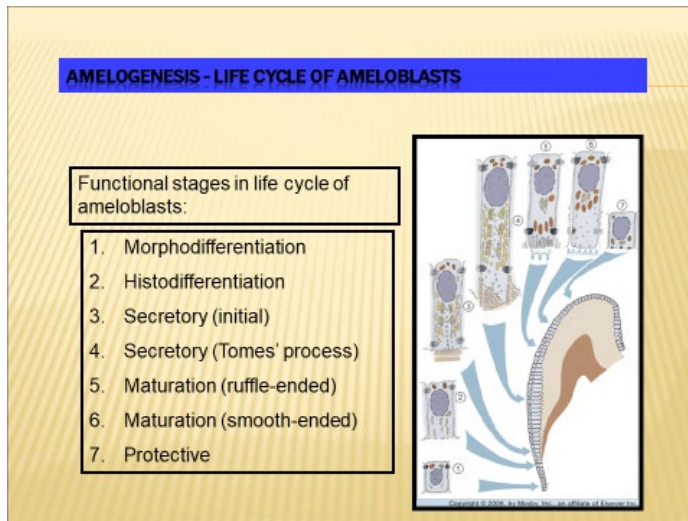
It means the secretion of the E. matrix by ameloblasts. The freshly secreted E, matrix contain 30% minerals as hydroxy apatite crystals and 70% waters and E. proteins (enameline and amelogenine). These E, proteins which are secreted by ameloblasts are responsible for creating and maintaining an extracellular environment favorable to mineral deposition. When the first layer of E- is laid down, the ameloblasts will begins to retreat from DEJ towards E. surface and begins to secrete the next layer of E. Enamel matrix appear as a deep staining layer in the H. and E. staining sections. The ameloblasts usually secrete the E. in rods or prisms. The initially secreted E. matrix is described as Rodless E,

### **Mineralization of the E.:**

When the full thickness of E. matrix has been deposited, mineralization will be started. This process involved additional minerals with the removal of organic material and water to reach 96% mineral content. This minerals makes the initial E. crystals that formed in first stage to grow wider and thicker due to the deposition of large amount of hydroxy apatite crystals.

### **Life cycle of the ameloblast cells:**

According to their function, the life cycle of inner E. epith. cells are divided into 6 stages which are:



### 1- Morphogenic stage:

This stage occurred during the advanced bell stage, when the cells of inner E. epith. interact with the adjacent mesenchymal cells of the dental papillae to determine the shape of the crown. The inner E. epith. Cells are separated from the cells of dental papilla by basement membrane. During this stage the inner E. epith. Cells are cuboidal or low columnar.

### 2- Organizing stage(histodifferentiation):

During this stage the inner E. epith. cells have an organizing influence on the adjacent cells of dental papilla and causes their differentiation into odontoblasts.

The inner E. epith, or preameloblasts become longer and the nuclei move toward the proximal end of the cell. At the end of this stage the odontoblasts form first layer of dentin (mantel D.) at the cusp tips and the incisal edge.

### 3-Formative stage:

When the first layer of D, is formed, the cells of inner E. epith. will be differentiated into ameloblasts which begins first at cusp tips and the incisal edges and then proceed down the slopes of the tooth crown till all inner E. epith. cells will be differentiated into ameloblasts, so the last E. to form is at the cervical end of the crown.

Ameloblasts is 35-50 micrometer wide which contain proximal nuclei with supranuclear region show R.E,R, and prominent Golgi apparatus.



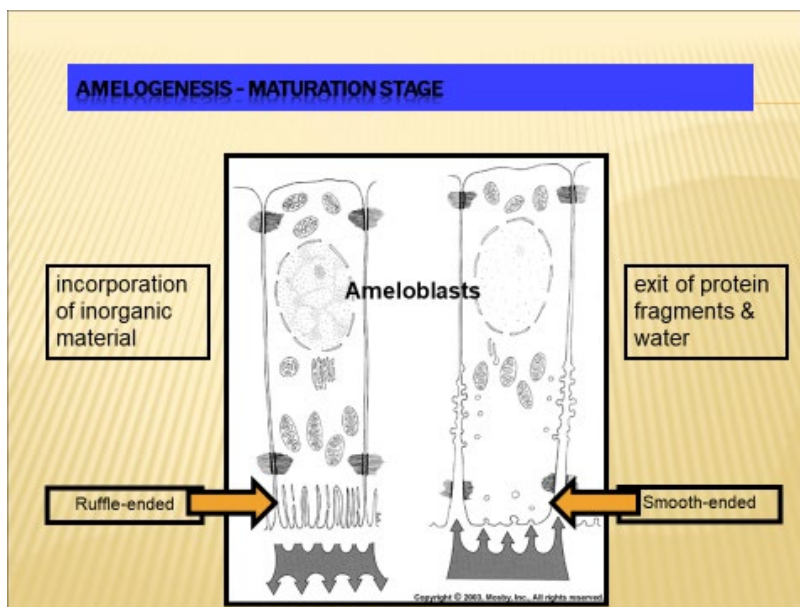
The secretory phase begins with the formation of a thin layer E. matrix opposite to the D.

After the **initial secretion of E, which is called rodless E**, the secretory end of ameloblasts becomes pyramidal in shape forming a process called **Tom's process which is responsible for secretion and the orientation of E, rods and their crystals.**

#### **4- Maturation stage;**

During maturation of E. matrix, the **ameloblasts will become shorter and lose their Tom's process, instead they develop ruffled or brush borders (microvilli)** at their distal portions of the ameloblasts and also contain cytoplasmic vacuoles which containing materials of E, matrix will indicating of an absorptive function of these cells. **Microvilli will increase the resorptive surface area of the cell membrane of the ameloblasts.**

Maturation involves the removal of water and mainly amelogenin E, protein and addition of Ca and Ph ions to increase E, crystals mainly in their thickness,

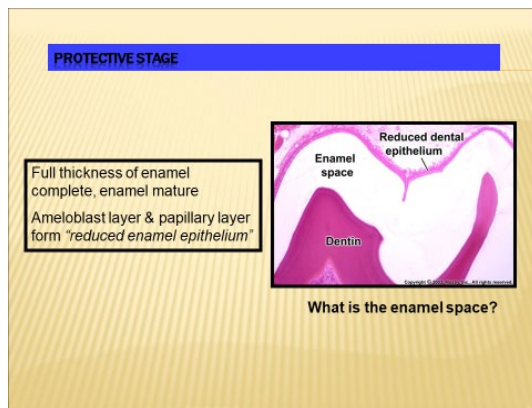


## 5- Protective stage:

When ameloblasts complete maturation of whole E, matrix , they lose their microvilli and then secrete a thin membrane on the surface of the E. which is called primary E. cuticle. Then ameloblast shorten and arranged with other cells of E, organ (stratum intermedium, stellate ericulum, and outer E. epith.) to form reduce E. epith.

### Functions of reduced E. ep.

- 1- To protect the newly formed mature E. by separating it from the surrounding C.T.comes in contact with E. until the tooth erupt.
- 2- It elaborate desmolytic enzyme to destroy C.T, fibers to facilate the eruption of the tooth.



## 6- Desmotytic stage:

Reduce E. epith. proliferates and destroy C.T. around the tooth germ and then fused with oral epith. to form a **complete canal of epith. cells called eruptive canal** from which tooth will erupt without any bleeding and pain.