

**Periodontal Ligament (PDL)**

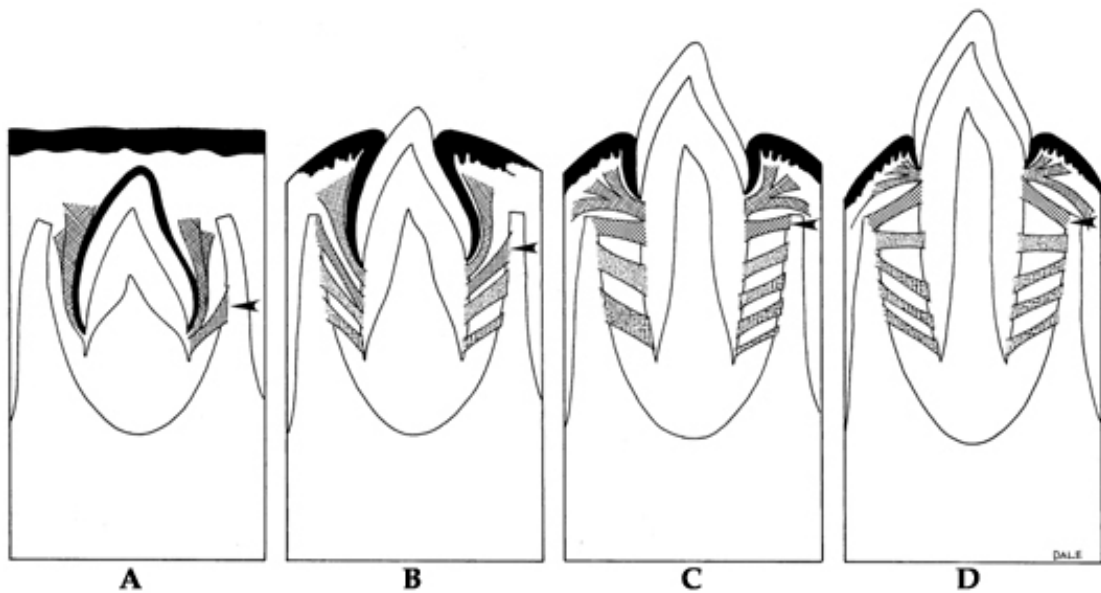
**PDL is the soft specialized connective tissue situated between cementum and alveolar bone proper ,It's origin from dental follicle**

**\*Ranges in thickness between 0.15 and 0.38 mm and is thinnest in the middle portion of the root.**

**\*The width decreases with age**

**\*PDL Tissue with high turnover rate**

**\*Contains fibers, cells and intercellular substance**



Copyright © 2003, Mosby, Inc., All rights reserved.

**FUNCTIONS OF PDL**

**1.Tooth support**

**2.Shock absorber: Withstanding the forces of mastication**

**3.Sensory receptor** necessary for proper positioning of the jaw

**4.Nutritive:** blood vessels provide the essential nutrients to the vitality of the PDL

### **Cellular Composition of PDL**

The cells of periodontal ligament are categorized as:

1. **Synthetic Cells**
  - a) **Osteoblasts**
  - b) **Fibroblasts**
  - c) **Cementoblasts**
2. **Resorptive Cells**
  - a) **Osteoclasts**
  - b) **Cementoclasts**
  - c) **Fibroblasts**
3. **Progenitor Cells**
4. **Epithelial Cell rests of malassez**
5. **Connective Tissue cells**
  - a) **Mast cells**
  - b) **Macrophages**

## **Functions of Cells**

a) Osteoblasts( is the formative cell of bone)

b) Osteoclasts ( is the resorptive cell of bone and involved in bone remodeling and in periodontal disease and tooth movement)

c) Fibroblasts (Most abundant cell in PDL, involved in production of various types of fibers)

- Fibroblasts are capable of both synthesis and resorption of fibers( has dual function).
- They exhibit lysosomes, which contain collagen fragments undergoing digestion.
- The presence of collagen resorbing fibroblasts in a normal functioning periodontal ligament indicates resorption of fibers occurring during remodeling of periodontal ligament.

d) Epithelial cells (remnants of Hertwig's epithelial root sheath-epithelial cell rests of Malassez) found close to cementum.

e) Macrophages (important defense cells)

f) Progenitor cells are the undifferentiated mesenchymal cells, which have the capacity to undergo mitotic division and replace the differentiated cells dying at the end of their life span. These cells are located in perivascular region.

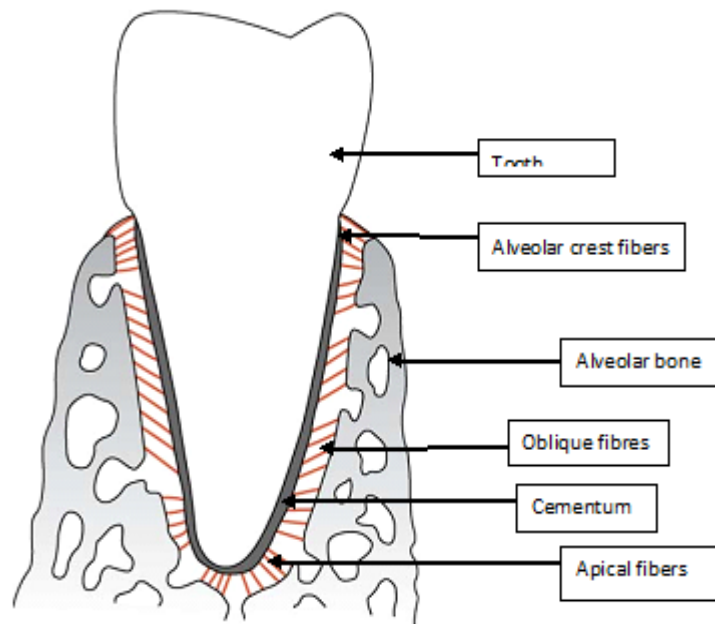
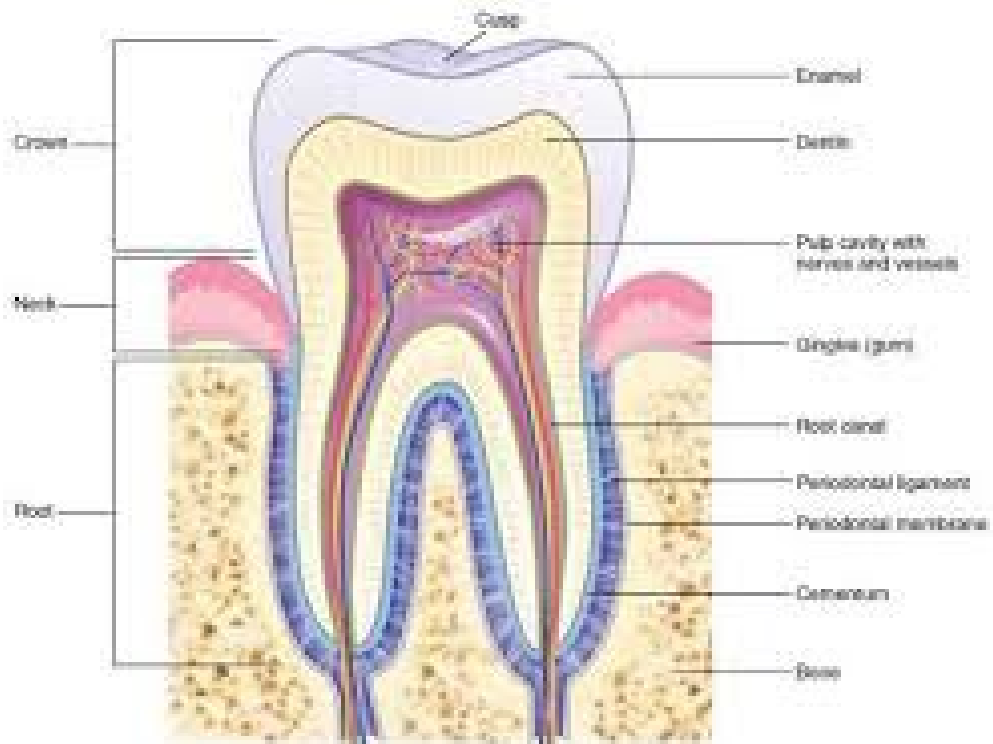h) Cementoblasts(formative cell of cementum)

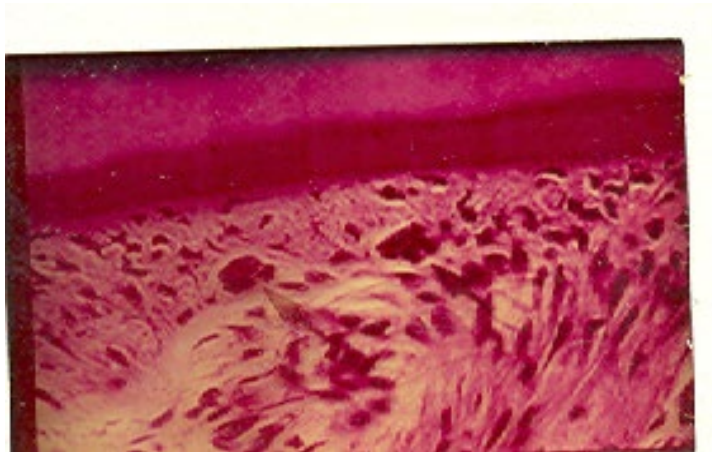
i) Cementoclasts (only in pathologic conditions)

## **PDL fibers**

**Collagen fibers: I, III and XII.** Groups of fibers that are continually remodeled. (Principal fiber bundles of the PDL).

**Oxytalan fibers:** variant of elastic fibers, perpendicular to teeth, adjacent to capillaries.





epithelial cell rests of Malassez

## **Principal Fibers**

**Run between tooth and bone. Can be classified as dentoalveolar and gingival group**

### **1.Dentoalveolar group**

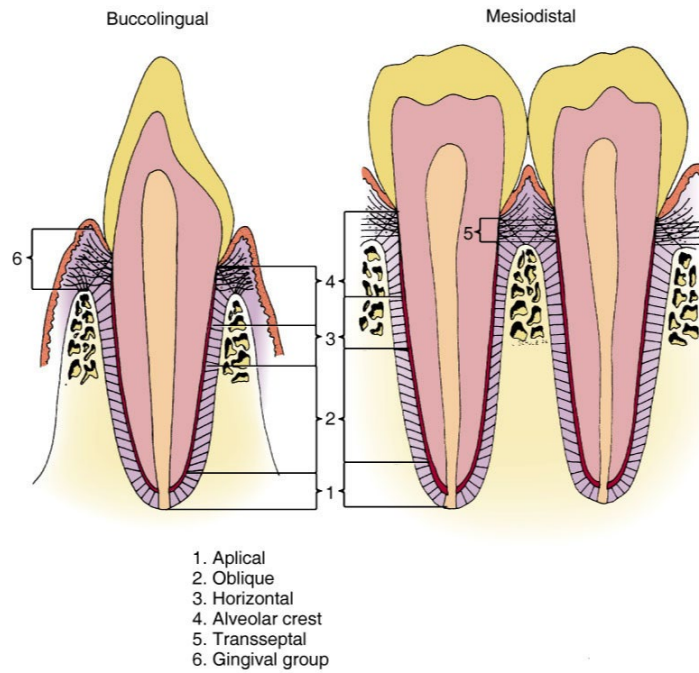
**a. Alveolar crest group (ACG):** below CE junction, downward, outward

**b. Horizontal group:** apical to ACG, right angle to the root surface

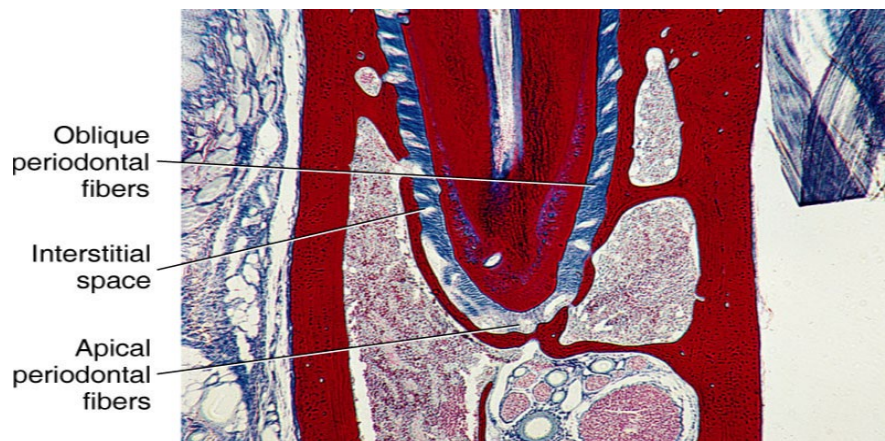
**c. Oblique group:** most numerous, oblique direction and attaches coronally to bone

**d. Apical group:** around the apex, base of socket

**e. Interradicular group:** multirrooted teeth Runs from cementum and bone , forming the crest of the interradicular septum At each end, fibers embedded in bone and cementum: **Sharpey's fiber**



Copyright © 2006 by Mosby, Inc.



Copyright © 2006 by Mosby, Inc.

**2. Gingival ligament fibers:** the principal fibers in the gingival area are referred to as gingival fibers. Not strictly related to periodontium. Present in the lamina propria of the gingiva.

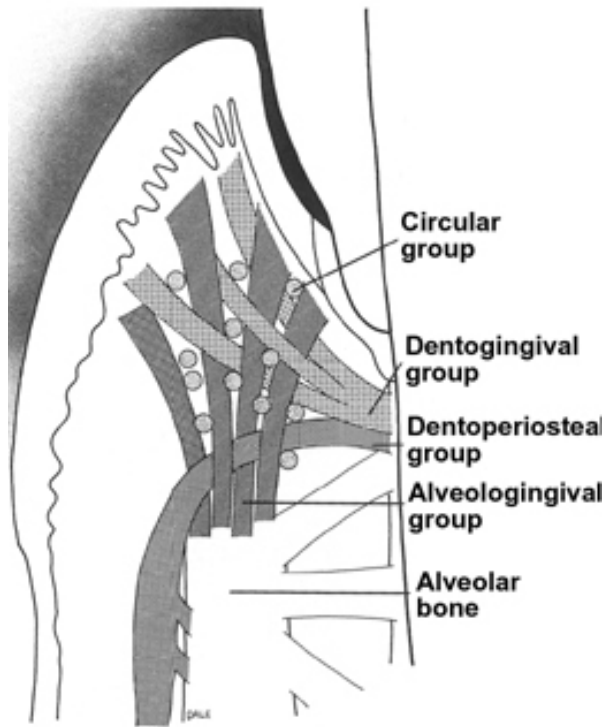
**a. Dentogingival:** most numerous; cervical cementum to f/a gingiva

**b. Alveologingival:** bone of the alveolar crest to f/a gingiva

**c. Circular:** around neck of teeth, free gingiva

**d. Dentoperiosteal:** runs apically from the cementum over the outer cortical plate to alv. process or vestibule (muscle) or floor of mouth

**e. Transseptal:** cementum between adjacent teeth, over the alveolar crest



## Gingival fibers

Fiber group	Location of attachment	Function
<b>Gingival fiber group</b>		
Transseptal	Cervical tooth to tooth mesial or distal to it	Resist tooth separation mesial distal
Attached gingival	Cervical tooth to attached gingival	Resist gingival displacement
Free gingival	Cervical tooth to free gingival	Resist gingival displacement
Circumferential	Continuous around neck of tooth	Resist gingival displacement
<b>Dentoalveolar fiber group</b>		
Apical	Apex of root of fundic alveolar bone proper	Resist vertical forces
Oblique	Apical one third of root to adjacent alveolar bone proper	Resist vertical and intrusive forces
Horizontal	Midroot to adjacent alveolar bone proper	Resist horizontal and tipping forces
Alveolar crest	Cervical root to alveolar crest of alveolar bone proper	Resist vertical and intrusive forces
Interradicular	Between roots to alveolar bone proper	Resist vertical and lateral movement

### **Interstitial Space**

**Present between each bundle of ligament fibers Contains blood vessels and nerves.**

### **Blood supply to PDL**

**Main blood supply is from superior and inferior alveolar arteries.  
The blood vessels are derived from the following:**

- 1. BRANCHES FROM APICAL VESSELS ( Vessels supplying the pulp).**
- 2. BRANCHES FROM INTRA-ALVEOLAR VESSELS:-**
- 3. BRANCHES FROM GINGIVAL VESSELS**