

## LEC 12 **Peri-implant diseases classification, cases definition and treatment**

A new classification for peri-implant diseases was developed by the workshop J. G . Caton et al 2017. The peri-implant condition was classified into peri-implant health , peri-implant mucositis and peri-implantitis.

### **Peri-implant health**

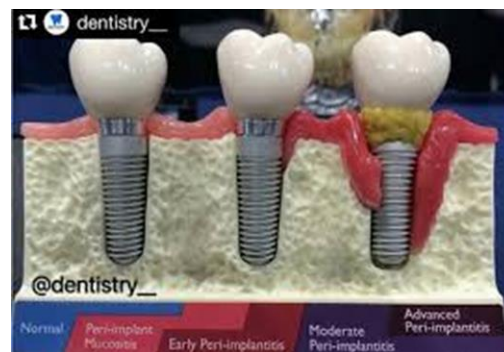
Peri-implant health was defined both clinically and histologically.

**The following characteristics should be considered:**

- 1.The clinical characteristics of a healthy peri-implant site include **absence of erythema, bleeding** on probing, swelling and suppuration.
2. In health, **there are no visual differences** between peri-implant and periodontal tissues. However, **the probing depths are usually greater** and the interproximal papillae are **shorter** at implant versus tooth sites.
- 3.The papilla height **between implants and teeth** is affected **by the level of the periodontal tissues on the teeth adjacent** to the implants. The height of the papilla **between implants** is determined **by the bone crest between the implants**.

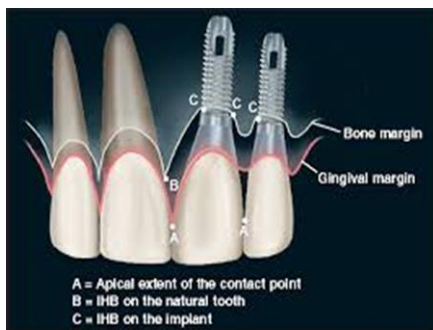

Figure 2. Anatomic IHB (B) is dominant over implant IHB (C) in relation to the bone margin.

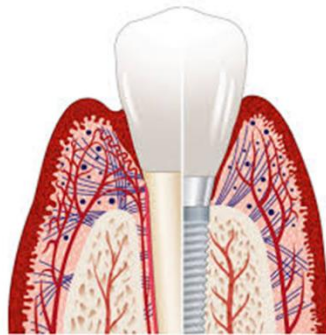


4. The clinical methods to detect the presence of inflammation at an implant site should include visual inspection, probing with a periodontal probe (It is not possible to define a range of probing depths compatible with periimplant health).
- 5 . Peri-implant **tissue health** can exist around implants with **reduced bone support**.

6. The histological characteristics of a healthy peri-implant site are derived mainly from animal studies. The healthy peri-implant mucosa averages **3 to 4 mm** in height and is covered by either a keratinized (masticatory mucosa) or non-keratinized epithelium (lining mucosa).

The portion of the periimplant mucosa that is facing the implant/abutment contains a “coronal” portion that is **lined by a sulcular** epithelium and a thin junctional epithelium, and a more “**apical**” **segment in which the connective tissue** is in direct contact with the implant surface. The connective tissue lateral to the sulcular epithelium harbors a small infiltrate of inflammatory cells. Most of the intrabony part of the implant is in contact with mineralized bone, while the remaining portion faces bone marrow, vascular structures, or fibrous tissue.

7. Compared to the periodontium, the peri-implant tissues **do not have** cementum and periodontal ligament. The **peri-implant epithelium is often longer** and in the connective tissue zone there **are no inserting fibers** into the implant surface. The peri-implant tissues are **less vascularized** in the zone between the bone crest and the junctional epithelium when compared to the connective tissue zone of the periodontium.



### Diagnosis of peri-implant health requires:

- Absence of clinical signs of inflammation.
- Absence of bleeding and/or suppuration on gentle probing.
- No increase in probing depth compared to previous examinations.
- Absence of bone loss beyond crestal bone level changes resulting from initial bone remodeling.

### Management

**Supportive and maintenance are** essential for maintaining healthy peri-implant tissue. The **frequency** of maintenance visits is **based on patient risk indicators** (such as health status and smoking), homecare compliance (such as brushing and flossing), and

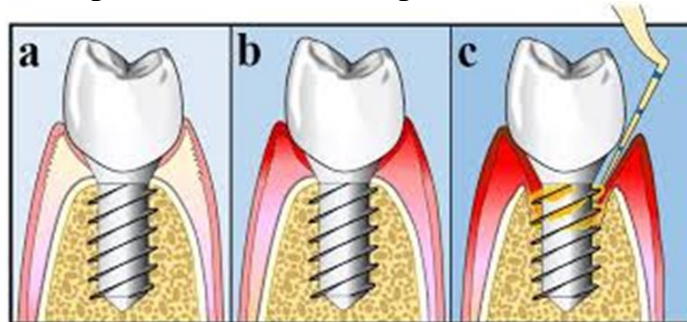
prosthetic design. Generally, a **6-month visit interval or shorter is preferred**. At these visits, peri-implant **probing**, assessment of bleeding on probing and, if warranted, a **radiographic** examination is performed. An **oral hygiene assessment** and instruction of patient-administered plaque control is required. **Mechanical instrumentation** of implant sites to remove biofilm is mandatory.

### **Peri-implant mucositis**

While there is strong evidence that peri-implant mucositis is caused by plaque, there is very limited evidence for non-plaque induced peri-implant mucositis. Periimplant mucositis can be **reversed** with measures aimed at eliminating the plaque.

**The following characteristics should be considered:**

- 1-** The **main** clinical characteristic of peri-implant mucositis is **bleeding** on gentle probing. Erythema, swelling and/or suppuration may also be present.
- 2-** An **increase** in probing depth is often observed in the presence of periimplant mucositis due to swelling or decrease in probing resistance.
- 3-** There is evidence from experimental human studies that peri-implant mucositis **can resolve**. Resolution of the clinical signs of inflammation may take more than 3 weeks following reinstitution of plaque/biofilm control.
- 4-** The **major etiological factor** is plaque accumulation. Host response to the bacterial challenge may vary between patients. Smoking, diabetes mellitus, and radiation therapy may modify the condition (risk indicators).
- 5-** Peri-implant mucositis is characterized by a well-defined inflammatory lesion lateral to the junctional/pocket epithelium with an infiltrate rich in vascular structures, plasma cells, and lymphocytes. The inflammatory infiltrate **does not extend apical** of the junctional/pocket epithelium into the supracrestal connective tissue zone.



## Diagnosis of peri-implant mucositis requires:

- visual signs of inflammation (erythema and swelling)
- Presence of bleeding and/or suppuration on gentle probing with or without increased probing depth compared to previous examinations.
- Absence of bone loss beyond crestal bone level changes resulting from initial bone remodeling.

## Treatment

**1. Non-surgical** mechanical therapy and oral hygiene measures are useful in treating peri-implant mucositis. The non-surgical mechanical therapy tools are metal (e.g. titanium) curettes, and ultrasonic curettes with the **plastic sleeve**, power-driven air-polishing devices.

The additional use of adjunctive therapies (such as antiseptic, antibiotic, antimicrobial, laser-assisted and probiotic therapies) provides **only minimal** clinical improvements in bleeding tendency and pocket reduction.

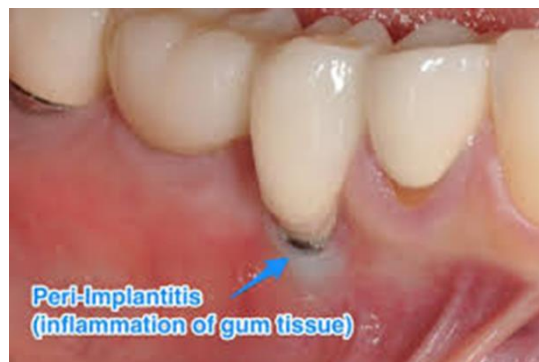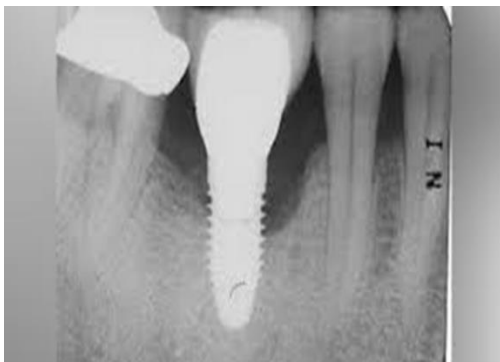**2.** Maintenance care

## Peri-implantitis

Peri-implantitis was defined as a plaque-associated pathologic condition occurring in the tissue around dental implants. Peri-implant mucositis is assumed to precede peri-implantitis.

**The following characteristics should be considered:**

**1-** Peri-implantitis sites exhibit clinical signs of inflammation, bleeding on probing and/or suppuration, increased probing depths and/or **recession** of the mucosal margin in addition to radiographic **bone loss**.



**2-** Peri-implantitis lesions **extend apical** of the junctional/pocket epithelium and contain large numbers and densities of plasma cells, macrophages and neutrophils. In addition, peri-implantitis lesions are **larger** than those at periimplant mucositis sites.

**3-** The onset of peri-implantitis may occur early during follow-up as indicated by radiographic data. Data suggest that the progression of peri-implantitis appears to be **faster than** that observed in periodontitis.

**4-** There is an **increased risk** of developing peri-implantitis in patients who have a history of severe periodontitis, poor plaque control, and no regular maintenance care after implant therapy. Data identifying **smoking and diabetes** as potential risk indicators for peri-implantitis are inconclusive. There is some limited evidence linking peri-implantitis to factors such as post-restorative presence of submucosal cement and positioning of implants that does not facilitate oral hygiene and maintenance. The role of periimplant keratinized mucosa, occlusal overload, titanium particles, bone compression necrosis, overheating, micromotion and biocorrosion as risk indicators for peri-implantitis remains to be determined.

**5-** Observational studies have indicated that crestal bone level changes at implants are typically associated with clinical signs of inflammation. However, there are situations in which peri-implant bone loss may occur due to iatrogenic factors, including malpositioning of the implant or surgical trauma.

### **Diagnosis of peri-implantitis requires:**

- visual signs of inflammation.
- Presence of bleeding and/or suppuration on gentle probing.
- Increased probing depth compared to previous examinations.
- Presence of bone loss beyond crestal bone level changes resulting from initial bone remodeling.

In the absence of previous examination data diagnosis of peri-implantitis can be based on the combination of:

- Presence of bleeding and/or suppuration on gentle probing.
- Probing depths of  $\geq 6$  mm.
- Bone levels  $\geq 3$  mm apical of the most coronal portion of the intraosseous part of the implant.

## Treatment

The treatment includes:

**1. Non-surgical therapy:** it usually provides clinical improvements, but may not be sufficient to treat advanced cases. It allows the clinician time to evaluate the healing response of the tissues and the patient's ability to perform effective oral hygiene measures. Mechanical therapy can be supplemented with locally delivered antibiotics and anti-septics.

**2. Surgical interventions:** surgical approaches usually include either resective or regenerative procedures.

**3. Maintenance care**