

Lec 11 Mucosa- Implant Interface

Introduction

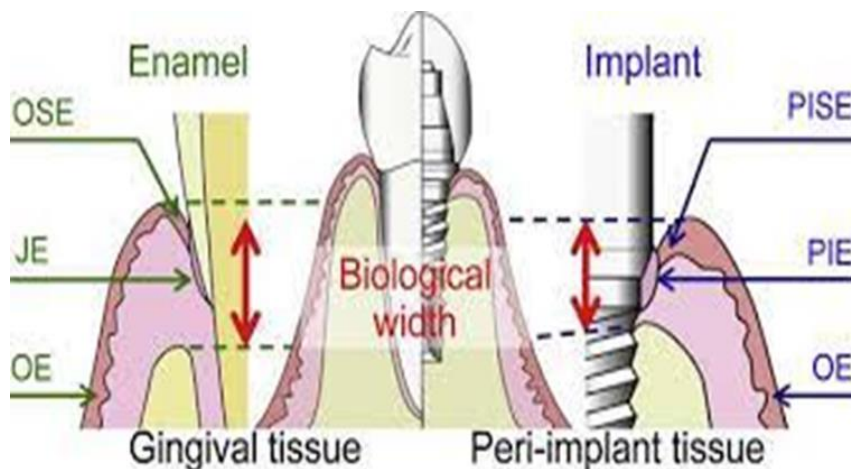
Implant therapy is a treatment option for completely and partially edentulous patients. The success of dental implant is based on the concept of osseointegration ‘which is the direct structural and functional connection between living bone and the surface of a load-bearing implant without intervening soft tissues. Thus, direct contact between the bone and the implant became a critical factor in implant therapy. However, high rate of implant failure was reported with time. It is well known that a major reason for implant loss is dental plaque associated periimplantitis, a condition bearing great similarity to periodontal disease. There is a fact states that oral mucosa provides protection (seal) to the periodontal tissue ‘ including alveolar bone, against invading bacteria. Thus, it is important to understand the relation of implant to its surrounding tissue. The best to understand mucosa implant interface is to compare it to natural tooth.

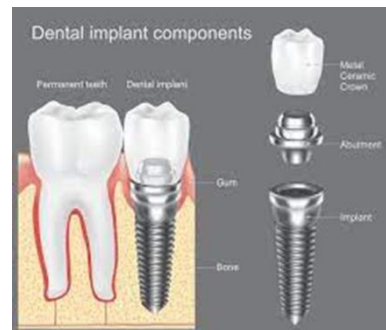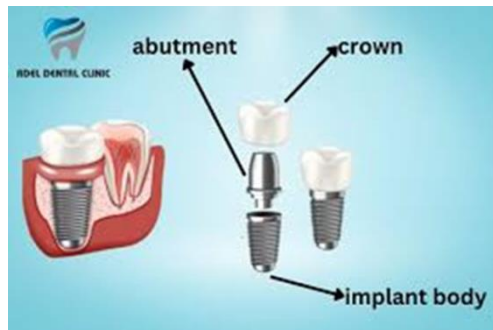Epithelial structure around natural tooth

The gingival epithelium is composed of 3 types of epithelium: junctional epithelium , sulcular epithelium , and oral epithelium. The JE around a natural tooth is non-keratinized and characterized by a wide intercellular space. The oral cavity is constantly exposed to attack from physical, chemical and bacterial insults. OE is a thick mucosal epithelium that protects hard- and soft tissues from exogenous stimulation. However, penetration of the teeth through the OE into the oral cavity compromises this barrier, so the gingiva must form a strong impenetrable bond with the tooth surface in order to seal and maintain the protection of the submucosal tissue from microbial invasion. This seal around the tooth extends from the bottom of the SE to the top of the alveolar bone and comprises both epithelial (JE) and connective tissue components. This attachment structure is usually 2 mm in width and is termed the “biologic width ;” the updated term is “supra-crestal attachment tissue”. Approximately 0.5–1 mm of this width is JE, a stratified squamous epithelium that attaches to the cervical enamel layer in younger generations, and moves progressively to the cementum layer around the tooth root as patients age. Chronic inflammation of the periodontal tissue destroys these adhesion structures, allowing disease to spread easily to the periodontal tissue.

Epithelial structure around dental implant

The mucosa surrounding implants also forms a seal that is comparable to the JE. This peri-implant junction is composed of 3 types of epithelium: peri-implant epithelium (PIE), peri-implant sulcular epithelium (PISE), and oral epithelium (OE). In addition, there is a biologic width of 3–4 mm around implant, slightly longer than that around natural tooth (2mm PIE and 1 to 2mm connective tissue (The PIE performs a similar epithelial attachment function to the JE, and forms from the OE within 2–3 weeks after implantation. Morphologically, PIE is composed of a thin layer of 3–4 cells, and has immunoglobulins, neutrophils, lymphocytes and plasma cells, in a wide intercellular space, which together protect the underlying tissue from invading bacteria. However, despite oral mucosa contacting both the implant abutment and implant body immediately after placement, the PIE often ultimately contacts only the implant body because of on-going bone resorption around the implant as the implant-abutment interface becomes a cause of inflammation. Furthermore, the PIE has a much lower functional sealing capacity than JE, despite having very similar epithelial structures. The lower adhesion of the OE to titanium seems to be caused by the electrostatic characteristics of the implant and ion elution, but the precise reason remains unclear. Therefore, care should be taken while probing implant sites by using periodontal probe. The probing force should be no more than 0.25 mg for implant sites as applied on natural tooth sites.





Structure of the interface between the tooth and gingiva

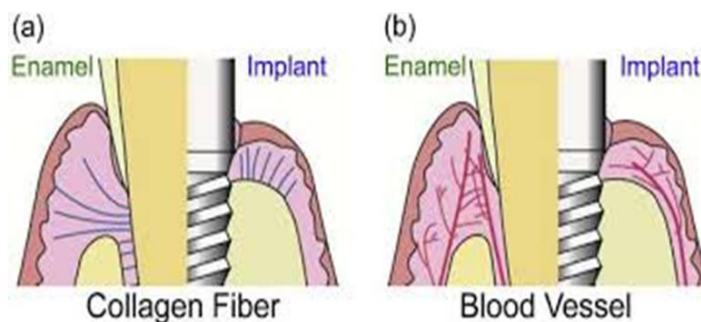
The JE, which seals the periodontal tissue from the oral cavity, is surrounded by a basement membrane (BM) comprising two layers (internal and external basement laminae (IBL and EBL, respectively). BM is divided into electron-lucent and electrondense laminae (the lamina lucida (LL) and lamina densa (LD), respectively), through which the epithelial cells of the JE attaches to tooth surface and sub-mucosal tissue .On the enamel side, the LL connects to the JE cells, an interaction that is reinforced by hemidesmosomes (epithelial adhesion plaques that tack the plasma membrane of the epithelial cells to the adjacent LL). The LD is connected to the enamel. The BM is composed of structural proteins such as type IV collagen, fibronectin and laminin.

Structure of the interface between implant and oral epithelium

Previous reports reported that PIE cells connect to titanium in a similar manner to that JE cells connect to natural teeth, via the IBL and hemidesmosomes. It is suggested that the hemidesmosomal attachment seen between epithelial cells and natural teeth is produced by epithelial cells close to the implant surface. Previous papers have also reported that hemidesmosomes and the IBL (LL and LD) were formed only in the lower region (apical) of the PIE–titanium interface, in contrast to natural teeth where the hemidesmosomes and IBL are evident throughout the JE-tooth interface , suggesting the inferior PIE adhesion to titanium. Therefore, it is reported that the resistance to probing offered by PIE was weaker than that of gingivae around natural teeth, demonstrating that the PIEimplant connection is much weaker than the JE-enamel connection.

Structure of the interface between the implant and connective tissue

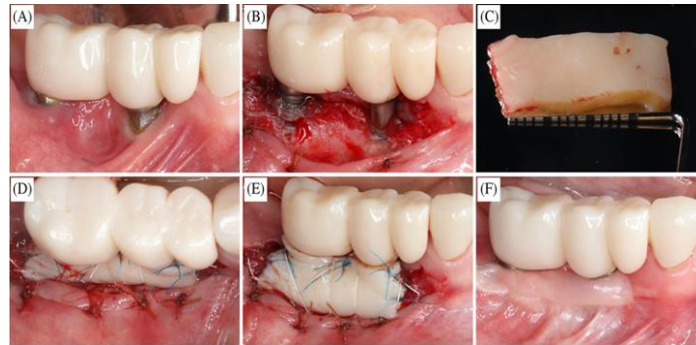
In case of natural teeth, the connective tissue attachment is apical to the JE and resists the physical invasion of bacteria by providing strong adhesion between the special fibers as periodontal ligament and cementum. The fiber orientation and attachment patterns of the epithelium to the implant and tooth are fundamentally different because of the absence of cementum and periodontal ligament around the implant. In short, while the fiber orientation in the connective tissue around natural teeth is perpendicular to the root surface, it runs parallel to the surface around dental implants. This weak, poorly-sealing connective tissue around the implant may accelerate horizontal recession. The role of connective tissue around both implant and tooth is not only for the protection from the extra stimulation as oral bacteria, but also for the supply of nutrients from the blood vessel. However, the PIE is also disadvantaged in comparison with the JE by its limited supply of nutrients. While the periodontal tissue has ample blood flow from the periodontal ligament, periosteum, and connective tissue, the blood supply to peri-implant soft tissue is mainly from the connective tissue. In addition, the soft tissue around the implant is dependent upon the alveolar bone for its blood supply in the absence of other supporting periodontal tissues. In summary, the high quality management of the peri-implant soft tissues such that they act as a healthy periodontal tissue is as indispensable as the maintenance of those around a natural tooth.



Keratinized tissue (attached gingiva) around implant

Previous studies suggest that the presence or absence of keratinized gingiva is not a prerequisite for long-term stability of implants and success when the patient perform optimum oral hygiene procedures. However, it has been suggested that implants surrounded by mucosa only (i.e., nonkeratinized) are more susceptible to peri-implant problems. Keratinized mucosa tends to be more firmly anchored by collagen fibers to the underlying periosteum than nonkeratinized mucosa, which has more elastic fibers and tends to be movable relative to the underlying bone. However, when there is a lack of keratinized

tissue, patients tend to complain about pain and discomfort while performing oral hygiene procedures or other functions in the area. The symptoms are alleviated by increasing the amount of keratinized (firmly bound) tissue around the implant(s) via soft tissue grafting .



Clinical Comparison of Teeth and Implants

Although the similarities between soft tissue-to-implant and soft tissue –to-tooth interfaces, some differences should be considered. At the bone level, the absence of the periodontal ligament surrounding an implant has important clinical consequences. This means that no resilient connection exists between implants and supporting bone. Implants cannot intrude or migrate to compensate for the presence of a premature occlusal contact (as teeth can). Implants and the rigidly attached implant restorations do not move. Thus, any occlusal disharmony will have consequences at either the restoration-to-implant connection, the bone-to-implant interface, or both. Proprioception in the natural dentition comes from the periodontal ligament. The absence of a periodontal ligament around implants reduces tactile sensitivity and reflex function. This can become even more challenging when osseointegrated, implant-supported, fixed prostheses are present in both jaws. The lack of a periodontal ligament and the inability of implants to move contraindicates their use in growing individuals. Natural teeth continue to erupt and migrate during growth, whereas implants do not. Implants placed in individuals prior to the completion of growth can lead to occlusal disharmonies with implants. Likewise, it may be problematic to place one or more implants in a location adjacent to teeth that are very mobile from the loss of periodontal support because, as the teeth move in response to or away from the occlusal forces, the implant(s) will bear the entire load. Overload, because of improper superstructure design, parafunctional habits, or excessive occlusal load ‘may cause microstrains and micro fractures in the bone, which will lead to bone loss and a fibrous inflammatory tissue at the implant interface.